

Miscellaneum : Intra-arterial acetylcholine injections in the treatment of refractory tropical ulcers

Autor(en): **Meyer, Hans E.A.**

Objektyp: **Article**

Zeitschrift: **Acta Tropica**

Band (Jahr): **13 (1956)**

Heft 2

PDF erstellt am: **23.05.2024**

Persistenter Link: <https://doi.org/10.5169/seals-310606>

Nutzungsbedingungen

Die ETH-Bibliothek ist Anbieterin der digitalisierten Zeitschriften. Sie besitzt keine Urheberrechte an den Inhalten der Zeitschriften. Die Rechte liegen in der Regel bei den Herausgebern.

Die auf der Plattform e-periodica veröffentlichten Dokumente stehen für nicht-kommerzielle Zwecke in Lehre und Forschung sowie für die private Nutzung frei zur Verfügung. Einzelne Dateien oder Ausdrucke aus diesem Angebot können zusammen mit diesen Nutzungsbedingungen und den korrekten Herkunftsbezeichnungen weitergegeben werden.

Das Veröffentlichen von Bildern in Print- und Online-Publikationen ist nur mit vorheriger Genehmigung der Rechteinhaber erlaubt. Die systematische Speicherung von Teilen des elektronischen Angebots auf anderen Servern bedarf ebenfalls des schriftlichen Einverständnisses der Rechteinhaber.

Haftungsausschluss

Alle Angaben erfolgen ohne Gewähr für Vollständigkeit oder Richtigkeit. Es wird keine Haftung übernommen für Schäden durch die Verwendung von Informationen aus diesem Online-Angebot oder durch das Fehlen von Informationen. Dies gilt auch für Inhalte Dritter, die über dieses Angebot zugänglich sind.

lich mit dem Bau des Sennar-Dammes in Verbindung zu bringen. In Wadi Halfa wurde sie drei Jahre nach der zweiten Errichtung des Aswan-Reservoirs und im ersten Jahr nach der In-Funktion-Setzung des Jebel Auliya-Dammes beobachtet. Es werden verschiedene Möglichkeiten diskutiert, in welcher Weise diese Dämme die Chironomiden-Fauna beeinflußt haben mögen.

Die Chironomiden-Invasion in Khartum ist offenbar auf das Zusammenspiel verschiedener Umstände zurückzuführen. Wenn ein ausgedehnter Flußlauf durch ein Land mit Monsun-artigem Klima fließt und zudem der Stauwirkung eines Wehrs ausgesetzt ist, so bietet er, hydrobiologisch gesehen, im «Winter» seenähnliche Bedingungen. In Khartum wird der Blaue Nil durch den Weißen Nil zum Teil aufgestaut. Die ausgesprochene Trockenzeit und wahrscheinlich auch die Einwirkung des Sennar-Dammes schaffen optimale Brut- und Entwicklungsbedingungen für Chironomiden, und zwar bevor ihre eventuellen Prädatoren aufkommen könnten. Die Fähigkeit von *Tanytarsus*, schon bald nach dem Schlüpfen Eier zu legen, begünstigt diese Gattung, welche denn auch das Gros der Mückenschwärme liefert. Die tropische Temperatur fördert zudem das Larvenwachstum. Während der Chironomidenzeit ist die Hauptwindrichtung nach der Stadt zugewendet, und viele Häuser sind in der Nähe des Wassers gelegen und von Schattenbäumen und Gebüsch umstanden, welche den Mücken Unterschlupf bieten. Infolge des frühen Sonnenuntergangs und des warmen Klimas halten sich die Leute in diesen Breitengraden nach der Dämmerung gerne im Freien oder in offenen Räumen auf und sind deshalb den Insekten ausgesetzt. Wegen ihrer außerordentlichen Kleinheit können die Mücken überall eindringen.

Zum Abschluß werden kurz einige erfolgversprechende Präventivmaßnahmen diskutiert.

Miscellaneum.

Intra-arterial Acetylcholine Injections in the Treatment of Refractory Tropical Ulcers.

By HANS E. A. MEYER (Zürich)

formerly Senior Medical Officer of Kaffa Province (Ethiopia).

The author had under treatment over one hundred tropical ulcers including an appreciable proportion of neglected large phagedenic ulcers penetrating to the bone which showed only a very slight healing tendency. These patients came for treatment at a very late stage with widespread deep ulcers: some of them had already been treated elsewhere for years with native or other medicines and were in a state of very poor nutrition. The patients usually came for hospital treatment for other diseases (malaria, relapsing fever, typhus fever, dysentery, syphilis, etc.). A special building was available for the hospitalization of about 100 cases of tropical ulcer.

At that time the general treatment for chronic tropical ulcers was:

1. Exposure of ulcer base, opening up and removal of pus deposits and undermined skin bridges.
2. Daily application of bandages soaked in Dakin's or 1% potassium permanganate solution until the ulcer base was cleansed.
3. Bandages with ointment (iodoform-bismuth-vaseline, sulfathiazole and cod-liver oil ointment).
4. Plaster of Paris over iodoform powder under gauze strips for 3 to 5 weeks.

Additional measures consisted of boracic acid poultices, boracic acid bandages, neoarsphenamine, locally as powder and as injections, bismuth, sugar, balsam of Peru, cod-liver oil, corrosive sublimate, acriflavin, etc. The patients were confined to bed during the first two weeks. They were given liberal diet, vitamin preparations and glucose.

This treatment was ultimately effective even in severe cases, only a few cases remaining refractory. Owing to shortage of hospital beds, a more rapidly effective treatment was required and investigations were made to find methods of accelerating healing. Whenever possible, chronic ulcers (i.e., chronically relapsing, fibrous, poorly healing ulcers of longer than 6 months' duration) were given the same treatment as fresh ulcers. This consisted of excision of the ulcer base through healthy tissue with subsequent skin grafting. This method could, however, not always be used for ulcers with exposed bones or tendons or for those situated on the heel, toes, etc. The measures investigated for the promotion of healing by improving the blood circulation in the affected limbs included: hot-and-cold baths, hot poultices, Priscol, Acetylcholin 'Roche', Padutin, Prostigmin (Roche), periarterial sympathectomy. As reported by KNOLL (1), successful trials with acetylcholine injections i.m. had already been carried out to accelerate the healing of tropical ulcer. In peripheral circulatory disorders (cold feet, acrocyanosis, poor granulation, etc.), we found i.m. injections of Acetylcholine 'Roche' every two days up to a total of 20 injections to have a good effect. To strengthen the action of acetylcholine we frequently combined it with vitamin B₁ or Prostigmin 0.5 mg.

Out of 100 tropical ulcers roughly equal in size (area between 10 × 10 and 10 × 12 cm.), depth, location (lower third of the lower leg) and clinical features (bacteriological control):

25 cases treated with 10 injections Acetylcholine 'Roche' i.m. healed in an average of 31 days,

25 cases treated with 10 i.m. injections Acetylcholine 'Roche' + Prostigmin 0.5 mg. healed in an average of 28 days,

25 cases treated with Priscol i.m. healed in an average of 27 days,

25 cases treated without injections healed in an average of 34 days.

Therapy	Acetylcholine i. m.	Acetylcholine + Prostigmin i. m.	Priscol i. m.	no therapy
No. of patients	25	25	25	25
Recovery in days	31	28	27	34

These figures show that the relief of peripheral circulatory disorders causes more rapid healing of tropical ulcer. There were wide variations in the duration of healing within the 4 groups and it is perhaps worth mentioning that the most rapid healing occurred in a case treated without injections.

On reading the publications of KAPPERT (2), SINGER (3), ELLIS and WEISS (4) on intra-arterial injection of acetylcholine, we decided to try this treatment in

our chronic tropical ulcer patients. Since this application is not mentioned in the literature we propose to report our own very successful results, above all with the intention of stimulating further trials with this medicament. We describe 8 cases and emphasize once more that intra-arterial injections of Acetylcholine 'Roche' were given only for chronic widespread ulcers with poor healing tendency. We adopted the technique of SINGER (3). In one case we had to expose the arteria femoralis operatively on account of old scars. It was possible to re-examine 3 cases after 2 years; 1 case which was first seen in 1951 had healed in the meantime. It is to be stressed that the dates in the case histories are not to be relied upon, as every experienced specialist in tropical medicine will confirm; where figures are given, they should be treated with due reserve.

Case reports.

Case 1: Galla, aged about 40 years. 6 months' ambulatory treatment. Admitted to hospital for urethral stricture (gonorrhea), chronic malaria, hook-worm disease, ascaridiasis, secondary anemia (Hb. 32% Sahli), bronchitis, tropical ulcer above the right malleolus externus and on lower third of the right lower leg, 16×11 cm. in area, 1 cm. deep, fibula exposed for 5 cm. in a foul ulcer base. Ulcer treated from 6. 10. 48: therapy see page 1.

11. 1. 49: ulcer still measures 13×9 cm., epithelization beginning only towards the knee, ulcer base covered with grey greasy substance, only scanty granulation tissue. Same therapy continued.

3. 2. 49: intra-arterial injection of Acetylcholine 'Roche' 50 mg. into the right Art. femoralis which caused very sharp pain decreasing after about 5 minutes but for 2 hours giving the patient the impression that his foot was on fire. Bandage with cod-liver oil ointment, changed at the end of 8 days; the ulcer base is dark red and presents some islets of sound marginal granulations.

13. 2. 49: renewed injection of Acetylcholine 'Roche' 50 mg. intra-arterially. On 26. 2. the ulcer still measured 10×8 cm. and, with the exception of the area of exposed fibula, was covered with red granulations; bandages with physiological saline.

4. 3. 49: Thiersch graft covering over 2/3 of the ulcer area.

Discharge from hospital at the end of April with markedly contracted scar; protective bandage over the fibula which is covered only by fine skin.

Re-examination in February 1951 showed an insensitive scar adherent to the fibula with good function of the ankle joint.

Case 2: Galla, about 20 years of age, was admitted on 6. 9. 48. Chronic gonorrhea; *Entamoeba histolytica*, *Ascaris lumbricoides*, *Ancylostoma duodenale*, *Trichuris trichiura*; numerous widespread scars on both legs due to previous tropical ulcers. On the dorsum of the right foot, near the malleolus internus, a large punched-out tropical ulcer 1 cm. deep; the extensor tendons were exposed and torn. Excision of the wound, plaster bandage over cod-liver oil ointment for 5 weeks. Healing except for a 6×6 cm. area which was refractory to all measures and did not respond to skin grafts. The patient was given Acetylcholine 'Roche'—Prostigmin injections as described above, every second day to a total of 10 injections without particular success.

3. 1. 49: Acetylcholine 'Roche' 50 mg. intra-arterial injection, ointment bandage. A further 2 intra-arterial Acetylcholine injections of 75 mg. each at intervals of 5 days.

20. 1. 49: Successful skin graft.

Middle of February, discharge from hospital, with scar scarcely movable on the base. Re-examination 2 years later showed good insensitive scar with slight decrease of plantar flexion of the right foot as result of scar traction.

Case 3: Amhara, about 40 years of age, was admitted to hospital on account of relapsing fever, malaria (*Plasmodium falciparum*), ascarides, *Taenia saginata* and tropical ulcer on the left big toe. The tropical ulcer was reported to be caused by a small wound from an acacia thorn; the terminal phalanx of the big toe was swollen to twice the normal size, the whole of the dorsum being invaded by the ulcer which was purulent, with the borders curved outwards and exposing the terminal phalanx.

28. 12. 48: intra-arterial acetylcholine injection 50 mg. when the ulcer was clean. After 2 days a fine capillary hemorrhage was observed on the ulcer floor. Cod-liver oil bandage under plaster for 2 weeks and 2 further injections of Acetylcholine 'Roche' 75 mg. and 100 mg.

On removal of the plaster after further decrease in the swelling, the terminal phalanx still presented a defect of about 4 cm. which became covered by a fine epithelium after a further 3 weeks under plaster bandage. Discharge from hospital with protective bandage. The patient was given a fourth intra-arterial acetylcholine injection 100 mg. 10 days before removal of the plaster. Duration of treatment 6 weeks. Later examination was not possible.

Case 4: This 40-year-old Kaffa was first seen after he had already been given 0.6 gm. Mapharside and 10 c.c. bismuth subsalicylate in oil. Associated diseases: syphilis, malaria, *Ancylostoma duodenale*, *Taenia saginata*, scabies, trachoma. The whole of the left big toe was affected by a tropical ulcer out of which the terminal phalanx projected; the wound margins were as if sclerosed, thickened and protruding. The ulcer, which was of many months' duration, had first been treated by a native doctor with leaves, then burnt out with fire and powder. It did not respond to the antiluetic treatment or to sulfonamide therapy.

5. 12. 48: On admission to hospital, treatment referred to on page 159 was instituted.

From 28. 12. 48: 4 intra-arterial injections 50-100 mg. Acetylcholine 'Roche'. When discharged from hospital Case 4 still had a deep ulcer on the left big toe and the terminal phalanx had been sloughed. Further plaster bandages over balsam of Peru and cod-liver oil ointment caused no improvement and the left big toe had to be amputated a little above the main joint. The further course was undisturbed and the patient was discharged as recovered almost 4 months after admission.

On amputation of the big toe it was observed that scarcely any bleeding occurred, the vessels had thickened walls, narrow lumina and were very stiff. Histological examination was unfortunately impossible.

Case 5: Soldier, about 40 years old, complained of multiple tropical ulcers, and of a non-healing wound of 6 months' duration on the left lower leg which had been treated with various native remedies.

Malaria (*P. falciparum*), acute gonorrhea, syphilis, secondary anemia (Hb. 46%), *Ancylostoma duodenale*, *Ascaris lumbricoides*, *Strongyloides stercoralis*, *Taenia saginata*, *Trichuris trichiura*; impetigo on the face and neck, tropical ulcer 6 × 11 cm. in area and almost 1 cm. deep over the fibula in the lower third of the left lower leg; the fibula was exposed in two places. Had last been treated for 1 month with vioform powder.

14 days after admission to hospital it was decided to give acetylcholine injections intra-arterially. The ulcer was clean, without granulations; the undermined skin borders were cut away so that the wound became still larger.

At intervals of 6 days 5 intra-arterial injections Acetylcholine 'Roche' 50 mg., 75 mg., 75 mg., 100 mg. and 100 mg. were given. In addition, the patient received Mapharside up to 0.6 gm. and 2 c.c. Salbismol weekly. Ferrosolate,

vitamins B and C, a total of 24 gm. sulfadiazine for the gonorrhea. Plaster bandage with vioform powder for 5 weeks. On removal of the plaster bandage the ulcer was covered with skin over a few square cm.; in addition there were healthy red granulations. Skin graft, silver-foil bandage. Discharge from hospital after 10 weeks with insensitive scar adherent to the bone.

1951, re-examination: good scar, no relapse, final healing.

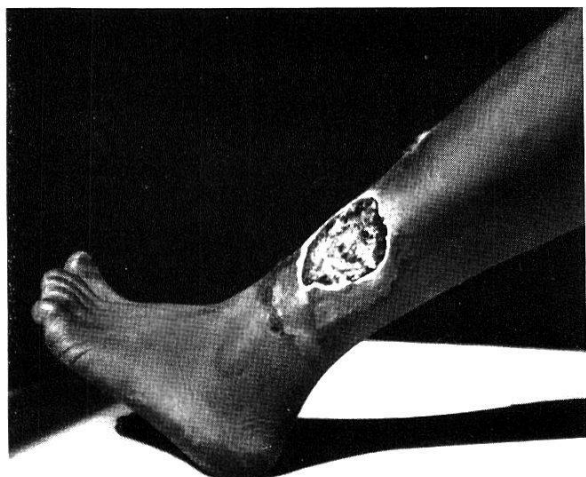
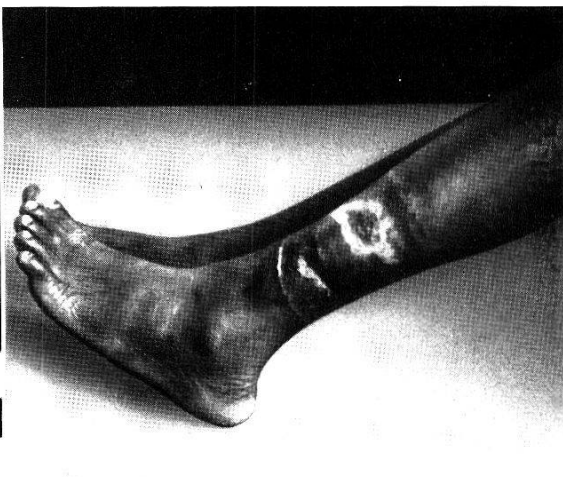Case 6: Galla, about 35 years of age, very poorly nourished. Had been in hospital several times during previous years for tropical ulcers. Admitted on 4. 11. 48. Scabies, chronic malaria, lues, chronic gonorrhea, amebic dysentery, ancylostomiasis, *Taenia saginata*, secondary anemia (Hb. 38%), trachoma blind in left eye, tropical ulcer 10×5 cm. over the Achilles tendon and the tuber calcanei which were completely exposed. Strong scar wall forming a border about 1 cm. broad around the fetid ulcer, 3 foci of infection undermining the skin were removed, the scars on the sole of the foot torn off. Treatment with Dakin's solution, ointment bandages as described above. After treatment of the other diseases and improvement in the nutritional state, at the beginning of January 1949, Acetylcholine injections 200 mg. i.m. daily for 10 days and thereafter every 2 days; on the days without injection 3×2 tablets Priscol to a total of 138 tablets. Scar tissue formed on the edges of the ulcer, the centre showed no granulations; balsam of Peru bandages. Hot saline solution, silver nitrate 5%, ichthyol, were all unsuccessful. Smears from the ulcer base on several occasions showed only leucocytes. Achilles tendon and bone still remained exposed. Skin grafting was twice unsuccessful. The patient was finally given 6 intra-arterial injections, 50, 75, 75, 100, 100 and 150 mg. After the injections the area surrounding the ulcer became darker in colour and warm; capillary bleeding occurred at the margin; only quite isolated rich granulations were observed peripherally towards the Achilles tendon. The ulcer was covered with cod-liver oil and the foot was placed in plaster in the right angle position. No other vasodilating measures were taken and finally after 10 months there was decrease in the size of the ulcer and stiffening of the ankle-joint because the Achilles tendon had become encased in the scar; about 6 sq.cm. of the tuber calcanei was exposed. The patient left hospital at his own request, having throughout refused a plastic flap.

Case 7: A 50-year-old Arab had for some 2 years been suffering from a refractory tropical ulcer. The ulcer was 13×9 cm. in area over the malleolus internus of the left lower leg, about $\frac{1}{2}$ cm. deep, with undermined irregular margins, half of which formed a thick scar with the Achilles tendon, leading to about 50% loss of ankle joint function. Wound smear showed fusiform bacteria, isolated Gram positive cocci, leukocytosis, scanty secretion from the tropical ulcer. Moderate edema of both lower legs and feet. Varices, the thickness of the little-finger, of the saphena magna inferior beneath the knee-joint. The tropical ulcer had at one time almost completely healed but then became very rapidly larger within a month. Treatment with acriflavin 1%, penicillin ointment, Neosalvarsan injections.

First of all on 27. 4. therapy was instituted according to the scheme on p. 159.

Finally weekly injections of Acetylcholine 'Roche' 50 mg. intra-arterially which caused severe pain. The swelling in the vicinity of the ankle increased after each of the last two intra-arterial acetylcholine injections; improvement in the circulation or tendency to granulation of the ulcer was not observed.

Later the patient was given 3 million units procaine-penicillin externally; the legs were elevated for weeks, the ulcer treated with plaster bandage over penicillin-cod-liver oil and was said finally to heal after several months; we had ourselves no opportunity to see the patient again.

*Fig. 1**Fig. 2*

Case 8: 25-year-old patient had been given ambulatory treatment for months with varying results with ointments and wet dressings and, finally, with adhesive plaster bandages and neosalvarsan injections.

Admitted to a Mission Hospital in December 1950. Malaria and other diseases; for his tropical ulcer, sulfonamide preparations i.v., boracic and gentian violet poultices. The ulcer which was 5×12 cm. in area and situated at the side of the tibia in the lower third of the right lower leg showed only slight tendency to healing.

In January 1951 the ulcer measured 10×7 cm., was about 1 cm. deep, appeared as if punched out of the surrounding scar tissue; the tibia was exposed over an area of about 3×2 cm.

Intra-arterial acetylcholine injections were given after operative exposure of the Art. femoralis in both inguinal regions on account of marked scar formations. At the same time the scar tissue was excised. 100 mg. acetylcholine were injected in 5 c.c. 0.5% procaine solution in 30 seconds into the left Art. femoralis. 5 days later the right Art. femoralis was exposed and injected in the same fashion, 4 cm. of the sympathetic nerve of the artery being excised in addition in order to increase and prolong hyperemia. Bandages with 5% silver nitrate solution; the patient was also given 500 mg. vitamin C i.v. Abundant granulations appeared within 2 weeks and an epithelial band $1\frac{1}{2}$ cm. wide on the ulcer margin. Skin transplantation led to healing and discharge from hospital in a further 3 weeks.

The above pictures illustrate the effect of intra-arterial injections of Acetylcholine 'Roche'. Condition before and after several injections (Case 5).

The following findings were common to all the cases. Without exception the patients found the injection painful, irrespective of the dosage¹.

They felt a burning of the feet for about an hour after the injection and often a feeling of heat or warmth from the second to the fourth day which, however, none of them found unpleasant. (Case 5 reported a stinging feeling in the feet, at first on the injected side and then on the other.) The effect of Acetylcholine 'Roche' intra-arterial injection must therefore be accepted as being not merely

¹ Pain on injection can be eliminated or at least markedly reduced by adding a 0.5-1% procaine solution to the acetylcholine (see case 8). This mixed injection may, however, only be given in cases without gangrene.

momentary but of prolonged duration. The opening up of the collateral circulation (SINGER) can cause prolonged improved blood flow.

Good posture and the use of very fine injection needles are important. The use of a coarse needle in one case caused a large subcutaneous hematoma which had to be punctured.

Unpleasant side-effects were not observed. Intra-arterial acetylcholine injections appeared to have a much stronger local action than subcutaneous or intramuscular injections which, as SINGER has already established, do not cause an appreciable general effect.

It would be of interest to investigate whether a further improvement in acetylcholine action, namely more prolonged effect, could be obtained by combination with vitamin B₁ or Prostigmin (inhibition of cholinesterase causing increase of acetylcholine action, stabilization of acetylcholine and dilation of arterioles in peripheral vascular spasms).

Conclusions.

On the basis of the cases treated the following conclusions may be drawn:

1. With the exception of cases 2 and 8, the patients were all middle-aged, in a state of poor nutrition and suffering in addition from a whole series of chronic debilitating diseases. No women are included in our cases because tropical ulcer is predominantly a disease of men. Out of about 5,000 cases of tropical ulcer in 3 provinces of South-west Ethiopia only 3% were women.

2. The treatment of associated diseases is of importance—it is for them that patients usually come for medical treatment—as is also improvement in the general condition (good diet, administration of iron and vitamins). At the beginning of the treatment the diseased limbs must be immobilized (bed-rest, sedentary occupations at a later stage).

3. Long duration of the disease and minimal response to local measures (ointments, baths, poultices) were common to all the cases.

4. In the majority of cases the subcutaneous or intramuscular injection of Acetylcholine 'Roche' with or without addition of Prostigmin (Roche), vitamin B₁, Priscol or Dilvasene, etc., was adequate in promoting the peripheral circulation. In severe chronic cases intra-arterial injection proved superior.

5. Failure of acetylcholine i.m. injection does not mean that intra-arterial injection will be unsuccessful. In fact, intra-arterial injections proved so effective that we believe they deserve trial in the treatment of all refractory cases of chronic tropical ulcer.

6. When the circulation of the affected extremity is impaired, intra-arterial injections will produce no better results than the other routes.

7. It is not absolutely necessary to make the injections on the same side as the ulcer (see case 8).

References.

1. KNOLL, H. (1949). Zur chirurgischen Behandlung des tropischen Ulcus. — *Acta trop.*, 6, 145-149.
2. KAPPERT, A. (1947). Die Behandlung der peripheren Durchblutungsstörungen. — *Praxis*, 36, 421-428.
3. SINGER, R. (1944). Die arterielle Injektion als Behandlungsmethode für periphere Durchblutungsstörungen. — *Mitt. Grenzgeb. Med. Chir.*, 47, 69-97.
4. ELLIS, L. B. & WEISS, S. (1932). A study of the cardiovascular responses in man to the intravenous and intra-arterial injection of acetylcholine. — *J. Pharmacol. exper. Therap.*, 44, 235-251.