

Miscellaneum : Mast cells in the myocardium : pathophysiological result of the variation in the number of the mast-cells : a geographic pathological approach

Autor(en): **Fernex, Michel**

Objektyp: **Article**

Zeitschrift: **Acta Tropica**

Band (Jahr): **18 (1961)**

Heft 2

PDF erstellt am: **23.05.2024**

Persistenter Link: <https://doi.org/10.5169/seals-310946>

Nutzungsbedingungen

Die ETH-Bibliothek ist Anbieterin der digitalisierten Zeitschriften. Sie besitzt keine Urheberrechte an den Inhalten der Zeitschriften. Die Rechte liegen in der Regel bei den Herausgebern.

Die auf der Plattform e-periodica veröffentlichten Dokumente stehen für nicht-kommerzielle Zwecke in Lehre und Forschung sowie für die private Nutzung frei zur Verfügung. Einzelne Dateien oder Ausdrucke aus diesem Angebot können zusammen mit diesen Nutzungsbedingungen und den korrekten Herkunftsbezeichnungen weitergegeben werden.

Das Veröffentlichen von Bildern in Print- und Online-Publikationen ist nur mit vorheriger Genehmigung der Rechteinhaber erlaubt. Die systematische Speicherung von Teilen des elektronischen Angebots auf anderen Servern bedarf ebenfalls des schriftlichen Einverständnisses der Rechteinhaber.

Haftungsausschluss

Alle Angaben erfolgen ohne Gewähr für Vollständigkeit oder Richtigkeit. Es wird keine Haftung übernommen für Schäden durch die Verwendung von Informationen aus diesem Online-Angebot oder durch das Fehlen von Informationen. Dies gilt auch für Inhalte Dritter, die über dieses Angebot zugänglich sind.

Miscellaneum.

Mast Cells in the Myocardium.

*Pathophysiological result of the variation in the number of the mast-cells:
A geographic pathological approach.*

By MICHEL FERNEX.

Swiss Tropical Institute, Basle.

Mast cells or "Mastzellen" were first described in 1877 by EHRLICH (18, 19), and are characterized by a protoplasm filled with basophil, metachromatic granules. These cells vary from 7 to 20 μ in diameter; they are more or less round, with protoplasmic projections. The nucleus is round, centrally situated, measures 5 μ and is sometimes hidden by the metachromatic granules.

The mast cells make their appearance towards the end of embryonic life, and are widely distributed throughout the connective tissues of the body. They are found in the loose perivascular connective tissue, in greater numbers in the digestive system, the bladder, the mammary gland, the uterus and abundantly near the epithelium of the skin, in the lungs, pleura and joint capsules (3, 31). They are few in the parenchyma of organs, but are present, however, in the capsules. Very exceptionally, in pathological states, they may reach the blood stream (10). In laboratory animals, their distribution is quite variable. The rat and mouse have an abundant quantity, whereas the guinea pig and the rabbit possess very few (12, 74).

The mast cells seem to take their origin in the proximity of the capillaries from which vicinity they migrate as they grow older (47, 69). Mitoses have been observed. They can also be derived from other conjunctive cells, particularly mesenchymatous cells, and also from histiocytes or even-lymphocytes.

Functions of the mast cells.

Sixty years after their discovery, the mast cells again became a matter of interest, when some Scandinavian workers (32, 76), while studying the anti-coagulant properties of a dog liver's extract, noticed that the granules of the mast cells, which are extremely abundant in that organ of the dog take the same stains as *heparin*. JORPES (32) showed that the amount of heparin extracted from the tissue is proportional to the number of mast cells which are referred to as heparinocytes. These cells can fix injected heparin and their study in animal tumours suggests that they synthetise this mucopolysaccharide (65, 34).

Experimentally, in dogs, a peptone shock produces a sudden degranulation of these cells, with liberation of heparin, which inhibites blood clotting. SCHILLING (64) describes a similar phenomenon in man, after pulmonary embolism or heart infarction.

ROCHA e SILVA (54) recorded, in 1952, the simultaneous liberation by the mast cells of heparin and *histamine* during anaphylactic shock. It seems that the granules of the mast cells are composed of a complex of these two substances (61). The introduction of "histamine liberators" (47, 49, 51, 52), which cause a splitting of the heparin-histamine complex, and a destruction of a large portion of the mast cells, apparently by holocrine secretion, has made it possible to confirm the view that the mast cell is in fact the source of histamine (62). The mast cell is capable of fixing circulating histamine, or

synthetising it from histidine, as can be demonstrated by the presence of histamine decarboxylase within the cell (63).

It has also been shown that, in a given tissue, the level of histamine varies with the number of mast cells (49). A few other cells seem also to be able to fix this tissue amine, for instance cells of the pyloric mucosa (50).

The relationship between the mast cell and 5 hydroxy-tryptamine (serotone) has so far been only partly explained. In the rat and in the mouse, it is generally accepted that mast cells produce serotonin (33, 41, 52, 75). In fact they contain 5 hydroxytryptophane decarboxylase which is necessary for the synthesis of this hormone. It is believed that, in man, circulating serotonin is produced in the chromaffin cells of the digestive tube, and liberated by the platelets during the formation of a thrombus. The role of the mast cells in the skin, in relation to this hormonal function is not generally accepted, and still remains obscure for other regions. In cardiac pathology, and especially in endocardial lesions arising in cases of malignant carcinoid, where there is an oversecretion of serotonin, there is an increase in the number of mast cells which is considered pathognomic for the disease (33).

The mast cells have a merocrine (67) or holocrine secretion during periods of stress or anaphylactic shock. In experimental shock, the rapid desintegration of a great number of mast cells liberates histamine into the blood stream, and in some animal species even heparin and serotonin (75).

Besides their endocrine function, the mast cells take part in the regeneration and healing of connective tissue after injury (3, 5). During the course of scar formation, their number varies considerably (4). They are abundant in oedematous connective tissue, rich in protein; for example, during inflammation or lymphostasis, and at the beginning of fibrillogenesis. It has been shown that the mast cell granules may be sometimes composed of hyaluronic acid which is one of the mucopolysaccharides of the ground substance (71). It is possible however that this is a question of reabsorption rather than secretion of this mucopolysaccharide, which the mast cell is to transform into mono-, di- and tri-phosphorylated heparin. The presence of mast cells in granulation tissue of subacute and chronic inflammation is a certain sign of cellular activity and appears to have some relation to fibrillogenesis and sclerosis (3, 35).

Variation in the number of mast cells.

The number of mast cells in the connective tissue depends on the state of reaction and imbibition of the tissue (5). The proliferation of these cells may take the form of a localised tumour (40), or even a benign or malignant disseminated reticulosis (7, 11, 14, 16, 77).

The number and functions of the mast cells are influenced by various hormones (14). One may consider all the mast cells together as a disseminated endocrine system. The thyrotropic hormone and the estrogens (74) appear to increase their number, while A.C.T.H. and cortisone reduce it (4, 17, 51). Diet seems to have some influence. High cholesterol intake reduces their number in rat, and experimental scurvy in guinea pigs also creates a masked reduction of these cells (45).

Mast cells and myocardium.

In man the mast cell has been the subject of far more investigations in the skin (14, 16, 11) and bone marrow (35, 53) than in the heart. In the myocardium, the increase in number of these cells has been observed in various diseases: beri-beri (17, 20, 38), the early stages of scleroderma (73), morbus *Waldenström* (29), certain cases of tuberculous cachexia (25) and some cases

of acute rheumatic fever. An increase in the number of mast cells has also been observed in cases of serous myocarditis (20, 21).

In human coronary sclerosis, and more distinctly in coronary arterio-sclerosis complicated by thrombotic occlusion, a reduction of these cells is observed (12, 42). The number of mast cells seems to decrease slightly with age: for example in the myocardium, the blood vessels and the skin (30).

Geographic cardiovascular pathology.

Cardiovascular pathology as seen in Dakar differs from that in Europe. In Africa, coronary thrombosis is extremely rare (22, 60), whereas interstitial non specific myocarditis is frequently encountered (15, 26, 43).

It is of interest to study the variation in the number of mast cells in the myocardium of this African population when taking into account the pathology and normal living conditions, which differ from those found in Europe, and then to compare the level of mast cells in those two different groups.

We examined hearts obtained from 82 consecutive autopsies, performed

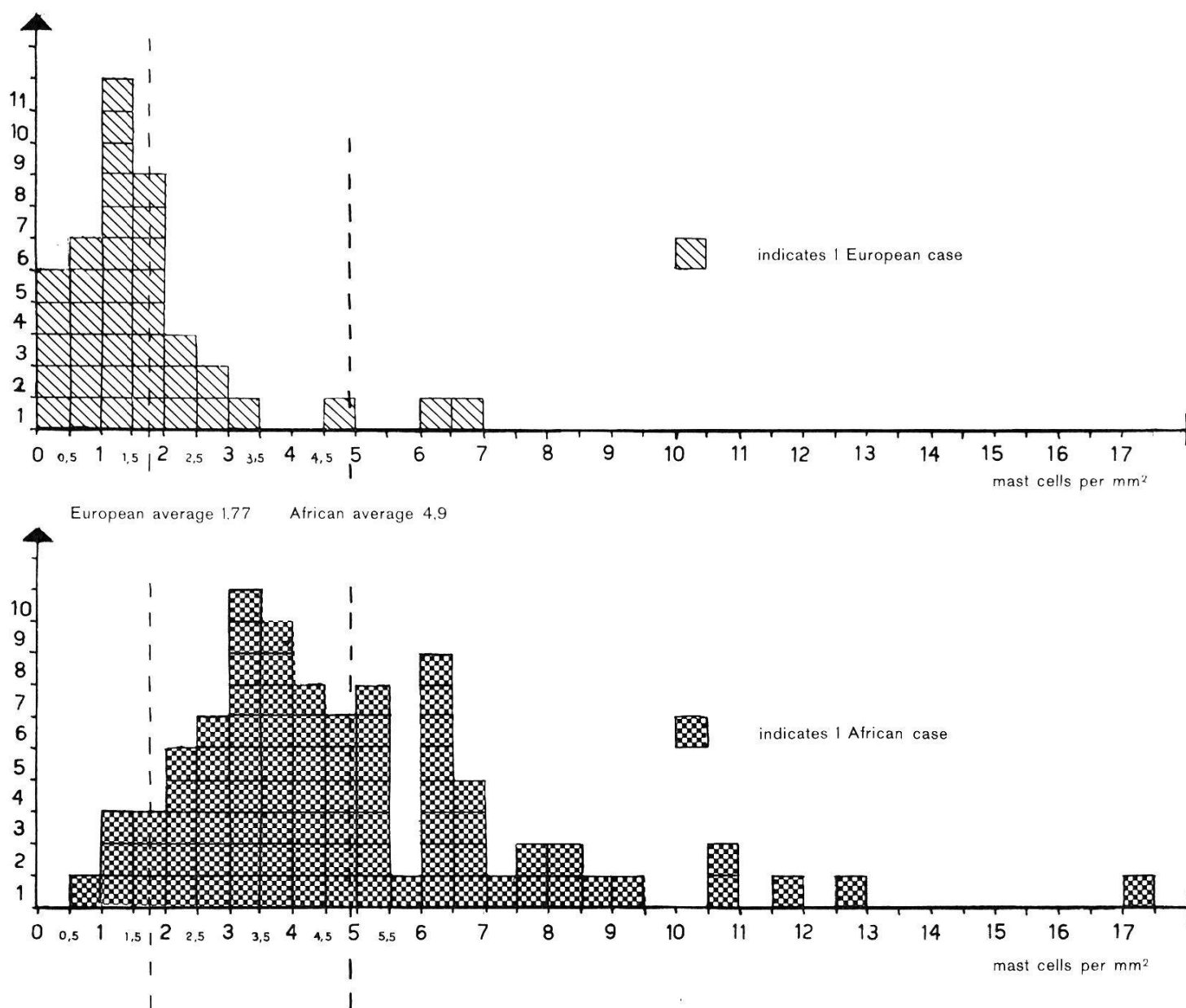


Fig. 1. Comparative estimation of mast cell count in a series of 39 Europeans (Paris) and 82 Africans (Dakar).

at Le Dantec Hospital in Dakar on a non selected series of Senegalese patients. The European controls were provided from 39 non selected patients from the Claude Bernard Hospital in Paris¹.

The autopsies were performed shortly after death. The myocardial tissue is always taken from the same region, that is, from the antero-lateral region of the left ventricle. The tissue is fixed in formalin at 10%, embedded in paraffin, cut at 7μ and stained with toluidine blue 0.1%. The cells were counted in 40 microscopic fields of $\frac{1}{3}$ mm². All the numbers listed on the following graphic are given in mm².

The above diagram shows that the average in the African series is almost three times higher than that of the European.

In the African, the cell number extends from 0,9 on the left to 17,4 per mm² on the right. Therefore, the question arises as to the interpretation that can be given of the extreme values obtained. In a simplified form, which are the cases associated with hyperplasia or with hypoplasia of the mast cells?

Mast cell hypoplasia in the myocardium.

In animals, the number of mast cells is shown to diminish with age. In man, however, this fall is not significant (18, 68).

There is no significant difference in the two age groups.

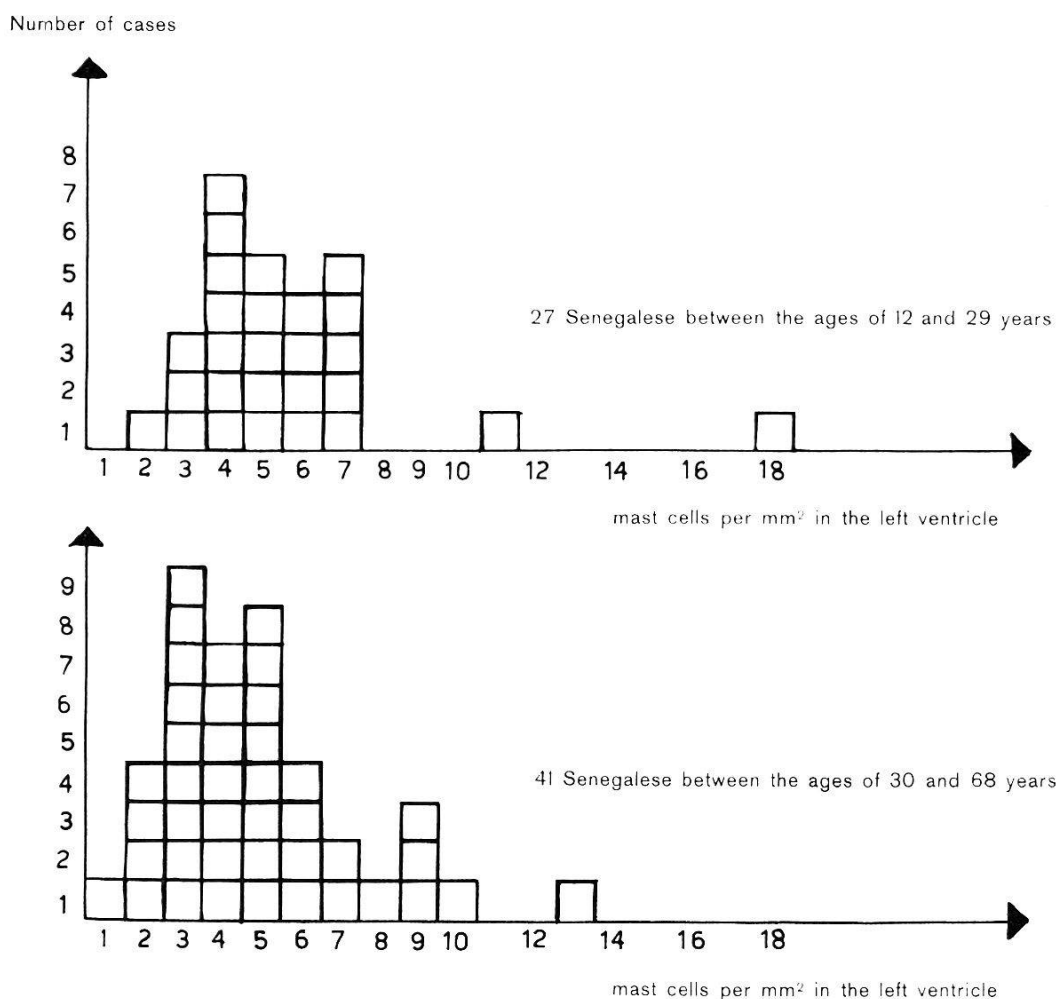


Fig. 2. Numerical variation in mast cell in the myocardium with respect to age.

¹ We are very grateful to Professor P. Mollaret, Claude Bernard Hospital, Paris, and to Professor M. Payet, Le Dantec Hospital, Dakar, who were kind enough to supply us with the material.

A discrete reduction with age may be related to atherosclerosis, which very often is more frequent in the aged (12). Comparing the cases with important coronary atherosclerosis with those of normal individuals, whatever their age, the difference becomes significant (42).

If in our African series we compare the number of mast cells of individuals having a slight or marked atheromatosis of the coronary arteries with that of those patients having no coronary atheromatosis, there appears an important difference.

Coronary atheromatosis in Dakar in relation to age.

Stenosing atheroma			1	2	1
Slight atheroma		1	2	5	4
Total (number of cases)	13	19	16	10	16

12 20 30 40 50 68 age →

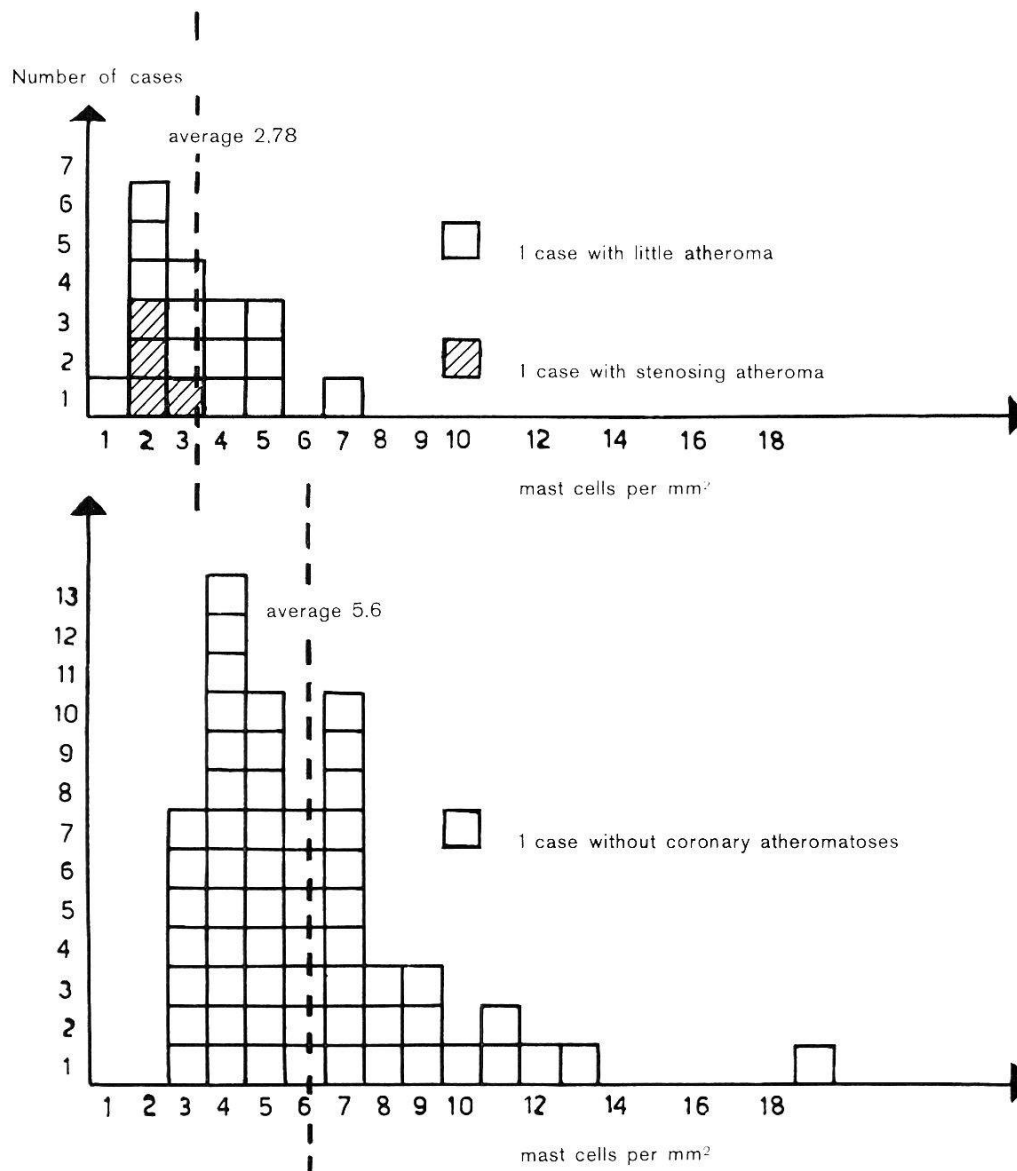


Fig. 3. Numerical variation of mast cells in cases with or without any coronary atheromatosis.

In Africans with slight atherosclerotic coronary arteries, the average level of the mast cells is nearly equal to that found in Europeans. Examining the 4 cases (fig. 3) with stenosing coronary atheromatosis, the average falls to 1.68 mast cell per mm^2 , an average lower than that of the European control series. Note the rarity of stenosing atheromatosis.

Discussion.

There is some relationship between atheromatosis and mast cells. WATSON (72) and CONSTANTINIDES (12) evoke the protective functions of mast cells in experimental atherosclerosis. The high level of mast cells in rats seems to make them resistant to induced arteriosclerosis by a cholesterogenic diet, while the rabbit, poorly endowed with mast cells, is very susceptible. WATSON, indeed, could only induce arteriosclerosis experimentally in rats, after he had destroyed their mast cells. Identical results have been observed by treating animals with corticosteroides or cold (66), both of which reduce the mast cell number.

In man, coronary arteriosclerosis and especially its ischaemic complications are somewhat related to modern civilization. Europeans seem to be predisposed

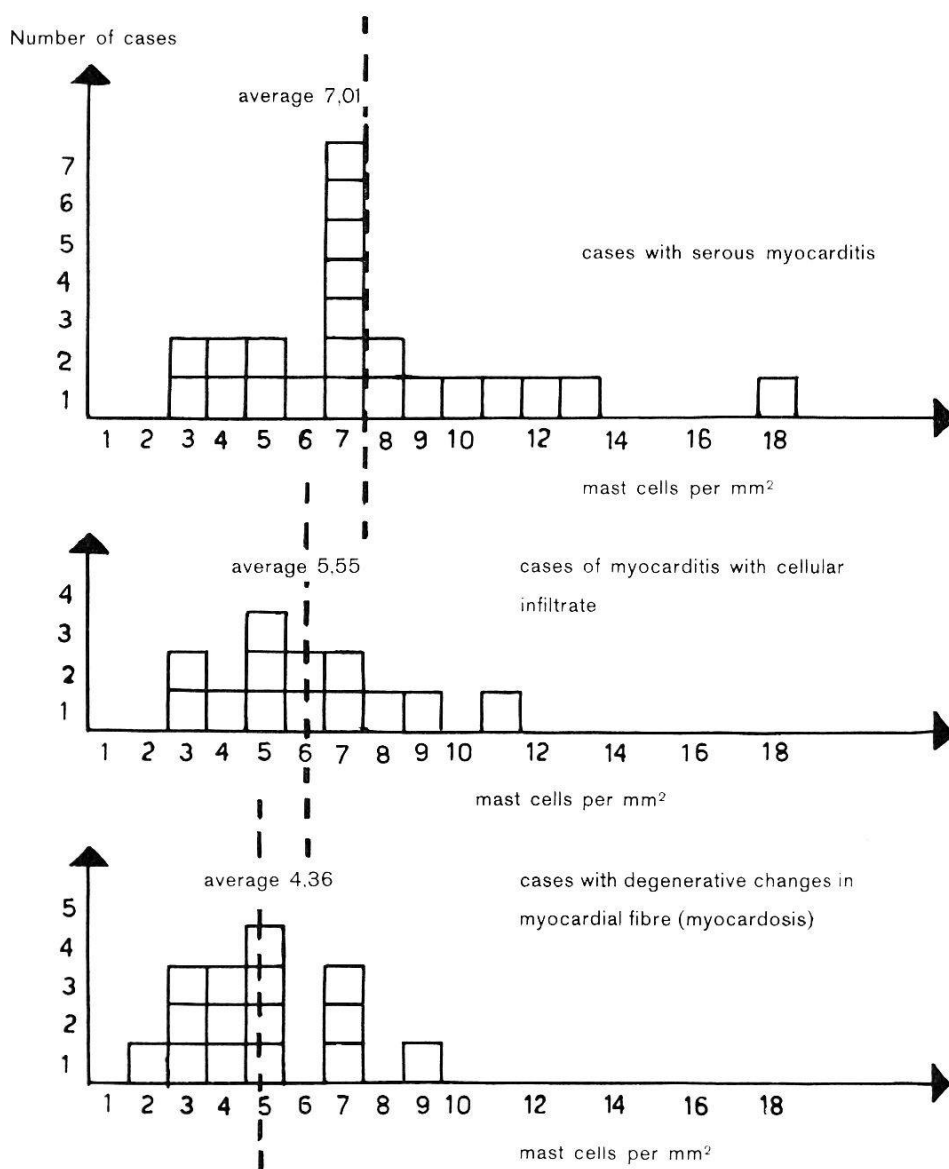


Fig. 4. Numerical variation of mast cells in different pathologic myocardial lesions.

perhaps by their diet and mode of life, and perhaps by their small number of mast cells.

The protective function of the mast cell may be associated with the secretion of heparin, the effects of which are multiple. This mucopolysaccharide is especially important in fat metabolism. It liberates the clearing factor, which reduces the chylomicrons (2, 8, 27, 28) and acts also on the vascular endothelium (37). In high concentrations, it is well known to be an anticoagulant.

Mast cell hyperplasia in the myocardium.

In a previous examination of cases having a high mast cell count in the myocardium, we showed the frequent association of "*mastocytosis*" with interstitial edema, corresponding to a serous myocarditis. We called this *mastocytic serous myocarditis*.

We will now distinguish several different types of myocardial alterations as seen in our African series, and compare the variations in mast cell number with relation to those lesions:

1. Serous myocarditis (22 cases).
2. Acute, subacute and granulomatous myocarditis (13 cases).
3. Degenerative disease of myocardial fibres (15 cases).

The figure 4 demonstrates the high mast cell level encountered in serous myocarditis. Excluding the cases of uremic serous myocarditis—the three cases on the extreme left of the figure with scanty mast cells—the average is even higher.

In cases of myocarditis with cellular exudation, the average number of mast cells is still high, though less than in the preceeding group.

When disease affects the myocardial fibres, the number of mast cells is not affected.

Physio-pathological function of the mast cell in the myocardium.

Mastocytic serous myocarditis is found to be the basic alteration in many idiopathic myocarditis observed at Dakar (21).

In these cases, as well as in fibrous endomyocarditis, one is struck by the appearance of a right side hypertension with dilatation of the pulmonary arteries. The rise in blood pressure in the pulmonary circulation is not due to a sclerosis of the pulmonary arterioles, but to a spasm, which ABRAHAMS and co-workers at Ibadan (1, 11) attribute to a chemical factor. This factor might be serotonin. In a recent paper, WEST (74) shows the rapid increase of serotonin and histamine in the rat during lactation and weaning. This could be a possible explanation of the idiopathic right side heart failure occurring in Senegalese women during the post partum and lactation period (44). A similar phenomenon might explain the pulmonary hypertension encountered in the syndrome of malignant carcinoid, a disease in which the mast cells in the endocardium are also increased (36).

The mast cell is certainly more than a mere indication of an increase in the secretion of serotonin, as far as the pathogenesis of myocarditis is concerned. In urticaria pigmentosa, a dermatitis in which there is a localized proliferation of mast cells in the skin, a very slight irritation is enough to produce a secretion of histamine with its consequences: dilatation of blood vessels, increase in capillary permeability, apparition of an oedema rich in proteins. This phenomenon corresponds to the first stage of an inflammation, referred to as serous inflammation (55, 56).

In the heart, serous inflammation may resolve completely, or many progress to a fibrous myocarditis (57), a condition met with very often in Africa: Senegal (43) as well as South Africa (15, 26).

Recent work suggests that heparin plays a part in the formation of fibrous tissue. In vitro, heparin causes fibrillogenesis, starting from a hydrolysed collagen (39). One must also take into consideration the views put forward by ASBOE-HANSEN (5) on the part played by mast cells in the variation in hyaluronic acid content of ground substance.

The mast cell, by its secretion of heparin, may favour the formation of collagen tissue. *Thus, in the African heart, the numerous mast cells, by their secretion of histamine cause serous inflammation to persist unduly, and by heparin secretion, favour the evolution from a serous to a fibrous myocarditis.*

Experiments in laboratory animals tend to confirm this hypothesis. Studies on the formation of fibrous tissue around foreign bodies can only be fruitful when working with animals having a high mast cell count, for example the rat. The rabbit and the guinea pig, which have few, do not produce but a negligible amount of collagen under similar conditions (58).

Conclusions.

Fibrous myocarditis, as a result of serous myocarditis, is a common pathological process which may be compared with and placed in the same group of other fibrosis frequently encountered in Africa, spoken of as the *fibrogenous diathesis*. This term indicates the tendency of the African to produce, under certain conditions, an excessive amount of fibrous tissue. In the African, a pseudo-arthritis nearly never occurs after bone fracture. On the contrary, the complication met with most frequently is the formation of an excessive hypertrophic callus.

In the skin of the African, the healing of a wound often results in the formation of a cheloid. When a cheloid is formed, mast cells are known to be very abundant in that area. Early radiotherapy prevents the formation of cheloids in a patient who is predisposed, as X-rays are known to destroy the mast cells (9, 45).

In a recent communication we demonstrated that the average number of mast cells in the derma of an African series is one and half as high as that of a corresponding European series (24).

The increased number of mast cells both in the myocardium and in the skin of an African population compared to an European control series together with its consequences (protection against atherosclerosis and tendencies to serous and fibrous inflammation), speak in favour of a generalized physiopathological process.

References.

1. ABRAHAMS, G. (1959). An unusual form of heart disease in West Africa. Its relationship to endomyocardial fibrosis. — *Lancet II*, 111.
2. ANGERVALL, G. & HOOD, B. (1957). Studies of heparin and lipemia clearing. — *Acta med. scand.* 157, 407.
3. ASBOE-HANSEN, G. (1950). The origin of synovial mucin. Ehrlich's mast cell, a secretory element of the connective tissue. — *Ann. rheum. Dis.* 9, 149.
4. ASBOE-HANSEN, G., BRODTHAGEN, H. & ZACHARIA, L. (1956). Treatment of cheloids with topical injections of hydrocortisone acetate. — *Arch. Derm. Syph.* 73, 162.
5. ASBOE-HANSEN, G. (1957). On the structure and functions of the mast cell. In: *Connective tissue*, ed. by R. E. Tunbridge et al. — Oxford: Blackwell.
6. ASBOE-HANSEN, G. (1959). Endocrine control of connective tissue. — *Amer. J. Med.* 26, 470.
7. BERLIN, C. (1955). Urticaria pigmentosa as a systemic disease. — *Arch. Derm. Syph.* 71, 703.

8. BLOCK, W. J., MANN, F. D. & BARKER, N. W. (1951). Effects of small doses of heparin in increasing the translucence of plasma during alimentary lipemia. Studies in normal individuals and patients with atherosclerosis. — *Circulation* 4, 464.
9. BRENK, VAN DEN, H. A. S. (1958). Observation on the mast cell changes, histamine release and local tissue damage in rats following X-irradiation. — *Brit. J. exp. Path.* 39, 356.
10. BRINKMANN, E. (1959). Mastzellenreticulose mit Histamin-bedingtem Flush und Übergang in gewebsbasophile Leukämie. — *Schweiz. med. Wschr.* 89, 1046.
11. BRODEUR, P. & GARDNER, L. T. (1956). Urticaria pigmentosa as a problem in diagnosis. Report of two cases, one with systemic involvement. — *New Engl. J. Med.* 254, 1165.
12. CAIRNS, A. & CONSTANTINIDES, P. (1953 & 1954). Mast cells in human atherosclerosis. — *Science* 117, 505; 120, 31.
13. COCKSHOT, P. W. (1960). Personal communication. University College Hospital, Ibadan, Nigeria.
14. COTTENOT, F. P. H. (1954). Contribution à l'étude de la physiologie normale et pathologique du mastocyte et de la substance fondamentale du tissu conjonctif. Thèse 823, Paris.
15. DAVIES, R. R., MARVEL, R. J. & GENOVESE, P. D. (1951). Heart disease of unknown etiology. — *Amer. Heart J.* 42, 546.
16. DEGOS, R. *et al.* (1951 & 1952). Réticulose à mastocytes. — *Bull. Soc. Franç. Derm. Syph.* 58, 435; 59, 247.
17. DURCK, H. (1908). Untersuchungen über die pathologische Anatomie des Beri-Beri. — *Ziegler Beitr. z. path. Anat. Suppl.* 8, 176.
18. EHRLICH, P. (1877). Beiträge zur Kenntnis der Anilinfärbungen und ihrer Verwendung in der mikroskopischen Technik. — *Arch. mikr. Anat.* 13, 263.
19. EHRLICH, P. (1879). Beiträge zur Kenntnis der granulierten Bindegewebszellen und der eosinophilen Leukocyten. — *Arch. Anat. Physiol.* 3, 166.
20. FERNEX, M. (1958). Aspect anatomo-pathologique du cœur béribérique à Dakar : une myocardite séreuse à mastocytes. Rapport du Congrès Internat. de Médecine Tropicale et du Paludisme à Lisbonne.
21. FERNEX, M. (1960). Contribution à l'étude physio-pathologique des mastocytes dans le myocarde. — *Actual. Cardio. angéiol. int.* 9, 269.
22. FERNEX, M. (1961). Observations sur l'état anatomo-histologique des artères des malades africains. Deuxièmes Journées Méd. de Dakar. — *Méd. d'Afrique Noire* 8, 66.
23. FERNEX, M. (1961). Répercussions physio-pathologiques de la variation du nombre des mastocytes dans le myocarde. Deuxièmes Journées Méd. de Dakar. — *Méd. d'Afrique Noire* 8, 90.
24. FERNEX, M. (1961). Mastzellenzahl in ihrer Beziehung zur Atherosklerose. Mitt. an die Schweiz. Ges. f. inn. Med. To be published in *Helv. Med. Acta*.
25. FISCHER, H. (1937). Gewebsmastzellen in menschlichen Herzen. Diss. Berlin.
26. GILLANDERS, A. D. (1951). Nutritional heart disease. — *Brit. Heart J.* 13, 177.
27. GRAHAM, D. M. *et al.* (1951). Blood lipids and human atherosclerosis. The influence of heparin upon lipoprotein metabolism. — *Circulation* 4, 666.
28. HAHN, P. F. (1943). Abolishment of alimentary lipemia following injection of heparin. — *Science* 98, 19.
29. HAMPTON, J. W. (1958). Waldenström macroglobulinaemia. Clinical and pathological report of a case resembling multiple myeloma. — *New Engl. J. Med.* 258, 1293.

30. HELLSTROM, B. & HOLMGREN, H. (1950). Numerical distribution of mast cells in the human skin and heart. — *Acta anatomica* 10, 81.
31. JANES, J. & McDONALD, J. R. (1948). Mast cells, their distribution in various human tissues. — *Arch. Path.* 45, 622.
32. JORPES, J. E., HOLMGREN, H. & WILANDER, O. (1937). Über das Vorkommen von Heparin in den Gefäßwänden und in den Augen. — *Z. mikr.-anat. Forsch.* 42, 279.
33. KELLER, R. (1960). Biochemische Eigenschaften und physiologische Bedeutung der Gewebsmastzellen. — *Schweiz. med. Wschr.* 90, 503.
34. KORN, E. D. (1958). The synthesis of heparin in mouse mast cell tumour slices. — *J. Amer. Chem. Soc.* 80, 1520.
35. LENNERT, K. & SCHUBERT, C. F. (1958/59). Untersuchungen über die sauren Mucopolysaccharide der Gewebsmastzellen im menschlichen Knochenmark. — *Frankf. Z. Path.* 69, 579.
36. McDONALD, R. A. & ROBBINS, S. L. (1957). Pathology of the heart in the carcinoid syndrome. A comparative study. — *Arch. Path.* 63, 103.
37. MCGOVERN, V. J. (1955). Reactions to injury of vascular endothelium with special reference to the problem of thrombosis. — *J. Path. Bact.* 69, 283.
38. MIURA, M. (1888). Pathologie der Kakke. — *Virch. Arch. path. Anat.* 111, 361; 114, 341; 115, 355.
39. MORRIONE, T. G. (1952). The formation of collagen fibres by the action of heparin on soluble collagen. — *J. exp. Med.* 96, 107.
40. OHO, S. *et al.* (1959). Relation of mastocytoma to mast-cell leukemia, and of heparin, histamine and serotonin to mast-cells. — *Blood* 14, 770.
41. PARRAT, J. R. & WEST, G. B. (1957). 5-Hydroxytryptamine and tissue mast cells. — *J. Physiol.* 137, 169.
42. PATERSON, J. C. & MILLS, J. (1958). Myocardial mast cell counts in coronary sclerosis. — *Arch. Path.* 66, 335.
43. PAYET, M. & ARMENGAUD, M. (1957). Etude clinique et pathogénique du cœur chez les grands anémiques et dans certains états myocardiques séquelles. — *Presse méd.* 84, 1877.
44. PAYET, M., FERNEX, M. & CACHIA, P. (1961). La myocardite du post-partum. To be published in *Presse méd.*
45. PETTERSON, T. (1954). Effects of X-ray total body irradiation on mast cell count in the skin. Experimental investigation on guinea-pigs. — *Acta path. microbiol. scand. Suppl.* 102, 1.
46. PETTERSON, T. (1959). Scurvy as a cause of morphological changes in mast cells in the guinea-pig. — *Acta path. microbiol. scand.* 45, 32.
47. RILEY, J. F. (1953). The effects of histamine-liberators on the mast cells of the rat. — *J. Path. Bact.* 65, 471.
48. RILEY, J. F. (1954). The riddle of the mast cells. A tribute to Paul Ehrlich. — *Lancet* 841.
49. RILEY, J. F. & WEST, G. B. (1955). Tissue mast cells. Studies with a histamine-liberator of low toxicity. — *J. Path. Bact.* 69, 269.
50. RILEY, J. F. & WEST, G. B. (1956). A binding site for histamine in hog pyloric mucosa. — *Experimentia* 12, 153.
51. RILEY, J. F. (1959). The mast cells. — Edinburgh and London: E. & S. Livingstone Ltd.
52. RILEY, J. F. (1960). Die Mastzellen. — *Endeavour* 19, 4.
53. ROHR, K. (1952). Reaktive Retikulosen des Knochenmarks. — 3^e Congrès de la Soc. Internat. Européenne d'hématologie, Rome, 268.
54. ROCHA & SILVA, M. (1952). Concerning the mechanism of anaphylaxis and allergy. — *Brit. med. J.* 1, 779.
55. ROSSLE, R. (1933). Über die Veränderungen der Leber bei der Basedowschen

- Krankheit und ihre Bedeutung für die Entstehung anderer Organsklerosen. — *Virchows Arch. path. Anat.* 291, 1.
56. ROSSLE, R. (1943). Über die serösen Entzündungen der Organe. — *Virchows Arch. path. Anat.* 311, 252.
57. ROULET, F. (1935). Myocardite séreuse dans la grippe et les endocardites. Apparition d'œdème et sa transformation hyaline. — *Virchows Arch. path. Anat.* 295, 438.
58. ROULET, F. (1960). Communication personnelle. Bâle.
59. ROWLEY, D. A. *et al.* (1956). 5-Hydroxytryptamine and histamine as mediators of the vascular injury produced by agents which damage mast cells in rats. — *J. exp. Med.* 103, 399.
60. SANKALE, M. (1960). L'athérosclérose chez le Noir Africain. Deuxièmes Journées Méd. de Dakar. Vol. des rapports.
61. SAMYAL, R. K. & WEST, G. B. (1959). The Histamine Heparin Complex. — *J. Pharm. Pharmacol.* 11, 548.
62. SCHAUER, A. & WEHRLE, E. (1959). Zur histochemischen Darstellung des Histamins der Mastzellen. — *Z. ges. exp. Med.* 131, 100.
63. SCHAYER, R. W. (1956). Formation and binding of histamine by gree mast cells of rat peritoneal fluid. — *Amer. J. Physiol.* 186, 199.
64. SCHILLING, F. J. & DE NATALE, A. (1949). Naturally occurring anticoagulants and accelerator substance in human blood. — *Amer. J. med. Sci.* 218, 70.
65. SCHÜRER, W. (1946). Speicherung von Heparin in den Zellen des Retikulo-endothels. — *Helv. med. Acta* 13, 161.
66. SELLER, E. A. & BAKER, D. G. (1960). Coronary atherosclerosis in rats exposed to cold. — *Canad. med. Ass. J.* 83, 6.
67. SMITH, D. E. (1958). Nature of the secretory activity of the mast cell. — *Amer. J. Physiol.* 193, 573.
68. SUNDBERG, M. (1955). On the mast cells in the human vascular wall. A quantitative study on changes at different ages. — *Acta path. microbiol. scand.* 107, 81.
69. TAKEDA, Y. (1958). On the origin of the tissue mast cell. — *Akijimas Fol. Anat. Japon.* 31, 143.
70. UNDRITZ, E. (1946). Les cellules sanguines dans l'homme et dans la série animale. — *Schweiz. med. Wschr.* 76, 115.
71. VELICAN, C. & VELICAN, D. (1959). Histochemical investigations on the presence of hyaluronic acid in mast cells. — *Acta haemat.* 21, 109.
72. WATSON, W. C. (1958). The role of the tissue mast cell in experimental atherosclerosis. — *Brit. J. exp. Path.* 39, 540.
73. WEGELIUS, O. & WAHLBERG, P. (1957). Early cardiac connective tissue change in scleroderma. Report of a case. — *Acta med. scand.* 156, 487.
74. WEST, G. B. (1959). Tissue mast cells and tissue amines. — *J. Pharm. Pharmacol.* 11, 513.
75. WEST, G. B. & PARRAT, J. R. (1957). 5-Hydroxytryptamine and the skin. — *Arch. dermatol.* 76, 336.
76. WILANDER, O. (1938). Studien über Heparin. — *Skand. Arch. Physiol.* 86, Suppl. 15.
77. ZAK, F. G., COVEY, J. A. & SNODGRASS, J. J. (1957). Osseous lesions in urticaria pigmentosa. — *New Engl. J. Med.* 256, 56.
-