

Zeitschrift: Acta Tropica
Herausgeber: Schweizerisches Tropeninstitut (Basel)
Band: 39 (1982)
Heft: 4

Artikel: Experimental superimposed infection of the hamster with "Leishmania mexicana" and "L. braziliensis"
Autor: Zeledón, R. / Soto, R. / González, G.
DOI: <https://doi.org/10.5169/seals-312997>

Nutzungsbedingungen

Die ETH-Bibliothek ist die Anbieterin der digitalisierten Zeitschriften auf E-Periodica. Sie besitzt keine Urheberrechte an den Zeitschriften und ist nicht verantwortlich für deren Inhalte. Die Rechte liegen in der Regel bei den Herausgebern beziehungsweise den externen Rechteinhabern. Das Veröffentlichen von Bildern in Print- und Online-Publikationen sowie auf Social Media-Kanälen oder Webseiten ist nur mit vorheriger Genehmigung der Rechteinhaber erlaubt. [Mehr erfahren](#)

Conditions d'utilisation

L'ETH Library est le fournisseur des revues numérisées. Elle ne détient aucun droit d'auteur sur les revues et n'est pas responsable de leur contenu. En règle générale, les droits sont détenus par les éditeurs ou les détenteurs de droits externes. La reproduction d'images dans des publications imprimées ou en ligne ainsi que sur des canaux de médias sociaux ou des sites web n'est autorisée qu'avec l'accord préalable des détenteurs des droits. [En savoir plus](#)

Terms of use

The ETH Library is the provider of the digitised journals. It does not own any copyrights to the journals and is not responsible for their content. The rights usually lie with the publishers or the external rights holders. Publishing images in print and online publications, as well as on social media channels or websites, is only permitted with the prior consent of the rights holders. [Find out more](#)

Download PDF: 11.07.2025

ETH-Bibliothek Zürich, E-Periodica, <https://www.e-periodica.ch>

¹ Instituto Costarricense de Investigación y Enseñanza en Nutrición y Salud, Dr. Uriel Badilla Fernández (INCIENSA), Apartado 4, Tres Ríos, Costa Rica

² Servicio de Patología, Hospital Dr. Fernando Escalante Pradilla, Pérez Zeledón, Costa Rica

Experimental superimposed infection of the hamster with *Leishmania mexicana* and *L. braziliensis*

R. ZELEDÓN¹, R. SOTO¹, G. GONZÁLEZ²

Summary

Hamsters inoculated subcutaneously with *Leishmania mexicana* (*L. m. amazonensis* or *L. m. mexicana*) and with *L. braziliensis panamensis*, either simultaneously or with an interval, in different parts of the body (right front paw and nose), showed an independent course of infection for either parasite with the typical clinical and histopathological characteristics produced by these organisms. In one group of animals, metastases from the paw (*L. m. amazonensis*) to the nose (*L. b. panamensis*) was proven and the partial transformation of the granuloma from epithelioid and giant multinuclear cells (tuberculoid) to histiocytes full of parasites (lepromatous), was observed. These two specific contrasting reactions, are confined to the place of infection and influenced by the type of parasite. The histopathological picture normally observed in hamsters as a reaction to *L. mexicana* s.l., occurs only occasionally in humans. It is suggested, on the basis of this animal model, that DCL in the New World is only produced by parasites of the “mexicana” complex and that both parasite characteristics and host immune status are responsible for this phenomenon.

Key words: *Leishmania mexicana mexicana*; *L. m. amazonensis*; *L. braziliensis panamensis*; hamster; superimposed infection; histopathology; diffuse cutaneous leishmaniasis (DCL).

Introduction

Inoculation of hamsters with *Leishmania* parasites of the “mexicana” complex produces large tumors consisting of macrophages rich in parasites; this

Correspondence: Dr. R. Zeledón, INCIENSA, Apartado 4, Tres Ríos, Costa Rica

infection has the tendency to spread metastatically to other areas of the animal body. On the other hand, parasites belonging to the "braziliensis" complex produce only small nodules with few parasites and a different histological picture. In this case metastasis is quite rare; if it occurs, the metastatic lesions remain inconspicuous (Lainson and Shaw, 1979). Similar pictures can be observed in humans infected with the same groups of parasites but in this case the "malignant" or lepromatous type of leishmaniasis is produced only when some type of cellular immunological impairment is present in the patient; for this reason it is apparently not so commonly seen. According to Convit and Pinardi (1974) this so-called diffuse cutaneous leishmaniasis (DCL), "... is due fundamentally to the response of the host, and the characteristics of the infecting strain of *Leishmania* can only secondarily influence the type of lesion that appears". This statement suggests that in the New World any type of *Leishmania* responsible for cutaneous lesions could potentially produce the clinical picture of DCL. Nevertheless, all evidence up to now shows that all cases of DCL are associated with organisms of the *L. mexicana* complex and their geographical distribution corresponds to those places where parasites of this complex occur (Lainson and Shaw, 1979). There is also evidence that the immunological unresponsiveness observed in these patients with DCL is specific for the infection with *Leishmania* (Bryceson, 1970). To clarify the basis of these phenomena we used the hamster model to study the course and characteristics of superimposed infections produced by these two types of *Leishmania*.

Materials and Methods

A total of 27 adult hamsters divided in 9 groups of 3 animals each, was inoculated subcutaneously as presented in Table 1. *L. mexicana mexicana*, corresponding to the O-CR strain of Zeledón et al. (1981), was used after the second or third transfer in Senekjie's medium following isolation from an experimentally infected monkey. *L. mexicana amazonensis* was isolated in 1975 from a patient in Brasilia, and was obtained from Dr. Cesar Cuba Cuba, and used in the first transfer after reisolation from a hamster. *L. braziliensis* (HSJD-36) was isolated from an ulcer of Costa Rican patient, had biological characteristics of *L. b. panamensis*, and was used after two transfers in culture following isolation from a hamster. Reisolates of the parasites were identified on biological grounds (culture behavior and animal inoculation). Sections of the lesions were made for histopathological studies and stained with hematoxylin-eosin.

Results

Nodules were first noticed two weeks after inoculation. Those of *L. mexicana* s.l. grew faster and became larger than those produced by *L. braziliensis*. After one or two months groups 1 and 2 exhibited well developed tumors in the paw and small nodules in the nose (Fig. 1). Groups 3, 4 and 5 (controls) presented lesions, of similar size to those of the previous groups inoculated with corresponding subspecies. In groups 6 and 8, one and two months after the respective challenges, the lesions followed a clinical course identical to those of

Table 1. Inoculation of 27 hamsters with *L. mexicana* and *L. braziliensis*

Group	Parasite	Inoculum ($\times 10^6$)	Place of inoculation	Remarks
1	<i>L. m. mexicana</i>	64	r.h.	simultaneous
	<i>L. b. panamensis</i>	38	n.	inoculations
2	<i>L. m. amazonensis</i>	35	r.h.	simultaneous
	<i>L. b. panamensis</i>	38	n.	inoculations
3	<i>L. m. mexicana</i>	64	r.h.	control of group 1
4	<i>L. m. amazonensis</i>	35	r.h.	control of group 2
5	<i>L. b. panamensis</i>	38	n.	control of groups 1 and 2
6	<i>L. m. mexicana</i>	64	r.h.	<i>L. b. panamensis</i> inoculated 6 weeks after <i>L. m. mexicana</i>
	<i>L. b. panamensis</i>	38	n.	
7	<i>L. b. panamensis</i>	38	n.	control of group 6
8	<i>L. b. panamensis</i>	38	r.h.	<i>L. m. mexicana</i> inoculated 6 weeks after <i>L. b. panamensis</i>
	<i>L. m. mexicana</i>	70	n.	
9	<i>L. m. mexicana</i>	70	n.	control of group 8

r.h. = dorsal part of the right front paw

n. = nose

the control groups (7 and 9). There was a tendency for *L. m. amazonensis* to produce ulcerations and evident points of necrosis. After four months two animals of group 2 (one had died) exhibited metastases to the other paws and to the tail; at that time, the lesions on the nose became more evident (tumors closer to the "mexicana" type), and a culture from this site revealed *L. m. amazonensis*. In the rest of the groups, the pictures continued as previously; two animals of group 4 and one from group 5 died at that time. After 5 months one of the animals of group 6 presented metastases to the other paws but no evidence of lesions of the nose. At month 6 the discrete lesions of the right paws of the animals of group 8 became more evident and larger than those of the control group (Figs. 2 and 3). No evidence of metastases was observed in the other paws. Three punctures at different intervals up to the 8th month gave always rise to positive cultures, but only with *L. b. panamensis*. Also animals inoculated with this new isolate exhibited the typical lesions of this subspecies. The experiment was concluded after ten months and the animals left were killed.

Histopathological examination of the appropriate sites on those animals inoculated with either subspecies of *L. mexicana*, showed the typical granuloma consisting of histiocytes full of parasites. In both arterial and venous vessels, emboli were observed consisting of erythrocytes and free of intracellular parasites, indicating their transport by the blood. In some areas plasma cells in variable numbers were noticed as well as focal necrosis associated with *in situ* arterial thrombosis with numerous parasites; also edema and abundant collagen tissue

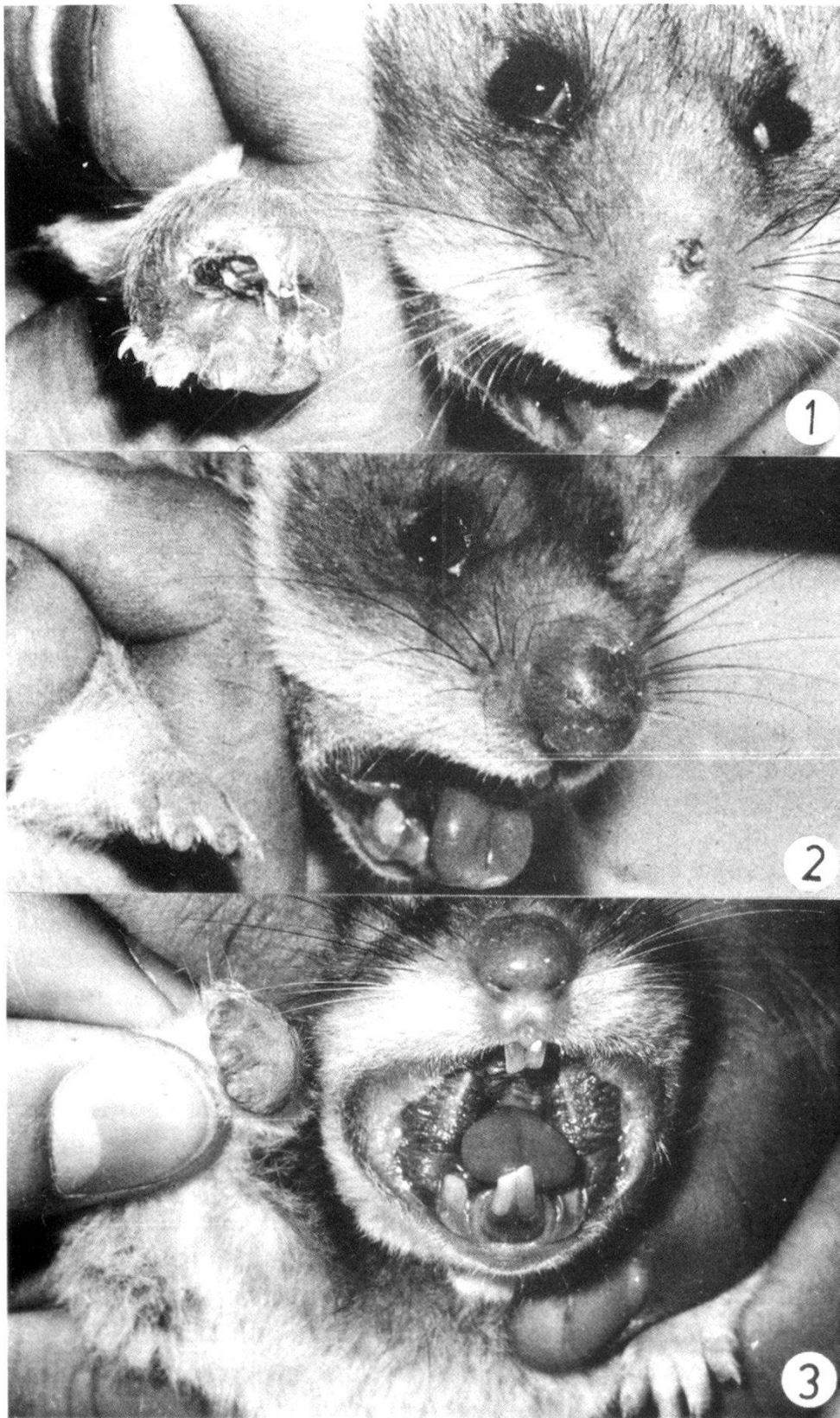


Fig. 1. Lesions produced by *L. m. mexicana* (O-CR) on the right paw and by *L. b. panamensis* (HSJD-36) on the nose after 3 months.

Fig. 2. Lesion produced by *L. m. mexicana* (O-CR) on the nose and by *L. b. panamensis* (HSJD-36) on the right paw after 3 months.

Fig. 3. As in Fig. 2 after 10 months.

in the dermis was common. In both animals of group 2 which suffered metastases of *L. m. amazonensis* from the front paw to the nose, where *L. b. panamensis* had originally been inoculated, the same general *L. mexicana* histopathological picture was predominant in the nose, alternating with small patches of lymphoplasmocyte infiltrate and occasional giant cells. In those animals with typical lesions of *L. braziliensis*, the tissue reaction was formed by granulomas of epithelioid and giant multinucleate cells of foreign body type, which were also disseminated, and greater proliferation of fibro-collagen tissue was observed. There were some histiocytes with very few parasites and various numbers of lymphocytes and plasma cells. In animals of group 8, in which we suspected a metastasis of *L. m. mexicana* from the nose to the front paw, the histological picture was that of *L. braziliensis* infection, although with marked edema, confirming the results of cultures obtained from the paw.

Discussion

The simultaneous inoculation of a hamster with *Leishmania* of the “mexicana” and “braziliensis” complexes indicated that the typical reactions produced by this animal in response to each one of these parasites, followed the same pattern, both micro- and macroscopically, as if they had been injected separately in different animals. This course of infection was not even affected when the host was challenged with a second *Leishmania* of a different complex after the first strain had established a typical infection. The two specific reactions, indicating a lack of specific immunological cellular responsiveness to *L. mexicana* and a rather strong response to *L. braziliensis* seemed to be confined to the place of infection of the skin. This phenomenon was further shown by the fact that a well established typical *L. braziliensis* tissue reaction at a particular site can suddenly change to a *L. mexicana* reaction if the latter metastasizes to that place. The hamster model indicated that particular characteristics of these two groups of parasites were at least partly responsible for the opposite responses of the host.

Further evidence supporting the suggestion of Lainson and Shaw (1979) that DCL in man in the New World is caused only by organisms of the *L. mexicana* complex would indicate that this condition is not produced only by some immunological “defect” of the host, as claimed by Convit et al. (1972), but rather by the association of both host-specific and parasite-specific factors. This association would be more consonant with Bryceson’s idea (Bryceson, 1970) that “certain strains of *Leishmania* are capable of causing DCL by virtue of the absence of a particular antigen or antigens, and thereby failing to induce an adequate immune response, or by the possession of a ‘tolerogen’, a specific determinant lethal to the clone of cells potentially able to respond to a particular leishmanial antigen”. Our experimental model, even though different from

the human suggests, however, that the mechanisms involved in the phenomenon could be even more complex.

The reaction observed in the animals of group 8, which presented consistently larger *L. braziliensis* lesions than those of the control animals after 6 months, without a detectable metastasis of *L. mexicana* to the site, apparently due to marked edema, remains unexplained.

Bryceson A. D. M.: Diffuse cutaneous leishmaniasis in Ethiopia. III. Immunological studies. IV. Pathogenesis of diffuse cutaneous leishmaniasis. *Trans. roy. Soc. trop. Med. Hyg.* 64, 380–393 (1970).

Convit J., Pinardi M. E.: Cutaneous leishmaniasis. The clinical and immunopathological spectrum in South America. In: Trypanosomiasis and leishmaniasis, with special reference to Chagas' disease. CIBA Foundation Symp. 20 (New Series), 159–166 (1974).

Convit J., Pinardi M. E., Rondon A. J.: Diffuse cutaneous leishmaniasis: a disease due to an immunological defect of the host. *Trans. roy. Soc. trop. Med. Hyg.* 66, 603–610 (1972).

Lainson R., Shaw J. J.: The role of animals in the epidemiology of South American leishmaniasis. In: Biology of the kinetoplastida, ed. by W. H. R. Lumsden and D. A. Evans, Vol. 2, 1–116. Academic Press, New York 1979.

Zeledón R., Soto R., Ponce C., Murillo J., Chaves F.: On the apparent absence of *Leishmania mexicana* in Costa Rica. *Trans. roy. Soc. trop. Med. Hyg.* 75, 753–754 (1981).