

Proliferating larval cestodiasis : report of a case

Autor(en): **LaChance, M.A. / Clark, R.M. / Connor, D.H.**

Objekttyp: **Article**

Zeitschrift: **Acta Tropica**

Band (Jahr): **40 (1983)**

Heft 4

PDF erstellt am: **25.05.2024**

Persistenter Link: <https://doi.org/10.5169/seals-313147>

Nutzungsbedingungen

Die ETH-Bibliothek ist Anbieterin der digitalisierten Zeitschriften. Sie besitzt keine Urheberrechte an den Inhalten der Zeitschriften. Die Rechte liegen in der Regel bei den Herausgebern.

Die auf der Plattform e-periodica veröffentlichten Dokumente stehen für nicht-kommerzielle Zwecke in Lehre und Forschung sowie für die private Nutzung frei zur Verfügung. Einzelne Dateien oder Ausdrucke aus diesem Angebot können zusammen mit diesen Nutzungsbedingungen und den korrekten Herkunftsbezeichnungen weitergegeben werden.

Das Veröffentlichen von Bildern in Print- und Online-Publikationen ist nur mit vorheriger Genehmigung der Rechteinhaber erlaubt. Die systematische Speicherung von Teilen des elektronischen Angebots auf anderen Servern bedarf ebenfalls des schriftlichen Einverständnisses der Rechteinhaber.

Haftungsausschluss

Alle Angaben erfolgen ohne Gewähr für Vollständigkeit oder Richtigkeit. Es wird keine Haftung übernommen für Schäden durch die Verwendung von Informationen aus diesem Online-Angebot oder durch das Fehlen von Informationen. Dies gilt auch für Inhalte Dritter, die über dieses Angebot zugänglich sind.

¹ Department of Infectious and Parasitic Disease Pathology, Armed Forces Institute of Pathology, Washington, DC USA

² Department of Pathology, Oshawa General Hospital, Oshawa, Ontario, Canada

Proliferating larval cestodiasis: report of a case*

M. A. LACHANCE¹, R. M. CLARK², D. H. CONNOR¹

Summary

A 72-year-old Filipino man who had emigrated to Canada had an abdominal infection with a proliferating acephalic larval cestode. Small, irregularly shaped parasites were within the substance of a lymph node, where they provoked a fibrogranulomatous and eosinophilic reaction. The parasite is described and is identified as an undifferentiated sparganum or tetrathyridium based upon comparison with two similar parasites from patients in Taiwan and Paraguay.

Key words: proliferating larval cestodiasis; sparganum; tetrathyridium; lymph node; histopathology.

Introduction

To date, nine patients infected with a proliferating larval cestode have been reported. In seven of these the parasites have been identified as *Sparganum proliferum*, first described by Ijima in 1905. One immunosuppressed patient had a disseminated infection with a parasite thought at first to be an atypical *Sparganum proliferum* (Connor et al., 1976), but on further study it was interpreted as an undifferentiated cysticercus or cysticercoid (Lucas et al., 1980; Beaver and Rolon, 1981). The most recent patient with a proliferating larval cestode, identified as a *Sparganum proliferum*, was a Venezuelan man (Mouli-

* The opinions or assertions contained herein are the private views of the authors and are not to be construed as official or as reflecting the views of the Department of the Army or Department of Defense.

nier et al., 1982). Here we describe a tenth infection which, because of its resemblance to a parasite described by Beaver and Rolon (1981), we believe is probably an undifferentiated sparganum or tetrathyridium.

Case Report

In 1977, a 72-year-old male Filipino living in Canada complained of a painful lump in his right groin which had been present for "years" but had never bothered him. He felt well and had no other complaints. He had had a healthy childhood in the Philippines and had served as a soldier from 1929 to 1946. During his military service, he had been interned for six months in a Japanese prisoner-of-war camp and on release was treated for an intestinal "worm". After World War II, he was treated for pulmonary tuberculosis. This treatment continued until he emigrated to Canada in 1977.

Physical examination revealed no abnormalities except for enlarged nodes in the right groin. These extended as a nodular mass into the right lower quadrant as far as the umbilicus. Rectal examination was unremarkable, and the barium enema was normal. His stools contained no parasites. An intravenous pyelogram revealed displacement of the right ureter and the right side of the urinary bladder, although no intrinsic lesions were present. Cystoscopy revealed hypertrophy of the prostate. Hemoglobin was 14.3 g/100 ml. WBC was 7700/mm³ with 10% eosinophilia. The patient's immune status was not considered to be deficient, but it had not been investigated. At surgery there was a firm mass above the inguinal ligament. Several enlarged lymph nodes were present below the ligament, and one of these was removed.

Materials and Methods

The specimen received in the laboratory was fixed in 10% buffered neutral formalin, processed to paraffin, sectioned at 5 μ m and stained by the hematoxylin and eosin, Russell's Movat, and periodic acid-Schiff techniques according to standard methods in use at the Armed Forces Institute of Pathology (AFIP) (Luna, 1968). A portion of the formalin-fixed tissue was cut into cubic millimeter blocks, washed in phosphate buffer and fixed in 1% osmium tetroxide. Following dehydration in an acetone gradient, the tissue was embedded in Epon 812. Sections cut on an ultramicrotome were stained in uranyl acetate and lead citrate prior to examination with an electron microscope. In addition, portions of parasite tegument were lifted from an H&E-stained section and processed for electron microscopy according to the method described by Van Dellen (1978).

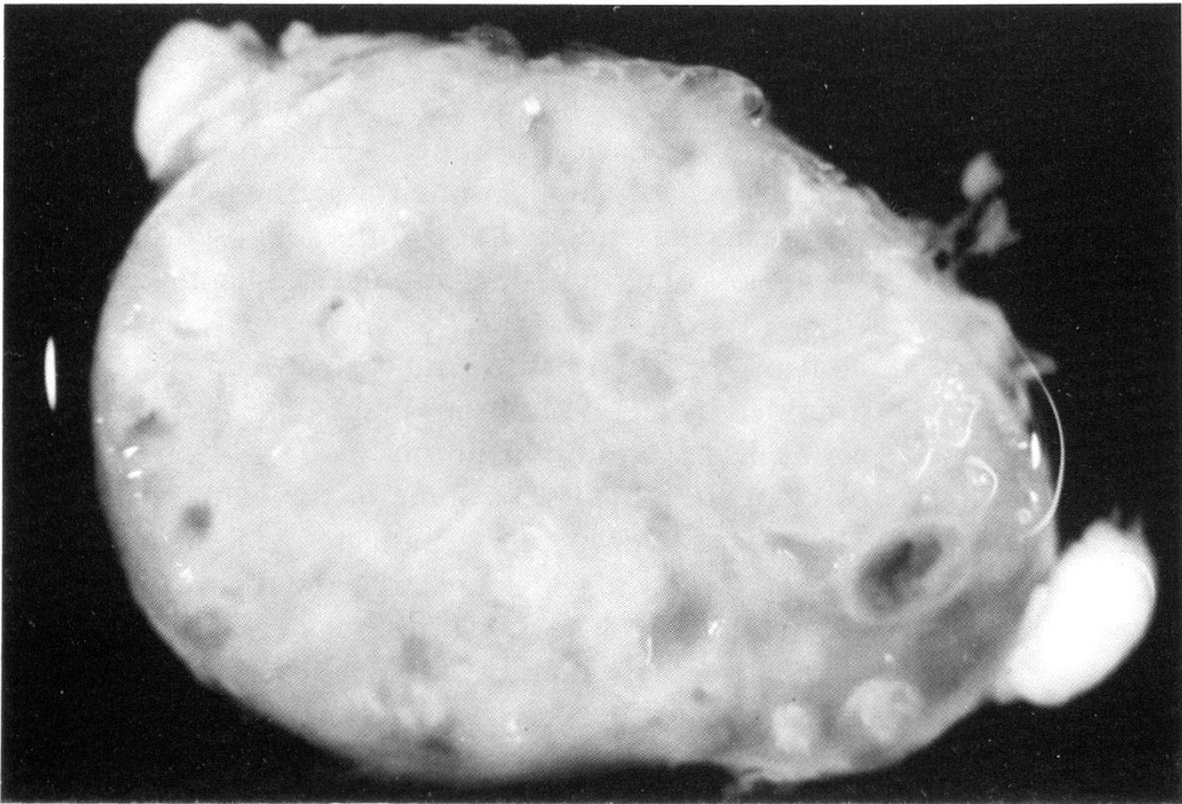
Results

The specimen was firm and rubbery. The cut surface was studded with many small, fluid-filled cysts measuring up to 3 mm across (Fig. 1). Under the dissecting microscope their inner surfaces appeared smooth and glistening.

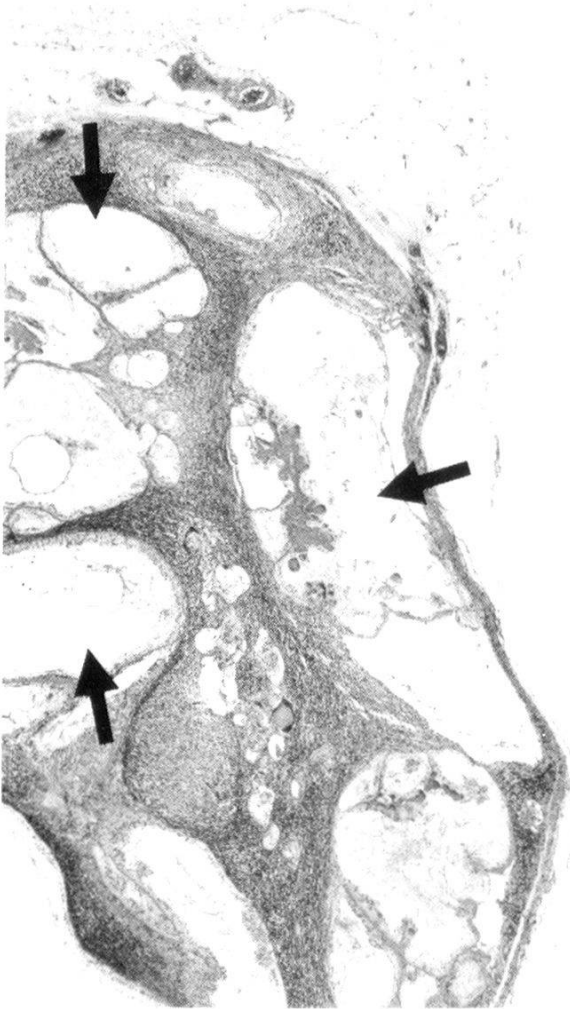Fig. 1. Cut surface of specimen showing multiple cystic parasites throughout the substance of the node, $\times 4.3$ (AFIP Neg. 81-18180).

Fig. 2. The node is enlarged and distorted by many parasites which vary greatly in size and shape. Dilated excretory channels are indicated by arrows. Movat, $\times 25$ (AFIP Neg. 82-11193).

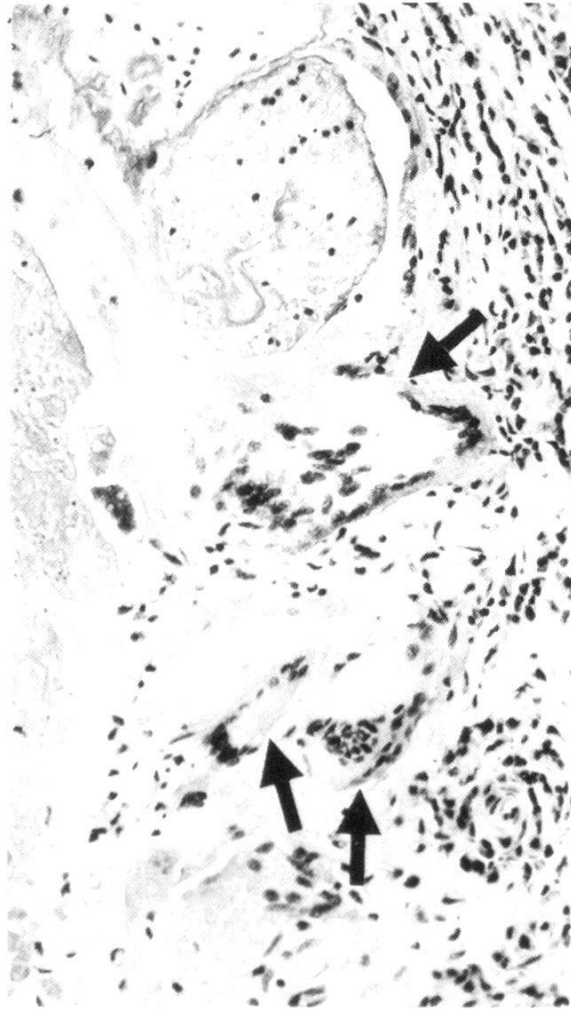
Fig. 3. Giant cells (arrows), both foreign body and Langhans, adjacent to and phagocytosing a degenerating parasite. A smaller degenerating parasite is at the top and is also surrounded in part by giant cells. Movat, $\times 160$ (AFIP Neg. 82-11237).



1



2



3

Microscopically the lymph node is expanded by cystic parasites that occupy more than one-half of the cross sectional areas. The parasites vary in shape. Some are roughly spherical, some are cylindrical or vermiform, and others are convoluted and folded, presenting a variety of patterns (Fig. 2). They vary from 0.06 mm to 3.0 mm in greatest cross-sectional dimension. The majority appear intact and viable, but a few are degenerated and form collapsed amorphous eosinophilic masses, with the loss of most of their stromal and tegumental detail (Fig. 3).

Only a small amount of lymphoid tissue remains between the parasites. Some parasites are surrounded by a cuff of fibrous tissue (Fig. 4). Both foreign body and Langhans' giant cells are within the fibrous tissue along with plasma cells, eosinophils and Russell bodies (Fig. 3). Some of the giant cells are adjacent to the parasite tegument. Degenerating parasites are surrounded by epithelioid cells and histiocytes, some of which are large and foamy (Fig. 4). The tegument of the parasite varies from 1 to 15 μm in thickness. Subtegumental cells are distributed irregularly, sparse beneath thinner segments of the tegument and more regular and crowded beneath thicker segments.

In many areas, deep branching folds and invaginations of the tegument appear as a complex geographic pattern (Fig. 5). The spaces formed between the opposed infolded surfaces contain desquamated, PAS-positive tegumental substance. The internal surface of the infolded segments is lined by irregularly arranged subtegumental cells. Electron microscopic examination of both the formalin-fixed tissue and the portions of tegument lifted from an H&E-stained section reveal a continuous row of microtriches on the external surface. Each microthrix terminates in an electron-dense, curved spinous process (Fig. 6).

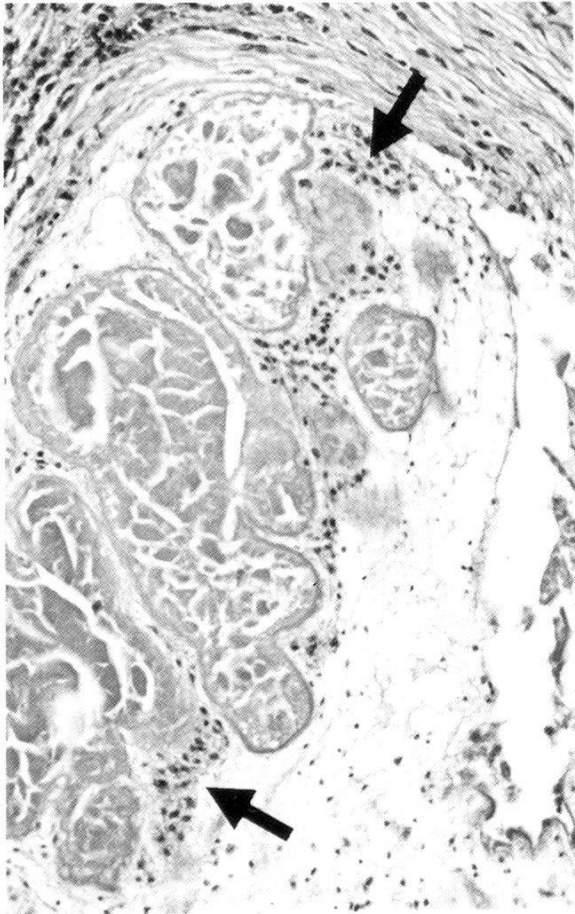
Many parasites contain pockets that are formed by infolded tegument within their stroma. These pockets are irregular in outline and appear singly or in groups (Figs. 5, 7). Each contains tegumental material and is surrounded by closely folded and apparently normal subtegument. Electron microscopic examination of these areas reveals an accumulation of microthrix spines within the central amorphous cuticular material, thus confirming its tegumental origin.

Fig. 4. Portion of parasite surrounded by fibrous tissue containing lymphocytes, plasma cells and eosinophils. The stroma of the parasite contains masses of trapped material produced by infolded tegument. Clusters of subtegumental cells (arrows) form an irregular layer adjacent to the tegumental follicles. H&E, $\times 160$ (AFIP Neg. 81-18251).

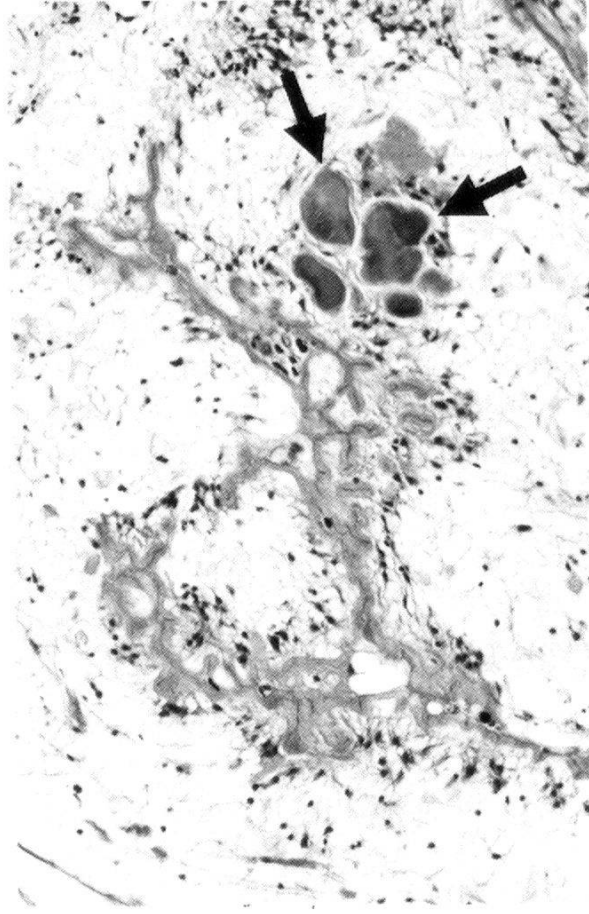
Fig. 5. Interior of a large parasite showing a deeply infolded and tortuous tegument. At the top are islands of trapped eosinophilic tegumental material (arrows). H&E, $\times 160$ (AFIP Neg. 82-11200).

Fig. 6. Electron micrograph of tegumental microtriches, $\times 20,000$ (AFIP Neg. 82-11242).

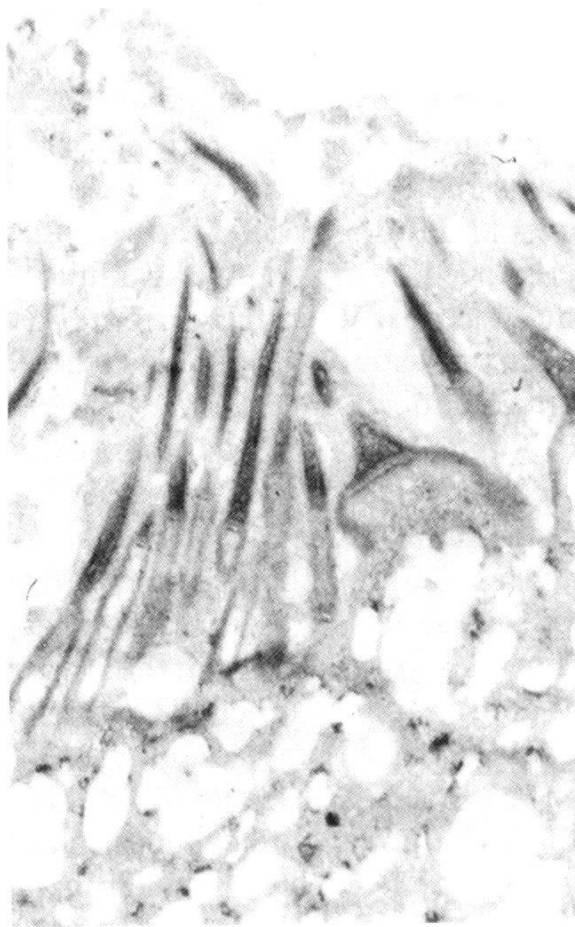
Fig. 7. Thin convoluted tegument forming an irregular infolding. Elaborated tegumental material is trapped and expands the folds even though the infolding is clearly continuous with the surface. The membrane of a dilated excretory channel is indicated by arrows. Movat, $\times 160$ (AFIP Neg. 82-11197).



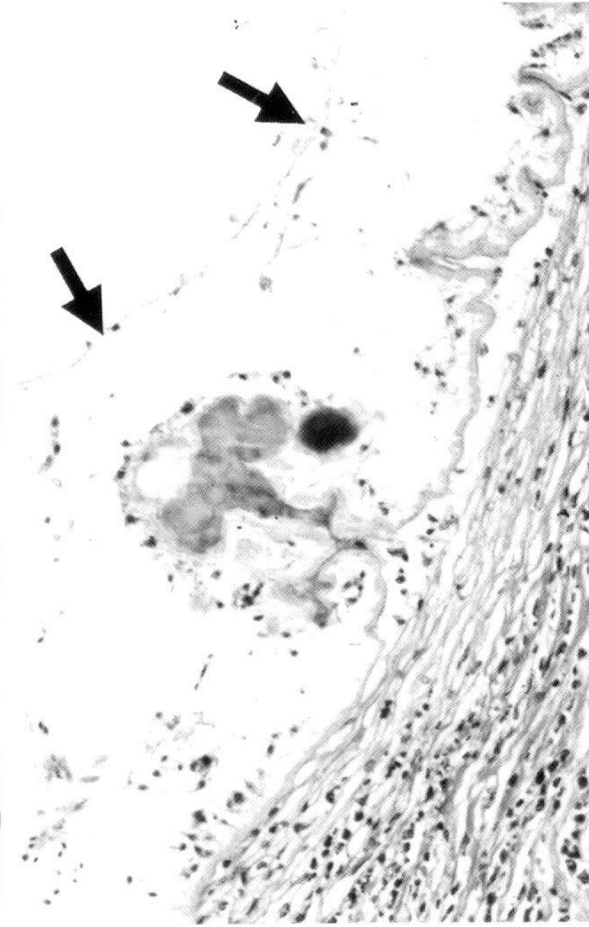
4



5



6



7

These structures are probably invaginations of surface tegument which are connected to the surface in another plane.

The stroma of the parasite is loose and vesicular. Many sections of parasite contain one to several large excretory channels. These channels are generally empty except for a few scattered eosinophilic granules and cellular debris and are limited by a 1 μm -thick, PAS-positive membrane (Fig. 7). In some parasites these channels are so large that the worm's stroma is reduced to a thin rim between the tegument and the limiting membrane (Fig. 2). The stroma contains basophilic nuclei with prominent nucleoli and peripherally arranged nuclear chromatin as well as a small number of ovoid to round, laminated calcareous corpuscles. No smooth muscle, suckers or hooklets are present in any of the parasites.

Discussion

How the patient became infected with this parasite is unknown, but the mass developed before he came to Canada, and it seems clear that he acquired the parasite while living in the Philippines. When last seen by his family physician in November of 1982, he had experienced no new manifestations of this infection and was feeling well. No specific therapy had ever been administered, and the masses above and below the inguinal ligament were still present.

This parasite resembles two other proliferating larval cestodes which have been reported from man. The first, in the lungs of a Taiwanese school teacher, is thought to be either an undifferentiated sparganum or a tetrathyridium because of its embryonic state of stromal development and the absence of muscle bundles within its tissues (Lin et al., 1978; Beaver and Rolon, 1981). The second, in abdominal and mediastinal fibrous tissue removed from a Paraguayan man, is interpreted as an undifferentiated sparganum because it has more differentiated stromal cells and muscle bundles more characteristic of a sparganum than of a tetrathyridium. Both of these parasites were in deep tissues and apparently grew slowly. In the Taiwanese and in our Filipino patient the parasites exhibited limited spread and produced negligible symptoms.

The predominantly globular shape of the parasite we describe here more closely resembles the parasite from the Taiwanese, although it is larger, but the worm in the Paraguayan is longer and more cylindrical. Muscle bands characteristic of a sparganum, present in the Paraguayan worm, are not in the parasite we describe here. All three worms had similar excretory channels. The distribution of tegument and subtegumental cells resembles the Paraguayan worm. The membrane delineating the excretory channels is not a feature of a proliferating taenioid cysticercus or cysticercoid, and the lack of muscle fiber bundles indicates that the parasite is not a *Sparganum proliferum*. We believe, therefore, that this parasite is an undifferentiated sparganum or tetrathyridium.

- Beaver P. C., Rolon F. A.: Proliferating larval cestode in a man in Paraguay: a case report and review. *Amer. J. trop. Med. Hyg.* 30, 625–637 (1981).
- Connor D. H., Sparks A. K., Strano A. J., Neafie R. C., Juvelier B.: Disseminated parasitosis in an immunosuppressed patient. Possibly a mutated sparganum. *Arch. Path. Lab. Med.* 100, 65–68 (1976).
- Ijima I.: On a new cestode larva parasitic in man (*Plerocercoides prolifer*). *J. Coll. Surg. Imperial Univ. Tokyo* 20 (Art. 7), 21 p. (1905).
- Lin T.-P., Su I.-J., Lu S.-C., Yang S.-P.: Pulmonary proliferating sparganosis. A case report. *J. Formosan med. Ass.* 77, 467–472 (1978).
- Lucas S. B., Hassounah O., Muller R., Doenhoff M. J.: Abnormal development of *Hymenolepis nana* larvae in immunosuppressed mice. *J. Helminth.* 54, 75–82 (1980).
- Luna L. G. (ed.): *Manual of histologic staining methods of the Armed Forces Institute of Pathology*, 3rd ed. McGraw-Hill Book Company, New York 1968.
- Moulinier R., Martinez E., Torres J., Noya O., De Noya B. A., Reyes O.: Human proliferative sparganosis in Venezuela: report of a case. *Amer. J. trop. Med. Hyg.* 31, 358–363 (1982).
- Van Dellen A. F.: Tissue section lifting for electron microscopy. In: *Electron microscopy 1978* (proceedings of ninth international congress on electron microscopy, Toronto, Canada, Aug. 1–9, 1978), ed. by J. M. Sturgess, p. 86–89. Microscopical Society of Canada, Toronto 1978.

