

Zeitschrift: Acta Tropica
Herausgeber: Schweizerisches Tropeninstitut (Basel)
Band: 42 (1985)
Heft: 4

Artikel: Differential pathogenicity of "Brugia malayi", "B. patei" and "B. pahangi" in immunodeficient nude mice
Autor: Vickery, A.C. / Nayar, J.K. / Albertine, K.H.
DOI: <https://doi.org/10.5169/seals-313486>

Nutzungsbedingungen

Die ETH-Bibliothek ist die Anbieterin der digitalisierten Zeitschriften auf E-Periodica. Sie besitzt keine Urheberrechte an den Zeitschriften und ist nicht verantwortlich für deren Inhalte. Die Rechte liegen in der Regel bei den Herausgebern beziehungsweise den externen Rechteinhabern. Das Veröffentlichen von Bildern in Print- und Online-Publikationen sowie auf Social Media-Kanälen oder Webseiten ist nur mit vorheriger Genehmigung der Rechteinhaber erlaubt. [Mehr erfahren](#)

Conditions d'utilisation

L'ETH Library est le fournisseur des revues numérisées. Elle ne détient aucun droit d'auteur sur les revues et n'est pas responsable de leur contenu. En règle générale, les droits sont détenus par les éditeurs ou les détenteurs de droits externes. La reproduction d'images dans des publications imprimées ou en ligne ainsi que sur des canaux de médias sociaux ou des sites web n'est autorisée qu'avec l'accord préalable des détenteurs des droits. [En savoir plus](#)

Terms of use

The ETH Library is the provider of the digitised journals. It does not own any copyrights to the journals and is not responsible for their content. The rights usually lie with the publishers or the external rights holders. Publishing images in print and online publications, as well as on social media channels or websites, is only permitted with the prior consent of the rights holders. [Find out more](#)

Download PDF: 15.07.2025

ETH-Bibliothek Zürich, E-Periodica, <https://www.e-periodica.ch>

¹ College of Public Health, University of South Florida, Tampa, FL, USA

² Florida Medical Entomology Laboratory, IFAS-University of Florida, Vero Beach, FL, USA

³ College of Medicine, University of South Florida, Tampa, FL, USA

Differential pathogenicity of *Brugia malayi*, *B. patei* and *B. pahangi* in immunodeficient nude mice

A. C. VICKERY¹, J. K. NAYAR², K. H. ALBERTINE³

Summary

Immunodeficient nude mice chronically parasitized by subperiodic *Brugia malayi* developed an elephantoid appearance with persistent lymphoedema of limbs and massive lymphangiectasis of subcutaneous vessels containing viable adult worms. Removal of worms reversed the process. The syndrome was not caused by *B. patei* or *B. pahangi* and was not correlated with the presence or absence of microfilaremia. Histologic examination of elephantoid mice revealed dilated and tortuous lymphatics containing small nonobstructive lymph thrombi composed of small mononuclear cells and multinucleate giant cells. Draining lymph nodes were not enlarged or congested and mast cells in oedematous tissue were not degranulated. Analysis of lymph aspirated from dilated lymphatics showed increased total protein content; bacterial sepsis was not detected. This work suggests that viable adult *B. malayi* exert direct pathologic effects upon lymphatics and that this parasite is more pathogenic than related *Brugia* spp.

Key words: *Brugia malayi*; *Brugia pahangi*; *Brugia patei*; filaria; nude mouse; lymphatics; histopathology.

Introduction

Of the lymphatic-dwelling filarial worms known to develop normally in the human host, 3 are generally recognized as pathogens: *Wuchereria bancrofti*, *Brugia malayi* (periodic strain) and *B. timori*. Infection with these parasites results in clinical syndromes which have been well described (e.g. Partono et al.,

Correspondence: Ann C. Vickery, Ph. D., University of South Florida, College of Public Health, 13301 N. 30th St., MHC 6-238, Tampa, Florida 33612, USA

1978; Ottesen, 1980; Partono, 1984). Much less is known about symptomatology caused by other zoonotic filarial species, such as *B. pahangi*, and *B. malayi* (subperiodic strain) which can develop in man (Edeson et al., 1960).

Immunologic hypersensitivity responses to antigens released by degenerating adult worms are thought to damage parasitized lymphatics, ultimately resulting in compromised drainage and chronic lymphoedema of affected limbs or genitals. Thus, recurrent episodes of obliterative endolymphangitis rather than simple mechanical obstruction of lymphatics by dead worms are thought to account for filarial lymphoedema and ultimately, for the development of elephantiasis (Ottesen, 1984). However, the lack of an experimental animal model suitable for studies of the immunopathogenesis of filarial lymphatic lesions, has long hampered efforts to establish a cause and effect relationship between hypersensitivity to filarial antigens and clinical manifestations of lymphatic filariasis.

While not discounting the host's responses to the parasite, we agree with earlier suggestions (von Lichtenberg, 1957; Rogers and Denham, 1974) that *living* adult worms and their excretory-secretory products also play an important role in the development of lymphatic lesions and further, suggest that the severity of the lesions differs with the parasite species. We now report that congenitally athymic nude C₃H/HeN mice, chronically parasitized by viable adult subperiodic *B. malayi*, exhibit an elephantoid appearance with massive lymphangiectasis of subcutaneous vessels and progressive lymphoedema of affected limbs in the absence of thymus-dependent immune responses to adult worm antigens (Vickery and Vincent, 1984) and in the absence of sepsis; mice similarly parasitized by *B. patei* or *B. pahangi* do not. Although not elephantiasis in the strictest sense of the word, the syndrome induced in nude mice by subperiodic *B. malayi*, will allow us to differentiate between direct effects of adult worms and their products upon lymphatic tissue and immunopathologic responses to filarial antigens which are lacking in immunodeficient nude mice. Further, the apparent difference in pathogenicity among three related filarial species will hopefully allow us to identify components of the parasite responsible for lymphatic changes.

Materials and Methods

Animals and parasites. Seven- to twelve-week-old nude (nu/nu) C₃H/HeN mice of either sex, maintained in a closed breeding colony under barrier conditions, were used in all experiments. All mice were obtained from sibling matings of nude males and heterozygotic females.

Subperiodic *B. malayi* and *B. pahangi* were maintained in nude mice. Jirds (*Meriones unguiculatus*) were used to maintain *B. patei*. Techniques of mosquito feeding on microfilaremic animals and larval harvest from infected *Aedes aegypti* and/or *Anopheles quadrimaculatus* mosquitoes have been described (Vickery et al., 1983). Infections with *Brugia* spp. were initiated by subcutaneous inoculation of mice with 25, 50, or 75 infective larvae (L₃), suspended in Earles' balanced salt solution containing 100 U/ml penicillin and 100 mg/ml streptomycin into the left groin or 35 L₃ into

the left footpad. Techniques of worm recovery were essentially those used by Ash and Riley (1970). Microfilaremiæ were determined by direct count of microfilariae (mf) in 20 mm³ samples of blood obtained from the retro-orbital plexus of ether-anaesthetized mice. Mice were categorized as amicrofilaremic if microfilariae were never observed in 20 mm³ samples of blood, obtained at approximately monthly intervals, between 60 and 350 days after inoculation with larvae.

Pathology. After inoculation with larvae, mice were examined at weekly intervals for enlarged regional lymph nodes, dilated subcutaneous lymphatics, swollen oedematous limbs and skin changes. Mice which exhibited one or more of these conditions up to 350 days post-inoculation were called elephantoid, and those which did not were called normal. Uninoculated control mice were observed for an equivalent period of time.

For histologic examination, uninoculated control mice and mice in the normal and elephantoid categories were sacrificed by cervical dislocation, then tissue in the region of the left superficial inguinal node was fixed in situ with 2% glutaraldehyde/1% paraformaldehyde in Millonig's phosphate buffer at room temperature. The excised tissue was embedded in glycol methacrylate and 2–3 µm thick sections stained with toluidine blue or hematoxylin and eosin.

Analysis of serum and lymph. Lymph was aspirated from dilated subcutaneous lymphatics of nude mice parasitized by *B. malayi*. Limited amounts of lymph from uninoculated nudes were obtained by thoracic duct cannulation (Lindena and Trautschold, 1983a). Differential leucocyte counts were made on lymph and serum samples, and the presence or absence of mf in the lymph was noted. The *Limulus* amoebocyte lysate (LAL) assay (E-Toxate; Sigma Chemical Co., St. Louis, MO, USA) was performed on serum and lymph according to the manufacturer's instructions for the detection of endotoxin (Sigma Technical Bulletin No. 210, 4–73). Established culture techniques for the detection of aerobic and anaerobic bacteria were performed on randomly selected samples of lymph. A microtitre adaptation of the enzyme-linked immunosorbent assay (ELISA) was used, as described previously (Vickery and Vincent, 1984), to determine serum and lymph titres of IgM and IgG antibodies specific for soluble antigens prepared from adult male and female *B. pahangi* (Vickery et al., 1985). Preliminary work had demonstrated strong cross-reactivity among *B. pahangi*, *B. malayi* and *B. patei* (unpublished observations).

Results

Of 42 male nudes inoculated subcutaneously with 25, 50, or 75 L₃ of *B. malayi* in the groin or 35 L₃ in the footpad, 26 (62%) developed an elephantoid appearance with progressive and ultimately massive lymphangiectasis of subcutaneous lymphatics draining the site of inoculation (Table 1). In males parasitized by *B. malayi*, lymphatics afferent to the superficial inguinal node were most frequently involved although the para-aortic lymphatics and lymphatics afferent to the axillary node were also occasionally affected. Inguinal nodes draining parasitized lymphatics were not enlarged, with a maximum diameter of 4.5 mm, comparable to inguinal nodes from uninoculated mice. Lymphatic dilatations usually became apparent approximately 200 days after inoculation and were dependent upon the presence of viable adult worms in the affected lymphatics, since dilatation of unparasitized lymphatics was not observed and removal of worms by aspiration through an 18 g needle resulted in shrinkage of dilated lymphatics.

Persistent lymphoedema of limbs drained by parasitized lymphatics was observed in approximately 10% of male nudes examined after 200 days post-

Table 1. Development of filarial elephantoid syndrome in microfilaremic and amicrofilaremic nude mice during chronic infection with *Brugia* spp.

Mice*				Microfilaremic**				Amicrofilaremic**			
				Elephantoid		Normal		Elephantoid		Normal	
N	Sex	N	Route	N	(%)	N	(%)	N	(%)	N	(%)
<i>B. malayi</i> L ₃											
7	M	25	S.C.	1	(14.3)	4	(57.1)	1	(14.3)	1	(14.3)
25	M	50	S.C.	14	(56.0)	4	(16.0)	3	(12.0)	4	(16.0)
6	M	75	S.C.	4	(66.7)	1	(16.7)	1	(16.7)	0	
4	M	35	F.P.	1	(25.0)	1	(25.0)	1	(25.0)	1	(25.0)
16	F	50	S.C.	0		4	(25.0)	0		12	(75.0)
3	F	35	F.P.	1	(33.3)	0		0		2	(66.7)
<i>B. pahangi</i> L ₃											
36	M	50	S.C.	0		35	(97.2)	0		1	(2.8)
25	F	50	S.C.	0		24	(96.0)	0		1	(4.0)
<i>B. patei</i> L ₃											
25	M	50	S.C.	0		4	(16.0)	0		21	(84.0)

* Male (M) or female (F) nude mice were inoculated subcutaneously in the left groin (S.C.) or in the left footpad (F.P.) with various numbers of infective larvae (L₃) of *B. malayi*, *B. pahangi*, or *B. patei*.

** Mice were designated microfilaremic or amicrofilaremic according to the criteria described in Materials and Methods.

inoculation with *B. malayi* (Fig. 1). The skin of most mice showing either lymphoedema or lymphangiectasis retained a normal appearance and stretched to accommodate the increased volume of dilated lymphatics and oedematous tissue. However, fissures developed in rigid and thickened skin. A minority (2%) of parasitized nudes developed ulcers superficial to the affected inguinal node, which healed by cicatrization. Spontaneous lymphangiohemorrhage occasionally appeared in mice with the largest lymphatics.

Of 19 female nude mice inoculated subcutaneously with 50 L₃ of *B. malayi* or with 35 L₃ in the footpad, only 5 (26%) became microfilaremic (Table 1). Seven of ten amicrofilaremic females necropsied 218 to 254 days post-inoculation for determination of worm burdens, harbored 1 to 4 worms although the majority of infections were with a single sex, usually female, and worms were frequently located in the right heart and pulmonary artery. Significantly, only 1 of the 19 (5.3%) females harbored lymphatic-dwelling adult worms and exhibited apparent lymphangiectasis. Thus, differential sex susceptibility to *B. malayi* biased in favor of male mice, is associated with the development of lymphatic lesions, further suggesting that nudes must harbor lymphatic-dwelling adult

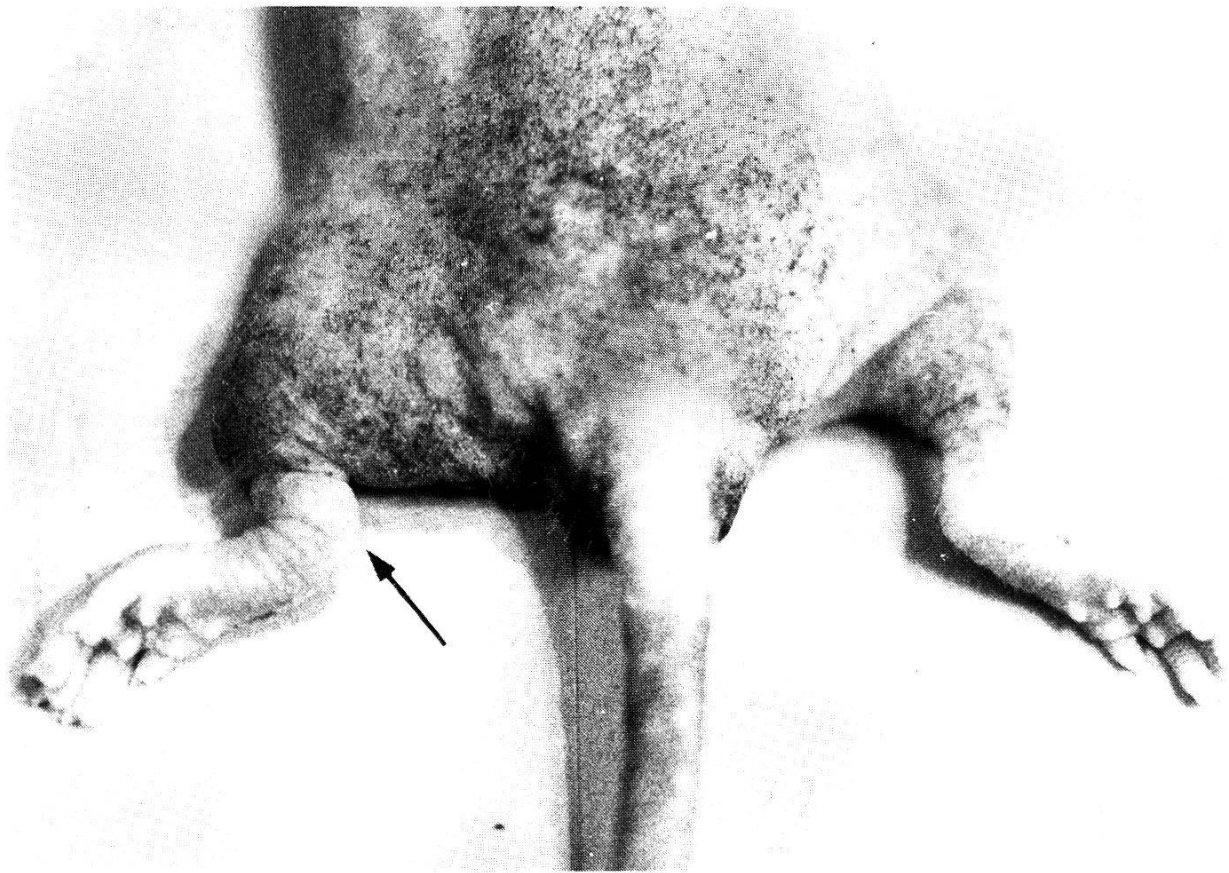


Fig. 1. Lymphoedema of the left hind limb (→) of a male nude mouse, 303 days after subcutaneous inoculation with 50 L_3 of *B. malayi*.

worms to exhibit elephantiasis-like symptomatology. An elephantoid appearance was not observed in any of 25 female and 36 male nudes after subcutaneous inoculation with 50 L_3 of *B. pahangi* although 96% of females and 97.2% of males became microfilaremic and all harbored lymphatic-dwelling adult worms. At necropsy, dissection of parasitized animals revealed small lymphatic dilatations around adult worms which had failed to progress to the massive varicosities observed in nudes parasitized by *B. malayi*. Nor was secondary tissue or skin involvement seen in mice parasitized by *B. pahangi*. This suggests a significant difference in pathogenicity between two closely related species of *Brugia* in an immuno-incompetent host.

Although filarial symptomatology was not observed in 25 male nudes following subcutaneous inoculation with 50 L_3 of *B. patei*, only 16% became microfilaremic; nude mice appear to be less susceptible to infection with *B. patei* than with *B. malayi* or *B. pahangi*. However, necropsy of the 4 patent and 21 nonpatent mice revealed only small lymphatic dilatations around adult worms indicating that the relative pathogenicity of *B. patei* more closely resembles that of *B. pahangi* than *B. malayi*. Further, the beaded appearance of the parasitized lymphatics is indicative of intact valvular function.

Preliminary histologic examination of parasitized lymphatics obtained from male nude mice, 220 to 260 days after subcutaneous inoculation with 50 L₃ of *B. malayi*, showed that lymphatic blockage is not involved in lymphangiectasis. Small non-obstructive lymph thrombi which appeared to be composed primarily of small mononuclear cells and large multinucleate giant cells were found free in the lumen or adhering to the endothelium which had a swollen and scalloped appearance (Fig. 2). In apparent contrast to suggestions that filarial lymphoedema may be primarily due to degranulation of IgE sensitized mast cells by adult worm antigens (Dumont et al., 1983), we found that interstitial mast cells in parasitized nude mice were not degranulated even when present in oedematous tissue adjacent to lymphatics harboring adult worms (Fig. 3). Little or no parietal or interstitial cellular infiltrate could be demonstrated although intraluminal and interstitial fibrin deposition was present and draining lymph nodes were not congested. Differential peripheral blood leukocyte counts were not different from uninoculated nude mice.

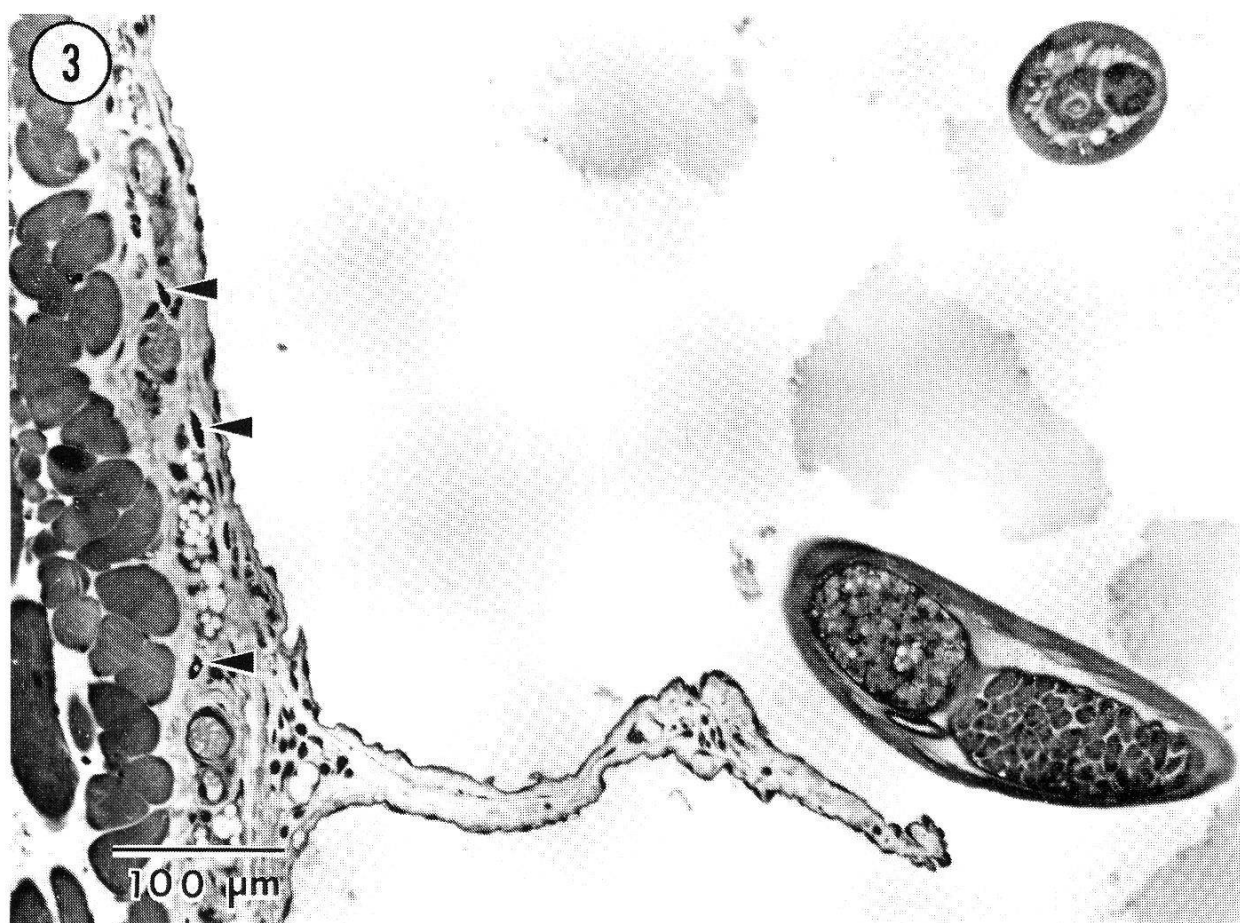Dilated subcutaneous lymphatics of male nudes harboring adult *B. malayi* became increasingly tortuous with time (Fig. 3), leading to the formation of massive varicosities (Fig. 4) from which relatively large volumes of parasitized lymph could be extracted; 1 to 3 ml per day from a single mouse was not unusual. Unexpectedly, puncture of distended lymphatics resulted in a slow oozing rather than a high pressure flow of lymph through the wound. The total protein content of parasitized lymph, determined by the method of Lowry et al. (1951), was more than double published values for normal mouse lymph (Lindena and Trautschold, 1983b). Protein contents ranging from 41.3 mg/ml to 69.3 mg/ml of lymph, together with the low opening pressure of these dilated lymphatics, would place this phenomenon in the "high-protein-concentration low-flow" category (Foldi and Casley-Smith, 1978).

Lymph obtained from parasitized nudes contained no detectable IgG and rarely contained IgM antibodies (titre never > 10) to parasite antigens (ELISA), was free of endotoxin as indicated by negative *Limulus* amoebocyte lysate analyses, and contained no bacteria demonstrable by routine culture techniques. Small mononuclear cells constituted the major intraluminal cell population (63%) with few neutrophils (19%) and fewer eosinophils (2%), again, indicative of the lack of a septic process which, in other models, appears to be necessary to produce progressive lymphatic dilatation (Folse et al., 1981).

Although the majority of male nudes which developed an elephantoid appearance following inoculation with varying numbers of *B. malayi* L₃ were microfilaremic, no absolute correlation between the presence or absence of

Fig. 2. Dilated and tortuous lymphatic containing lymph thrombi (►) of a male nude, 209 days after subcutaneous inoculation with 50 L₃ of *B. malayi*. Endothelium has a scalloped appearance (H&E).

Fig. 3. Intact interstitial mast cells (→) in oedematous tissue in close proximity to a dilated lymphatic containing adult *B. malayi* (Toluidine blue).

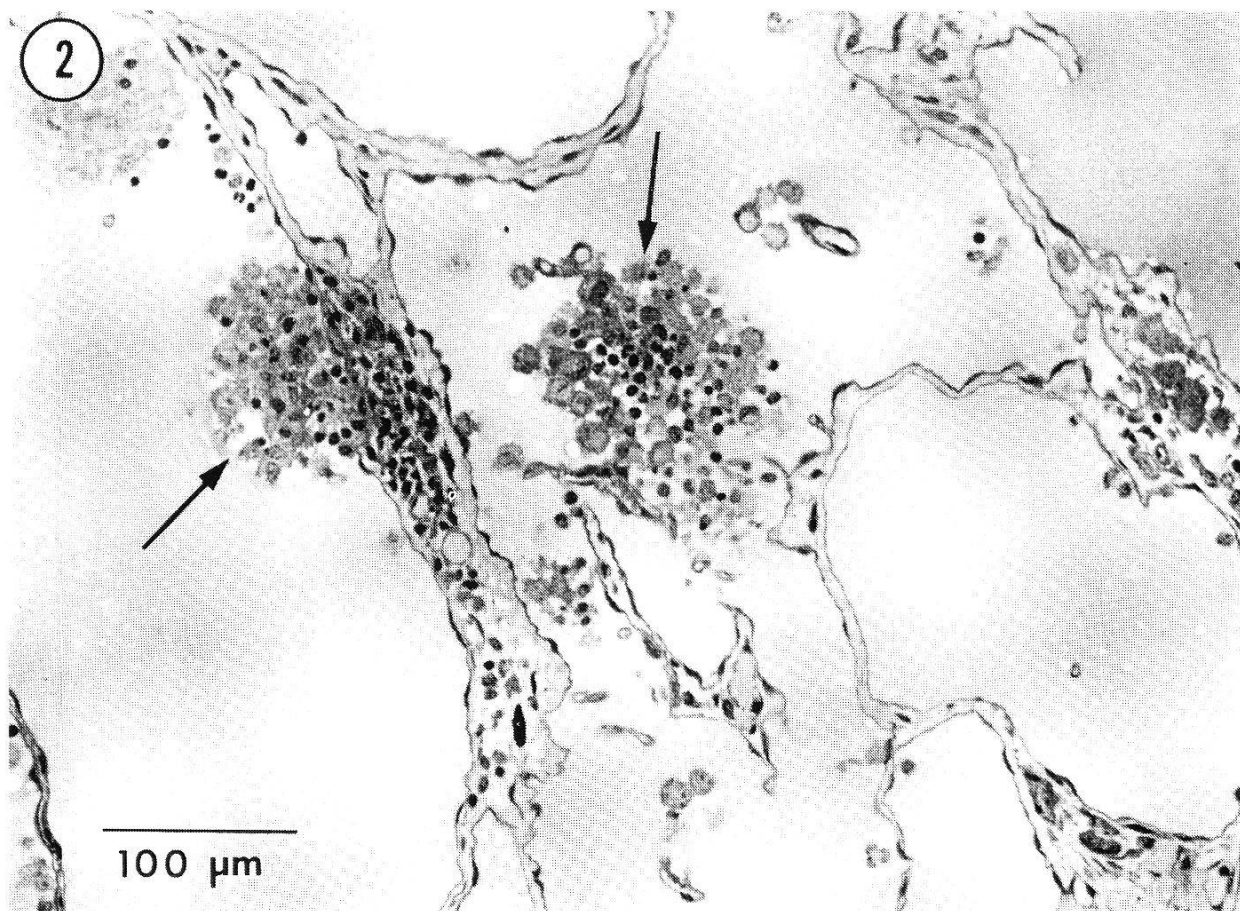

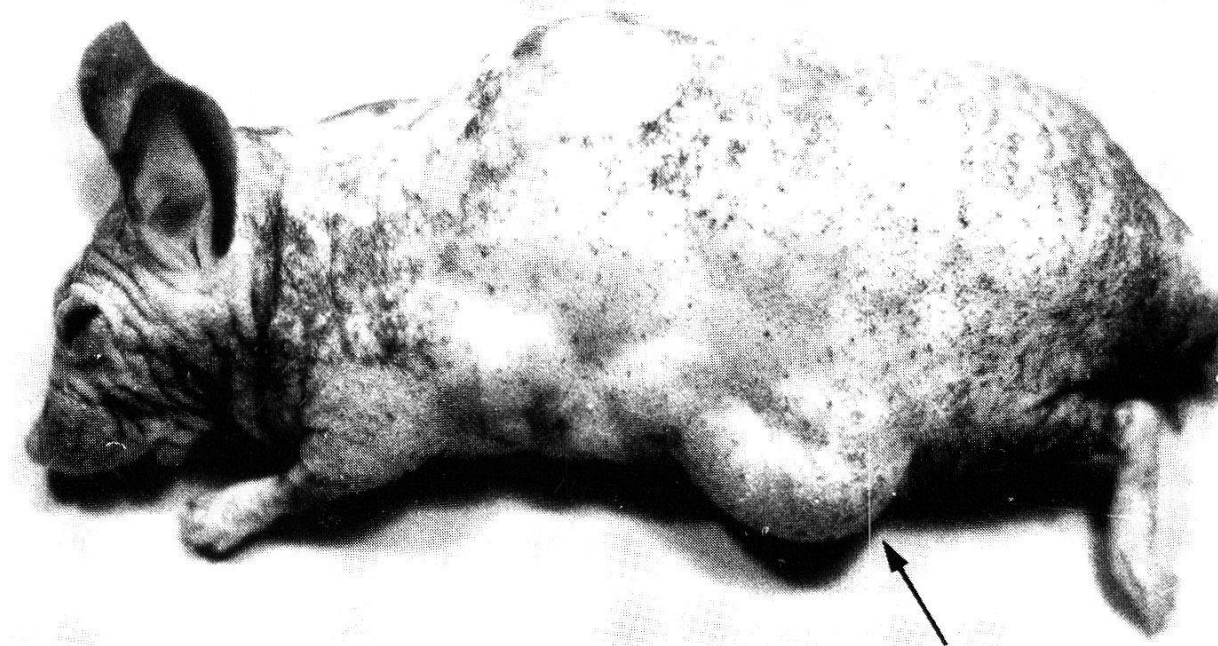


Fig. 4. Large varicosities (→) of a subcutaneous lymphatic harboring adult *B. malayi* from which lymph could repeatedly be aspirated, 274 days after subcutaneous inoculation with 50 L₃.

circulating microfilariae and the syndrome was noted. As shown in Table 1, an overall 40.7% of microfilaremic and 17.1% of amicrofilaremic male mice exhibited filarial symptomatology. Conversely, 24% of microfilaremic and of 14.6% of amicrofilaremic males remained normal. Therefore, we agree with Rogers and Denham (1974), that living adult worms and not microfilariae appear to be the pathogenic stage.

Discussion

This study confirms and extends the results of earlier work with *B. pahangi* in the nude mouse (Vincent et al., 1984) by showing that certain lymphatic lesions are caused directly or indirectly by living adult worms and that thymus-dependent immune responses to worm antigens are not involved in lesion development. Further, we have shown that *B. malayi* is significantly more pathogenic in mice than *B. pahangi* or *B. patei*. Of the 3 species only *B. malayi* is responsible for inducing an elephantoid appearance involving a massive lymphangiectasis and tortuosity of parasitized lymphatics, with fibrin deposition associated with high-protein low-flow oedema; some animals showed intersti-

tial oedema in the subcutis with swollen oedematous limbs and thickening of skin with loss of elasticity and development of ulcers and fissures.

The presence of viable adult *B. malayi* appears to be necessary for the occurrence of progressive dilation of lymphatics of nude mice, a process which can be stopped and reversed by the removal of the worms; microfilariae do not appear to be involved. This phenomenon is probably analogous to early stages of the pathologic process in human filariasis, when clinical features of infection can be reversed by chemotherapy. The mechanism of lymphatic dilatation, however, remains unknown. Lymphography in human filariasis has shown that there can be extensive dilatation of lymphatics in the absence of obliteration or blockage (Cohen et al., 1961). This appears to be the case in nude mice in which no mechanical blockage is apparent.

Dean et al. (1983) showed that immunosuppression retarded the development of lymphatic dilatation in cats parasitized by *B. pahangi* leading the authors to suggest that T cells are involved. This is not true, however, in nude mice which lack functional thymus-dependent immune responses (Vickery et al., 1983; Wortis, 1974). Nor does concomitant bacterial infection, shown to potentiate lymphatic dilatation in cats (Folse et al., 1981), appear to be involved in our model.

Although we cannot rule out mechanical irritation of the lymphatic endothelium by the vigorously thrashing worms as the proximal cause of dilatation, the high total protein content of lymph aspirated from dilated lymphatics suggests an osmotic phenomenon, which might also be operative in the development of tissue lymphoedema. In rat subcutaneous tissue, excess plasma proteins in the absence of lymphatic obstruction is sufficient to produce lymphoedema (Casley-Smith and Gaffney, 1980). Lymphatics in these animals were dilated with high protein contents in their lumens. Similar phenomena have been reported in dogs with chronic experimental lymphoedema (Casley-Smith et al., 1980).

The cause of elevated protein content of lymph from *B. malayi* infected nude mice is unknown. Degranulation of interstitial mast cells with resulting increased capillary permeability and increased rate of lymph production, as suggested by others (Dumont et al., 1983), is unlikely in nude mice which lack the ability to produce parasite antigen specific IgE (Vickery and Vincent, 1984). Also, in the present study, we found no evidence of mast cell degranulation even when the cells were present in oedematous tissue.

That the high protein content of lymph obtained from *B. malayi* infected nude mice might be due, at least in part to worm metabolic products, is suggested by our preliminary finding that normal heterozygous mice, syngeneic with the nude lymph donors, produce antibodies in response to immunization with parasitized lymph but not with lymph or serum from unparasitized nude mice.

The picture is complicated, however, by the significant difference in degree of lymphatic dilatation caused by *B. malayi* compared to *B. patei* and *B. pahan-*

gi, which suggests that *B. malayi* may either produce a unique mediator(s) capable of directly causing lymphangiectasis with or without lymphoedema or may secrete or excrete enzymes which break down host tissue. Work by Dresden and Ewert (1984), which showed increased collagen metabolism in tissue from *B. malayi* infected cats, tends to support the latter view. That *B. malayi* is simply more active metabolically than the other two parasites is unlikely. While such mediators or enzymes remain to be defined, lymphatics containing *B. pahangi* or *B. patei* remain beaded, indicating that valvular function is intact; lymphoedema does not develop in these mice. In contrast, we believe that the development of massive varicosities of lymphatics in nudes parasitized by *B. malayi*, is suggestive of valvular incompetence.

Massive lymphangiectasis, comparable to that seen in *B. malayi* infected nude mice, has not been reported in cats or jirds inoculated with *B. malayi* or *B. pahangi* (Ewert et al., 1972; Klei et al., 1982; Rogers and Denham, 1974). We suggest that differential pathogenicity of these parasites in immunocompetent hosts is masked by immune responses to parasite products, which leads to a self-limited and relatively stable relationship between the worm and lymphatic tissue. Thus, while we do not discount the importance of immunological hypersensitivity in the development of chronic obstructive disease in normal hosts, a severely immunodeficient host may be the best vehicle for studying the parasite's role in the development of filarial lymphatic pathology.

Acknowledgments

We thank Susan Deem and Theresa Cherry for technical assistance. This work was supported in part by the USPHS through NIH NIAID Grant AI 20052 and by a grant from the University of South Florida Research and Creative Scholarship Fund.

- Ash L. R., Riley J. M.: Development of *Brugia pahangi* in the jird, *Meriones unguiculatus*, with notes on infections in other rodents. *J. Parasit.* 56, 962–968 (1970).
- Casley-Smith J. R., Gaffney R. M.: Excess plasma protein as a cause of chronic inflammation and lymphoedema. I. Quantitative electron microscopy. *J. Path.* 133, 243–272 (1980).
- Casley-Smith J. R., Clodius L., Piller N. B.: Tissue changes in chronic experimental lymphoedema in dogs. *Lymphology* 13, 130–141 (1980).
- Cohen L. B., Nelson G., Wood A. M., Manson-Bahr P. E. C., Bowen R.: Lymphangiography in filarial lymphoedema and elephantiasis. *Amer. J. trop. Med. Hyg.* 10, 843–848 (1961).
- Dean G. S., Playfair J. H. L., Denham D. A., Noscoe N.: Effect of immunosuppressive or inflammatory agents on lymphatic dilatation in cats infected with *Brugia pahangi*. *Parasite Immunol.* 5, 113–122 (1983).
- Dresden M. H., Ewert A.: Collagen metabolism in experimental filariasis. *J. Parasit.* 70, 208–212 (1984).
- Dumont A. E., Fazzini E., Jamal S.: Metachromatic cells in filarial lymphoedema. *Lancet* 1983/II, 1021.
- Edeson J. F. B., Wilson T., Wharton R. H., Laing A. B. G.: Experimental transmission of *Brugia malayi* and *B. pahangi* to man. *Trans. roy. Soc. trop. Med. Hyg.* 54, 229–234 (1960).
- Ewert A., Balderach R., Elbihari S.: Lymphographic changes in regional lymphatics of cats infected with *Brugia malayi*. *Amer. J. trop. Med. Hyg.* 21, 407–414 (1972).

- Foldi M., Casley-Smith J. R.: The roles of the lymphatics and the cells in high protein oedemas. *Mol. Aspects Med.* 2, 77–146 (1978).
- Folse D., Ewert A., Reitmeyer J. C.: Light and electron microscopic studies of lymph vessels from cats infected with *Brugia malayi*. *Southeast Asian J. trop. Med. publ. Hlth* 12, 174–184 (1981).
- Klei T. R., Enright F. M., Blanchard D. P., Uhl S. A.: Effects of presensitization on the development of lymphatic lesions in *Brugia pahangi* infected jirds. *Amer. J. trop. Med. Hyg.* 31, 280–291 (1982).
- von Lichtenberg F.: The early phase of endemic bancroftian filariasis in the male. *Pathological study*. *J. Mt. Sinai Hosp.* 24, 983–1000 (1957).
- Lindena J., Trautschold I.: Ductus thoracicus lymph in mice. 1. A technique for cervical approach. *Lymphology* 16, 243–246 (1983a).
- Lindena J., Trautschold I.: Ductus thoracicus lymph in mice. 2. Enzyme activities and protein content. *Lymphology* 16, 247–249 (1983b).
- Lowry O. H., Rosebrough N. J., Farr A. L., Randall R. J.: Protein measurement with the Folin phenol reagent. *J. biol. Chem.* 193, 265–275 (1951).
- Ottesen E. A.: Immunopathology of lymphatic filariasis in man. *Springer Semin. Immunopath.* 2, 373–385 (1980).
- Ottesen E. A.: Immunological aspects of lymphatic filariasis and onchocerciasis in man. *Trans. roy. Soc. trop. Med. Hyg.* 78, (Suppl.), 9–18 (1984).
- Partono F.: Filariasis in Indonesia: clinical manifestations and basic concepts of treatment and control. *Trans. roy. Soc. trop. Med. Hyg.* 78, 9–12 (1984).
- Partono F., Purnomo, Pribadi W., Soewarta A.: Epidemiological and clinical features of *Brugia timori* in a newly established village, Karakuak, West Flores, Indonesia. *Amer. J. trop. Med. Hyg.* 27, 910–915 (1978).
- Rogers R., Denham D. A.: Studies with *Brugia pahangi*. 7. Changes in lymphatics of injected cats. *J. Helminth.* 48, 213–219 (1974).
- Vickery A. C., Vincent A. L.: Immunity to *Brugia pahangi* in athymic nude and normal mice: eosinophilia, antibody and hypersensitivity responses. *Parasite Immunol.* 6, 545–559 (1984).
- Vickery A. C., Vincent A. L., Sodeman W. A. jr.: Effect of immune reconstitution on resistance to *Brugia pahangi* in congenitally athymic nude mice. *J. Parasit.* 69, 478–485 (1983).
- Vickery A. C., Nayar J. K., Tamplin M. L.: Diethylcarbamazine mediated clearance of *Brugia pahangi* microfilariae in immunodeficient nude mice. *Amer. J. trop. Med. Hyg.* 34, 476–483 (1985).
- Vincent A. L., Vickery A. C., Lotz M., Desai U.: The lymphatic pathology of *Brugia pahangi* in nude (athymic) and thymic mice, C₃H/HeN. *J. Parasit.* 70, 48–56 (1984).
- Wortis H. H.: Immunological studies of nude mice. *Contemp. Top. Immunobiol.* 3, 243–263 (1974).

