

# Treatment of deep vein thrombosis : a comparative study of heparin, streptokinase and Arvin

Autor(en): **Kakkar, V.V.**

Objekttyp: **Article**

Zeitschrift: **Bulletin der Schweizerischen Akademie der Medizinischen Wissenschaften = Bulletin de l'Académie Suisse des Sciences Medicales = Bollettino dell' Accademia Svizzera delle Scienze Mediche**

Band (Jahr): **29 (1973)**

PDF erstellt am: **28.05.2024**

Persistenter Link: <https://doi.org/10.5169/seals-307957>

## **Nutzungsbedingungen**

Die ETH-Bibliothek ist Anbieterin der digitalisierten Zeitschriften. Sie besitzt keine Urheberrechte an den Inhalten der Zeitschriften. Die Rechte liegen in der Regel bei den Herausgebern.

Die auf der Plattform e-periodica veröffentlichten Dokumente stehen für nicht-kommerzielle Zwecke in Lehre und Forschung sowie für die private Nutzung frei zur Verfügung. Einzelne Dateien oder Ausdrucke aus diesem Angebot können zusammen mit diesen Nutzungsbedingungen und den korrekten Herkunftsbezeichnungen weitergegeben werden.

Das Veröffentlichen von Bildern in Print- und Online-Publikationen ist nur mit vorheriger Genehmigung der Rechteinhaber erlaubt. Die systematische Speicherung von Teilen des elektronischen Angebots auf anderen Servern bedarf ebenfalls des schriftlichen Einverständnisses der Rechteinhaber.

## **Haftungsausschluss**

Alle Angaben erfolgen ohne Gewähr für Vollständigkeit oder Richtigkeit. Es wird keine Haftung übernommen für Schäden durch die Verwendung von Informationen aus diesem Online-Angebot oder durch das Fehlen von Informationen. Dies gilt auch für Inhalte Dritter, die über dieses Angebot zugänglich sind.

## **Treatment of deep vein thrombosis**

### **A comparative study of heparin, streptokinase and Arvin**

V. V. KAKKAR

Deep vein thrombosis is an important cause of disability and death. The patient may die from pulmonary embolism or may develop the post-phlebitic syndrome, which represents one of the common and intractable problems in surgery. When thrombosed veins recanalise, their valves are destroyed and become incompetent, causing sustained high pressure [2, 17] which is thought to be responsible for many of the features of the post-phlebitic syndrome such as pain, swelling, eczema, pigmentation and ulceration of the legs.

If the mortality due to pulmonary embolism and the misery due to the post-phlebitic syndrome are to be significantly reduced, there are at least two basic requirements: deep vein thrombosis must be diagnosed at an early stage in all patients who develop it, and there must be rapid and complete dissolution of the thrombus at the earliest possible moment, with preservation of valvular function.

Within the last few years, a number of tests have been developed which can be used to detect the presence of *in vivo* thrombosis at an early stage, or changes in the blood that may reflect an excessive tendency to clot formation. These include the  $^{125}\text{I}$ -labelled fibrinogen test [1, 6, 10, 11, 18], the ultrasound technique [5, 22], impedance phlebography [23], and certain haematological tests [19].

Three different types of drugs are now available for treating patients with established deep vein thrombosis: the conventional anticoagulants – the heparin and coumarin group of drugs; thrombolytic agents – streptokinase and urokinase, and a defibrinating substance – Ancrod, a purified fraction of the venom of the Malayan pit viper, which has a specific coagulant action on fibrinogen [3]. There is still much argument as to which is the best therapy for patients with venous thrombosis. This is largely due to the lack of well controlled studies involving accurate measurement of the effectiveness of different treatments. With a few exceptions, the majority of studies have relied on clinical signs for evaluating treatment; these have been shown to be misleading – clinical clearance is often complete despite persisting thrombi within the veins [12].

Table 1  
Treatment schedules used

	Loading dose	Maintenance dose
Heparin	10 000 U in 5 min	10 000–15 000 U every 6 h
Streptokinase	500 000 U in 30 min	900 000 U every 6 h
Ancrod	80 U in 6 h 80 U in 15 min	40–80 U every 6 h

The purpose of this paper is to report the results of a controlled clinical trial in patients with extensive deep vein thrombosis who were allocated at random to treatment with heparin, streptokinase or Ancrod, under strict laboratory control. Two objective methods, as well as careful clinical observation, were used to study the fate of thrombi.

#### *Controlled clinical trial*

*Selection of patients:* Patients were considered for inclusion in this trial if they had signs and symptoms of deep vein thrombosis which had first appeared in the legs within the preceding four days. Because of the risk of bleeding, patients with active peptic ulcer disease, those with diastolic pressures greater than 100 mm Hg or known to have cerebro-vascular pathology, and those who had been operated on within the preceding three days, were excluded. All patients were examined by ascending venography and only when this confirmed the presence of thrombi in the deep veins of the legs was the patient considered suitable for treatment.

*Design of the trial:* 30 envelopes were prepared, each containing one of three possible treatment schedules, in random order. As each patient was admitted to the trial, his treatment was selected by opening the next envelope. This gave three groups of 10 patients which were found to be similar in many respects. All patients were confined to bed for the duration of the trial. The foot of the bed was raised, they were encouraged to move their legs as much as possible in bed, and all wore thick elastic bandages which were re-applied frequently.

The treatment schedules used are shown in Table 1. The selected drug was dissolved in 0.9% saline and given by continuous intravenous infusion, which was uninterrupted for five days unless phlebograms showed complete clearance of thrombi before that time, or unless complications arose. At the end of the infusion, oral anticoagulants were given to all patients.

#### *Assessment of progress*

*Clinical:* Patients were examined daily and particular attention paid to the extent of tenderness, the measured circumference of the limb at various levels, their temperature and the appearance of any new symptoms.

*Radiographic:* In this study, venograms were performed at about 48–72 hourly intervals during treatment and a final venogram was performed at the end of therapy for assessment of the results. The technique of ascending venography used has been described in detail elsewhere [15].

*Isotopic:* 21 patients showed definite evidence of a localised increase in radioactivity at the site of the thrombus before treatment. In these patients, the thyroid gland was first blocked by sodium iodide (100 mg) given intravenously  $\frac{1}{2}$  h prior to the injection of  $^{125}\text{I}$ -labelled fibrinogen (100  $\mu\text{Ci}$ ). Radioactive counting was performed along the leg

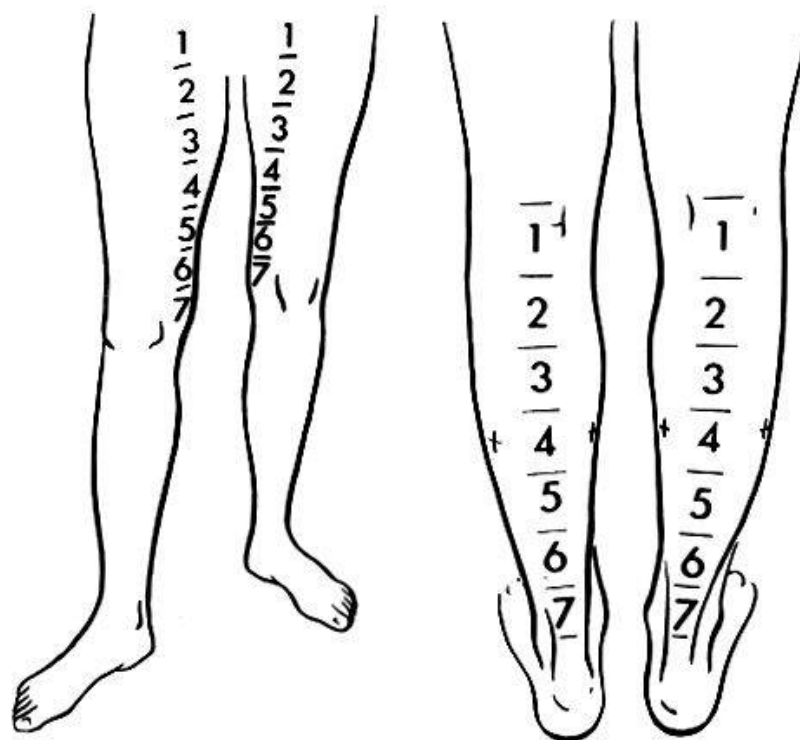


Fig. 1. The positions at which radioactivity is recorded.

after one hour and again after 6–12 h, and then daily during treatment. The counting equipment used consisted of a portable scintillation counter, a high-voltage unit, pulse amplifier, pulse-height analyser and a scaler. Three 10-second readings were taken at each position (Fig. 1) and the average of these was adjusted for background radiation, isotope decay and daily variation in the apparatus. Repeated counts of radioactivity over the site of the thrombus and over areas where there was no thrombus allowed a quantitative assessment of the fate of the thrombi. The original difference between the radioactivity at the site of the thrombus and that at an adjacent site was taken as 100 per cent. The percentage decline of this difference (thrombus radioactivity) was assumed to represent the degree of dissolution of thrombus and this was confirmed by phlebography (Fig. 2).

## Results

### A. Early results

*Clinical:* Of the 30 patients studied, 1 died from a massive pulmonary embolus which occurred 36 h after starting heparin therapy and, in another patient, extensive haemorrhage from the site of subclavian venopuncture prevented an adequate course of streptokinase infusion. These patients were excluded from further consideration. The remaining 28 patients all completed at least 5 days of treatment. The majority showed rapid clinical improvement but radiographic findings in these patients emphasise the inadequacy of clinical assessment (Table 2).

*Venographic:* Table 3 shows the venographic findings. There was complete dissolution of all visible thrombi (Fig. 3) in more than 50% of the patients treated with streptokinase. In the majority of patients receiving heparin or Ancrod, the original thrombi remained unchanged.

## THROMBUS DISSOLUTION

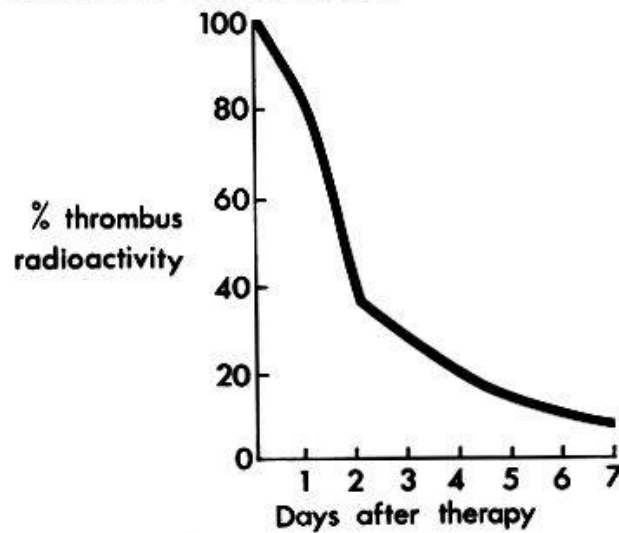


Fig. 2. The rate of thrombus dissolution, as judged by the  $^{125}\text{I}$  fibrinogen test. On the second day after streptokinase therapy the thrombus radioactivity has fallen to approximately 38% of the original and, at the end of seven days, it is less than 10%, indicating that approximately 90% of the thrombus has been dissolved during this period.

Table 2  
Correlation of venographic and clinical findings

	Venographically	
	Thrombus persisted	Thrombus cleared
Signs of deep vein thrombosis persisted	5	0
Signs of deep vein thrombosis disappeared	15	8

Table 3  
Early results of treatment of deep vein thrombosis with different drugs

Treatment	Patients	Complete lysis of thrombi	Partial lysis of thrombi	No improvement
Heparin	9	2	4	3
Streptokinase	9	6	1	2
Ancrod	10	1	3	6
<b>Total</b>	<b>28</b>	<b>9</b>	<b>8</b>	<b>11</b>

*Isotopic:* In 21 patients it was possible to assess the rate of thrombus dissolution by using the  $^{125}\text{I}$ -labelled fibrinogen test. Of the 6 patients treated with heparin, the decline of radioactivity over the site of thrombi showed a rapid fall in 2, with complete clearance, judged by venography; an intermediate fall in 1, and a slow reduction sometimes preceded by a rise,



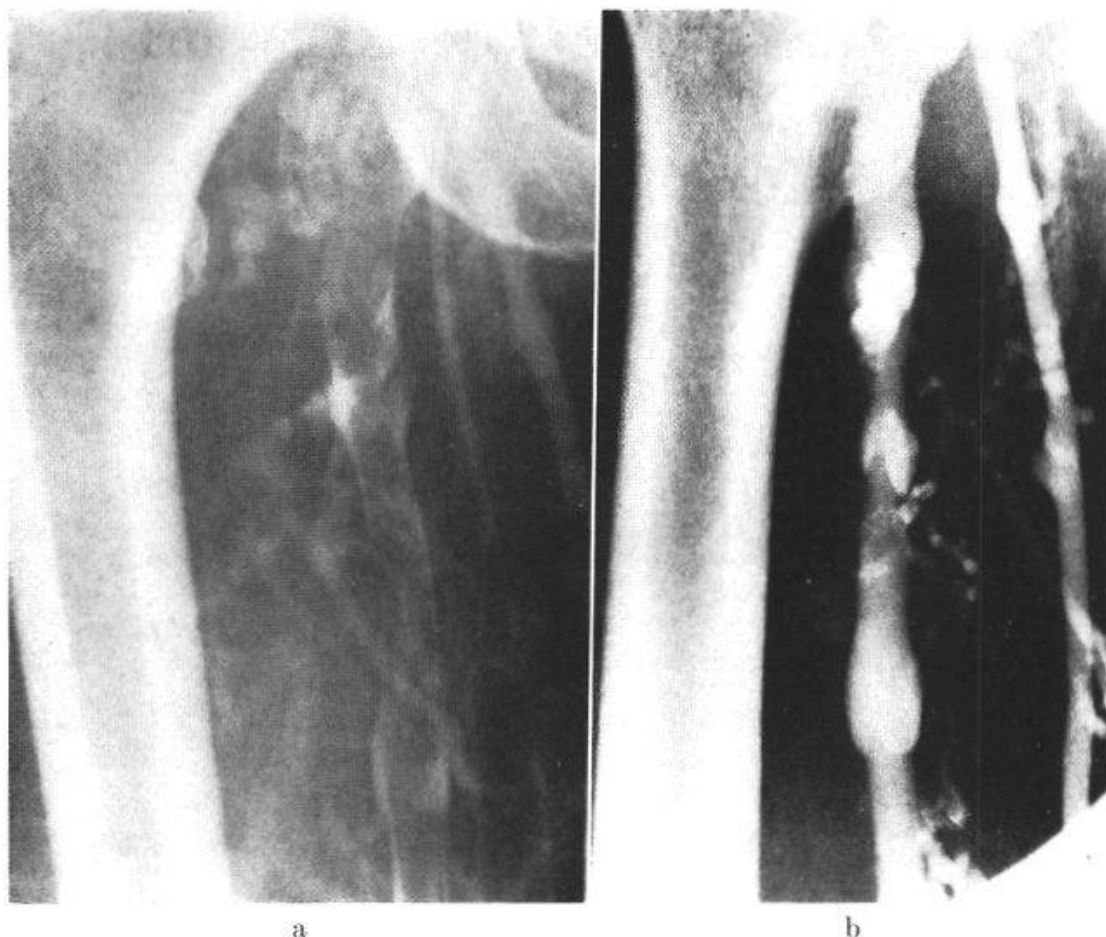


Fig. 3. – a) Phlebogram before treatment shows extensive thrombus in the femoral vein, surrounded by a rim of contrast medium. – b) After streptokinase therapy, there is uniform filling of the femoral vein, representing complete clearance. Both valve cusps are seen. – Reproduced by kind permission of the Editor of the British Medical Journal.

in 3 whose thrombi appeared unchanged (Fig. 4). Of the 8 patients treated with streptokinase, thrombus radioactivity fell to almost zero level in 6 and in each of these venograms showed complete dissolution of all thrombi (Fig. 4). The findings of 9 patients treated with Ancrod are shown in Fig. 4.

*Side effects:* In patients receiving heparin, treatment had to be stopped in 2 because of bleeding: One patient had a large retroperitoneal haemorrhage on the 7th day which caused renal failure from which he later died. Another patient developed melaena which required the injection of protamine and transfusion of 2.8 litres of blood for its control. Bleeding was also a feature in 3 cases receiving streptokinase infusion; in 2 it was severe enough to require neutralisation of the circulating activator with aminomethylcyclohexane carboxylic acid (cyclokapon). 4 patients developed a rise in temperature of between 2° and 5 °F (1.1° and 2.8 °C), often with rigors, during the first 48 h of streptokinase infusion. Acute dyspnoea and tachycardia occurred in 2 patients during the administration of the loading dose but symptoms were rapidly controlled by the intravenous administration of 10 mg of chlorpheniramine maleate (Piriton).

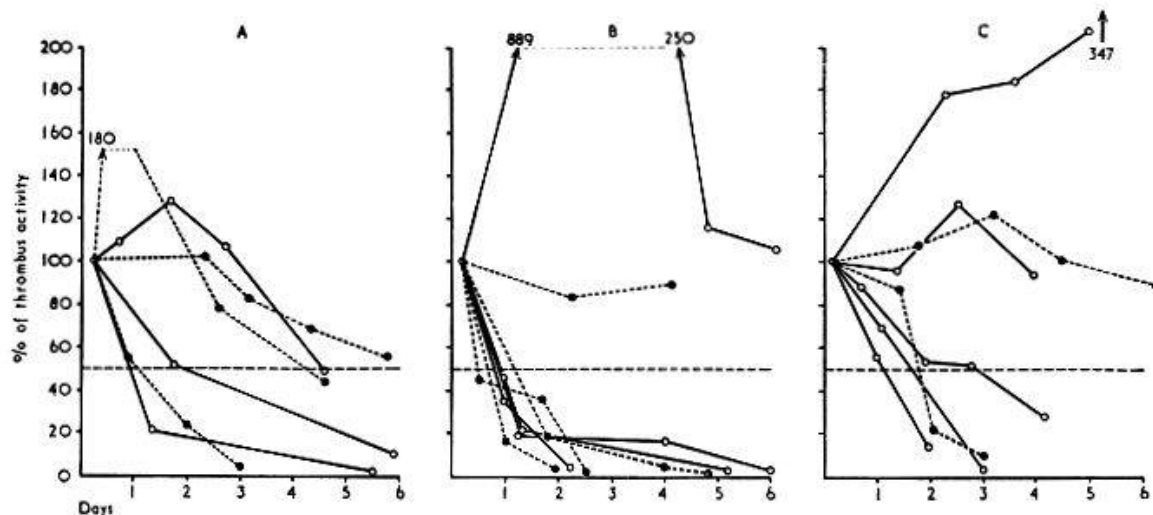


Fig. 4. Changes in thrombus radioactivity. – A: 6 patients treated with heparin. B: 8 patients treated with streptokinase. – C: 7 patients treated with Ancrod. – Reproduced by kind permission of the Editor of the British Medical Journal.

Complications were rare in patients receiving ancrod infusion. One patient suffered from a small melaena on the 12th day which did not require transfusion. Another patient with severe asthma developed an acute confusional state which rapidly resolved when the infusion was stopped on the 6th day.

### B. Late results

22 patients with deep vein thrombosis who had been treated during the acute phase with heparin, streptokinase or Ancrod were followed up in an attempt to answer the following question: which form of initial treatment was most successful in procuring the eventual return to normal of the involved veins? What are the critical factors involved in the preservation of venous valvular function?

The legs were re-examined several months after the original treatment, by ascending functional cinephlebography, the details of which have been described elsewhere [13]. Valvular function, as seen on the television monitor, was recorded on cine-film. Three different types of results were seen: normal, poorly-functioning and absent valves. Valvular function was considered normal when both valve cusps were visible and flexible, opening to allow onward flow of blood and closing during the Valsalva manoeuvre to prevent retrograde flow. It was considered that valve function was poor when the valve cusps could be seen on the cine-film but did not open and close, and retrograde flow occurred. In the third group of patients, X-rays showed no sign of surviving valves.

Only 8 of the 22 patients studied had complete dissolution of thrombi at the initial treatment. 5 of these showed normal valvular function when re-examined 6–12 months later by cinephlebography (Table 4). In all cases where valvular function returned to normal, the diagnosis of venous thrombosis had been made early, within 36 h of the onset of thrombosis, and in

Table 4  
Late results of treatment – Valvular function up to 12 months after initial treatment

Initial treatment	Patients	Valvular function		
		normal	poor	absent
Heparin	8	1	1	6
Streptokinase	7	4	1	2
Ancrod	7	0	1	6
Total	28	5	3	14

each case thrombi had been cleared rapidly, within 72 h of starting treatment, as judged by phlebography. The remaining 14 patients had only partial clearance of thrombi after completing the initial treatment and in none of these could valves be demonstrated subsequently.

### Discussion

The results of this study show that thrombolysis is more effectively achieved with streptokinase than with heparin or Ancrod. Similar encouraging results of thrombolytic therapy have also been reported by several other workers [4, 8, 20, 21]. Even streptokinase is not uniformly successful; factors known to affect the outcome are the extent and age of the thrombus. Since the activator must reach the surface of the thrombus to produce the desired effect, thrombolysis is achieved more rapidly in a vessel which is not completely occluded. The age of the thrombus appears to be more important than its extent; the best results are obtained when it has been present for less than 36 h before treatment is commenced. Other factors which may influence the final outcome have been discussed in detail elsewhere [16].

There are certain disadvantages in using streptokinase; immediate allergic reactions and pyrexia are not uncommon and have sometimes been troublesome; prophylactic hydrocortisone administration may not control these effectively. Because of the risk of haemorrhage, close laboratory supervision is required to give forewarning of a likely bleeding episode. This would perhaps be most obvious when the presence of excessive fibrinogen lysis products have caused an unusual prolongation of thrombin time.

The value of streptokinase in preventing the postphlebotic syndrome has yet to be determined. This study has shown that early diagnosis is of great importance for preserving the valves in the affected segments of deep veins. At this stage, organisation of thrombus has not taken place and complete lysis is possible. To be as certain as possible of preserving valvular function, the diagnosis must be made within 36–48 h of the onset of thrombosis, and the thrombus dissolved rapidly. When heparin or Ancrod were used, initial



clearance of veins was slower and less complete, and subsequent valvular function less satisfactory. The number of patients investigated in this study was small and therefore no definite conclusions can be drawn. The findings do, however, give a hint of the possible benefits of using streptokinase. Work is now in progress where a large number of patients treated with streptokinase are being followed up for longer periods to see if the use of this drug will help in preventing the late sequelae.

### Summary

Treatment of deep vein thrombosis aims to dissolve the thrombus completely and to preserve valvular function. It is still not clear which is the best form of medical treatment to achieve these aims and in only a few controlled trials has the effect of treatment been assessed by using objective criteria. In this paper, the results of a randomly-controlled trial are presented. 30 patients with extensive thrombosis of less than four days' duration were allocated at random to treatment with heparin, streptokinase or Ancrod, under laboratory control. When the fate of the thrombi was assessed by objective techniques – phlebography and the  $^{125}\text{I}$ -labelled fibrinogen test – the incidence of complete thrombolysis was greatest in the streptokinase group. Complications arose during treatment in each group, but were least with Ancrod.

22 patients out of 28 treated during the acute phase, were restudied by a new technique of ascending functional cinephlebography, 6–12 months after the episode of thrombosis. It was found that, if the condition was diagnosed within 36 h and the thrombus dissolved rapidly, valvular function was preserved. When diagnosis was delayed, there was a great risk of permanent damage to the valves. The natural history of the disease favours clinical but not always anatomical recovery.

### Zusammenfassung

Das Ziel einer Behandlung tiefer Venenthrombosen ist die vollständige Auflösung des Thrombus und die Erhaltung der Klappenfunktion. Es ist immer noch nicht geklärt, mit welcher medizinischen Behandlung dieses Ziel am besten erreicht werden kann, und nur in wenigen kontrollierten Studien ist der Behandlungserfolg mit Hilfe objektiver Kriterien geprüft worden. In diesem Bericht werden die Resultate einer randomisierten kontrollierten Studie dargestellt. 30 Patienten mit extensiven Thrombosen von weniger als 4 Tagen Zeitdauer wurden randomisiert, verteilt auf Behandlung mit Heparin, Streptokinase oder Ancrod unter Laboratoriumskontrolle. Wenn das Schicksal der Thromben durch objektive Methoden beurteilt wurde – Phlebographie und  $^{125}\text{I}$ -Fibrinogentest – war die Häufigkeit einer vollständigen Thrombolyse am grössten in der Streptokinasegruppe. Komplikationen traten während der Behandlung in jeder Gruppe auf, waren aber am geringsten mit Ancrod.

Von 28 Patienten, die während der akuten Phase behandelt wurden, wurden 22 6–12 Monate nach der Thromboseepisode einer Nachprüfung mit einer neuen Technik unterzogen, die mit aufsteigender funktioneller Kinephlebographie arbeitet. Es wurde gefunden, dass, wenn die Störung innerhalb von 36 Std. diagnostiziert und der Thrombus rasch aufgelöst wurde, die Klappenfunktion erhalten blieb. Erfolgte die Diagnose verspätet, so resultierte ein grosses Risiko einer permanenten Klappenschädigung. Die natürliche Entwicklung des Leidens begünstigt klinische, aber nicht immer anatomische Erholung.

### Résumé

Le but de tout traitement d'une thrombose veineuse profonde est la dissolution complète du thrombus et le maintien de la fonction valvulaire. On n'est pas encore au clair sur la méthode de traitement médical idéale pour atteindre ce but, et ce n'est que dans quelques études sérieuses que le succès thérapeutique a été vérifié selon des critères objectifs. Dans la présente étude sont présentés les résultats d'un tel travail: 30 patients avec des thromboses importantes et d'une durée de moins de 4 jours ont été choisis au hasard pour être traités avec de l'héparine, de la streptokinase ou de l'Ancrod, sous contrôle de laboratoire. Dans les cas où il a été possible de contrôler l'évolution de la thrombose par des méthodes objectives – phlébographie et test de fibrinogène à l'isotope  $I^{125}$ , – c'est avec la streptokinase que la fréquence de la lyse complète des thrombi a été la plus grande. Dans chaque série il y eut des complications durant le traitement, mais c'est avec l'Ancrod qu'elles ont été les plus banales.

Des 28 patients qui ont été traités dans la phase aiguë, 22 ont pu être revus 6–12 mois plus tard, et ceci avec une nouvelle technique, qui comprend la cinéphlébographie fonctionnelle ascendante. On a pu constater que lorsque l'affection avait été reconnue dans les 36 h et le thrombus rapidement lysé, les valvules restaient fonctionnelles. Si le diagnostic avait été tardif, il y avait un grand risque que la lésion valvulaire restait permanente. L'évolution clinique naturelle favorise une guérison clinique, mais non toujours anatomique.

### Riassunto

Lo scopo di una terapia delle trombosi venose profonde è la dissoluzione completa del trombo e la conservazione della funzione valvolare. Non è ancora chiaro quale mezzo terapeutico possa meglio raggiungerlo, ed il successo di un trattamento è stato controllato con criteri oggettivi solo in pochi studi. In questo articolo si espongono i risultati di uno studio controllato randomizzato. Trenta pazienti con trombosi estese datanti di meno di quattro giorni sono stati trattati, sotto stretto controllo di laboratorio, rispettivamente con eparina, streptochinasi oppure Ancrod. Apprezzando il destino dei trombi con metodi oggettivi (flebografia e test al fibrinogeno marcato con

iodio-125), si trova una maggiore frequenza di trombolisi completa nel gruppo trattato con la streptochinasi. In ognuno dei tre gruppi ci furono delle complicazioni durante la cura; esse furono più rare nel gruppo trattato con Ancrod.

Di 28 pazienti curati durante la fase acuta, 22 furono controllati con una nuova tecnica basata sulla cineflebografia funzionale ascendente da 6-12 mesi dopo l'episodio trombotico. Si è trovato che nei casi in cui la diagnosi della trombosi fu fatta nelle prime 36 ore e la dissoluzione del trombo ottenuta precocemente, la funzione delle valvole restò inalterata. Nei casi di diagnosi tardiva, il rischio di lesioni valvolari permanenti è grande. L'evoluzione spontanea della malattia favorisce il recupero clinico, ma non sempre quello anatomico.

1. ATKINS P. and HAWKINS L. A.: *Lancet* 1965/II, 1217.
2. BEECHER H. K.: *J. clin. Invest.* 16, 733 (1937).
3. BELL W. R., PITNEY W. R. and GOODWIN J. F.: *Lancet* 1968/I, 490.
4. BROWSE N. L., THOMAS M. L. and PIM H. P.: *Brit. med. J.* 1968/III, 717.
5. EVANS D. S. and COCKETT F. B.: *Brit. med. J.* 1969/II, 802.
6. FLANC C., KAKKAR V. V. and CLARKE M. B.: *Brit. J. Surg.* 55, 742 (1968).
7. FLETCHER A. P. and ALKJAERSIG N.: *Thrombos. et Diathes. haemorrh. (Stuttg.) Suppl.*, 389 (1971).
8. GORMSEN J.: *Symposium on Thrombolytic Therapy with Streptokinase, Munich 1967*, p. 41-49.
9. GORMSEN J. and LAURSEN B.: *Acta med. scand.* 18, 387 (1967).
10. KAKKAR V. V. and FLANC C.: *Brit. J. Surg.* 55, 384 (1968).
11. KAKKAR V. V., FLANC C., HOWE C. T. et al.: *Brit. med. J.* 1969/I, 806.
12. KAKKAR V. V., FLANC C., O'SHEA M. J. et al.: *Brit. J. Surg.* 56, 178 (1969).
13. KAKKAR V. V., HOWE C. T., LAWS J. W. et al.: *Brit. med. J.* 1969/I, 810.
14. KAKKAR V. V., HOWE C. T., NICOLAIDES A. N. et al.: *Amer. J. Surg.* 120, 527 (1970).
15. KAKKAR V. V.: *Milbank mem. Fund Quart.* 1, 206 (1971).
16. KAKKAR V. V.: *Arch. Surg.* 104, 152 (1972).
17. LINTON R. R. and HARDY I. B.: *Surgery* 24, 452 (1948).
18. NEGUS D., PINTO D. J., LE QUESNE L. P. et al.: *Brit. J. Surg.* 55, 835 (1968).
19. NIEWIAROWSKI S. and GUREWICH V.: *J. Lab. clin. Med.* 77, 665 (1971).
20. ROBERTSON B. R., NILSSON I. M. and NYLANDER G.: *Acta chir. scand.* 134, 203 (1968).
21. SCHMUTZLER R., HECKNER F., KORTZE P. et al.: *Germ. med. Mth.* 11, 308 (1966).
22. SIGEL B., POPKY L., WAGNER D. K. et al.: *Surg. Gynec. Obstet.* 127, 339 (1968).
23. WHEELER H. B. and MULLICK S. C.: *Ann. N. Y. Acad. Sci.* 170, 804 (1970).

Address of author: V. V. Kakkar, FRCSE FRCS, Consultant Surgeon and Senior Lecturer, King's College Hospital Medical School, Department of Surgery, Denmark Hill, London SE5 8RX.