

Autologous Tendon Transplantation in the Horse : the technic and its histologic evaluation

Autor(en): **Fackelman, G.E.**

Objektyp: **Article**

Zeitschrift: **Schweizer Archiv für Tierheilkunde SAT : die Fachzeitschrift für Tierärztinnen und Tierärzte = Archives Suisses de Médecine Vétérinaire ASMV : la revue professionnelle des vétérinaires**

Band (Jahr): **115 (1973)**

Heft 6

PDF erstellt am: **20.09.2024**

Persistenter Link: <https://doi.org/10.5169/seals-592091>

Nutzungsbedingungen

Die ETH-Bibliothek ist Anbieterin der digitalisierten Zeitschriften. Sie besitzt keine Urheberrechte an den Inhalten der Zeitschriften. Die Rechte liegen in der Regel bei den Herausgebern.

Die auf der Plattform e-periodica veröffentlichten Dokumente stehen für nicht-kommerzielle Zwecke in Lehre und Forschung sowie für die private Nutzung frei zur Verfügung. Einzelne Dateien oder Ausdrucke aus diesem Angebot können zusammen mit diesen Nutzungsbedingungen und den korrekten Herkunftsbezeichnungen weitergegeben werden.

Das Veröffentlichen von Bildern in Print- und Online-Publikationen ist nur mit vorheriger Genehmigung der Rechteinhaber erlaubt. Die systematische Speicherung von Teilen des elektronischen Angebots auf anderen Servern bedarf ebenfalls des schriftlichen Einverständnisses der Rechteinhaber.

Haftungsausschluss

Alle Angaben erfolgen ohne Gewähr für Vollständigkeit oder Richtigkeit. Es wird keine Haftung übernommen für Schäden durch die Verwendung von Informationen aus diesem Online-Angebot oder durch das Fehlen von Informationen. Dies gilt auch für Inhalte Dritter, die über dieses Angebot zugänglich sind.

Autologous Tendon Transplantation in the Horse – The Technic and its Histologic Evaluation

by G.E. Fackelman¹

Introduction

Tendinitis has been the subject of many papers dealing wholly or in part with equine lameness. Many geneses of the disease have been put forth and at least as many therapeutic measures proposed and performed.

These forms of therapy, most of which employ either chemical or thermal cauterization, have been extensively reviewed by Milne (1960) in his dissertation concerning the use of counterirritation in the horse.

Beginning with Forssell's work in the early 1930's, Sweden has been a center of activity directed toward the development of better operative techniques for the treatment of tendinitis. Specific references regarding the performance and the evaluation of these techniques are presented below.

In 1969, Professor K. Ammann gave impetus to the development of a different form of therapy utilizing transplanted tendon tissues. The author has attempted, in the conception and development of the corresponding surgical procedure, to aim at solving the actual problem at hand: the replacement of damaged tissues by normal healthy tendon.

It is the purpose of this paper to present the technique along with the rationale for its development; and to show through histological studies, that the transplanted tissue survives as true tendon; with an enrichment of the intratendinous blood supply taking place during the healing process.

Review of the Literature

The literature reviewed in this section was extracted with only few exceptions from sources in human medical journals. It is not only of historical interest but also provided the rationale for the conception and development of a logical transplantation technique. Further pertinent references are cited in later sections in direct association with the facet of the subject to which they apply.

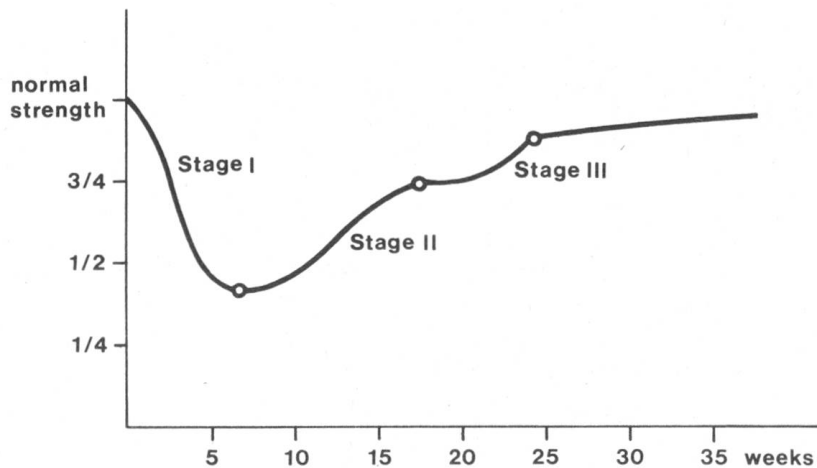
In 1914, Rehn, working with dogs, observed that the Achilles tendon could be replaced by strips of skin. This skin subsequently underwent metaplastic changes so that, with time, it came to resemble normal tendinous tissue.

¹ Address of the Author: G.E.Fackelman, DVM, Winterthurerstrasse 260, CH-8057 Zürich (Switzerland).

In a further work in 1919, the same author noted that if tendinous tissue is transplanted subcutaneously, it only remains tendinous if placed under tension. These observations provided stimulus to investigations into the peculiarities of the healing process that takes place in a tendon severed from its original blood supply, and the factors influencing these processes. Whether the severance occurred due to direct traumatic injury or through operative transplantation of the tendon segment, it appeared important for healing that the surrounding milieu be properly prepared and maintained postoperatively following certain principles. These principles were not necessarily those to be assumed based upon experience with other types of tissues.

Mason and Allen (1941) divided the healing process of severed tendons into three stages: 1) that of exudation and fibrous union, 2) that of fibroplasia and 3) that of maturation or organizing differentiation. The tensile strength of the tendon during these stages plotted against time in weeks can be graphically represented as follows:

Table 1



According to these authors, function of the part during stages I and II is deleterious to healing, whereas during stage III it tends to accelerate the process.

Skoog and Persson (1954) stress the importance of the paratenon in the healing of an injured tendon. These authors define the paratenon as the subcutaneous connective tissue, i. e. the fascia, surrounding a tendon. They found it to be by far the most important source of new fibrous tissue proliferating between the ends of a cut tendon or surrounding a tendon graft.

The peritenon, that smooth layer of connective tissue directly investing the tendon, showed no significant regenerative function for the first three weeks following operation or injury. It was noted however, that the subcutaneous tissue reaction was not as great when the peritenon covering an injured tendon remained intact. Endotenon, the trabeculae of connective tissue between the tendon fiber bundles, was found to have no regenerative function at all.

Berkin (1954) working with the effects of cortisone upon the healing of tendon, states that most surgeons maintain complete immobilization of an operated extremity for two to three weeks post surgically, thereafter allowing active movements only within a limited range.

That a drug like cortisone is given any consideration at all as postsurgical therapy, points up one of the biggest problems of tendon injuries, be they traumatic or surgical in nature: the formation of postoperative adhesions. These adhesions form with surrounding structures such as bone, skin, ligaments or other tendons, and seriously compromise the free movements of the injured tendon after healing has taken place. They stem from an exuberant phase of fibroplasia during the healing process.

Pulvertaft (1948) attempts to prevent the formation of these motion-limiting fibroplastic changes by encouraging the passive movement of the part as early as the fifth postoperative day, and condemns corticosteroids for reducing the tensile strength of the resultant structure.

Ketchum (1971) found, however, that a compromise situation could be attained by the local administration of triamcinolone in amounts not to exceed 1 mg/kg. At this dosage he saw, in his experimental dogs, no decrease in tensile strength and markedly fewer adhesions.

Wheat (1955) and Garner (1965) warn against the local use of corticosteroids in the horse because of the frequent subcutaneous calcinosis that occurs following their administration.

In an article dealing with the use of artificial tendon sheaths for the prevention of postoperative adhesions in man, Nicolle (1969) gets to the heart of the matter by suggesting prevention rather than cure. He considers accurate hemostasis and the elimination of plasmatic exudations from the wound to be of paramount importance.

In his work with artificial sheaths for tendon transplants, Potenza (1963) found that the resultant isolation of the tendons from the surrounding tissues could be disastrous. Necrosis of the enveloped tendons occurred due to the inability of proliferating blood vessels to reach the new tissues in time to satisfy their nutritional demands.

Building upon these observations, Colville (1969) was able to successfully employ silastic sheaths for the prevention of adhesions by first enclosing the tendon destined to be transplanted in the artificial sheath in such a way as to leave the mesotenon intact. Later, the entire tendon – mesotenon – silastic sheath unit was transplanted to the new site. Anastomoses could form with the vessels of the mesotenon and the new tendon segment was adequately resupplied along its entire length. No necrosis occurred.

The importance of an intact mesotenon, especially in the event that contact with the surrounding tissues is cut off, had already been pointed out by Smith (1964). He demonstrated that the circulation to a tendon reaches it almost entirely through the mesotenon and is segmental in nature. Collateral anastomoses between segments within the tendon are capable of supporting an additional length of only 1–2 cm on either side of a given arcade.

Tendon healing at the cellular level was documented by Peacock (1964) in a classical study of the rôle of collagen in the repair of wounds and the healing of tendons. His findings were brought forth again and expanded upon in 1965 at the Symposium on the Hand [35]. It was found that the at first amorphous collagen produced by the injured tissues becomes fibrillar under the proper conditions of temperature and pH. These fibrils then become organized so that by three months post-injury, they are found to be longitudinally oriented between the severed tendon's ends and randomly oriented in the surrounding tissues. Macroscopically, the scar filling in the gap is difficult if not impossible to distinguish from normal tendinous tissue. The random oriented fibers in the surrounding fascia act to replace the original "gliding tissues" so important to the proper motion of tendons in areas lacking a synovial sheath. Peacock believes that any excess collagen is subsequently "trimmed off" by the action of a specific collagenase enzyme. He cites Gross and Capiere as having been able to demonstrate the existence of this enzyme in tadpoles.

Schenk (1971) working with osteoblasts, showed that the site of production of tropocollagen, the forerunner of collagen, is intra-cellular. The amorphous material is then actively extruded through the cell membrane and polymerizes to collagen in the inter-cellular space.

Bringing us to clinical veterinary medicine, and more specifically to the tendons of a horse, there occurred in the late 1960's in Sweden a renaissance of a technique originally proposed by Forssell in 1931. According to this method, an injured tendon is longitudinally split along its posterior surface. A pathway is thus opened for proliferating fibroblasts to reach the actual site of pathology, the center of the tendon. This blood-vessel-bearing granulation tissue will eventually save the life of the tendinous tissue whose

nutrient supply was destroyed in the catastrophe of partial rupture. Åsheim presented this technique in only slightly modified form in 1964 and was cited later that year by Sevelius at the British Equine Veterinary Association Congress. The method was then further modified by Åsheim and Knudsen (1967) to consist of slits created medially and laterally through bilateral serial percutaneous stab incisions on the affected leg. Roberts (1969) recommends this technique and a further modification whereby the tendon is tunnelled along its length by the boring action of a specially constructed bistoury.

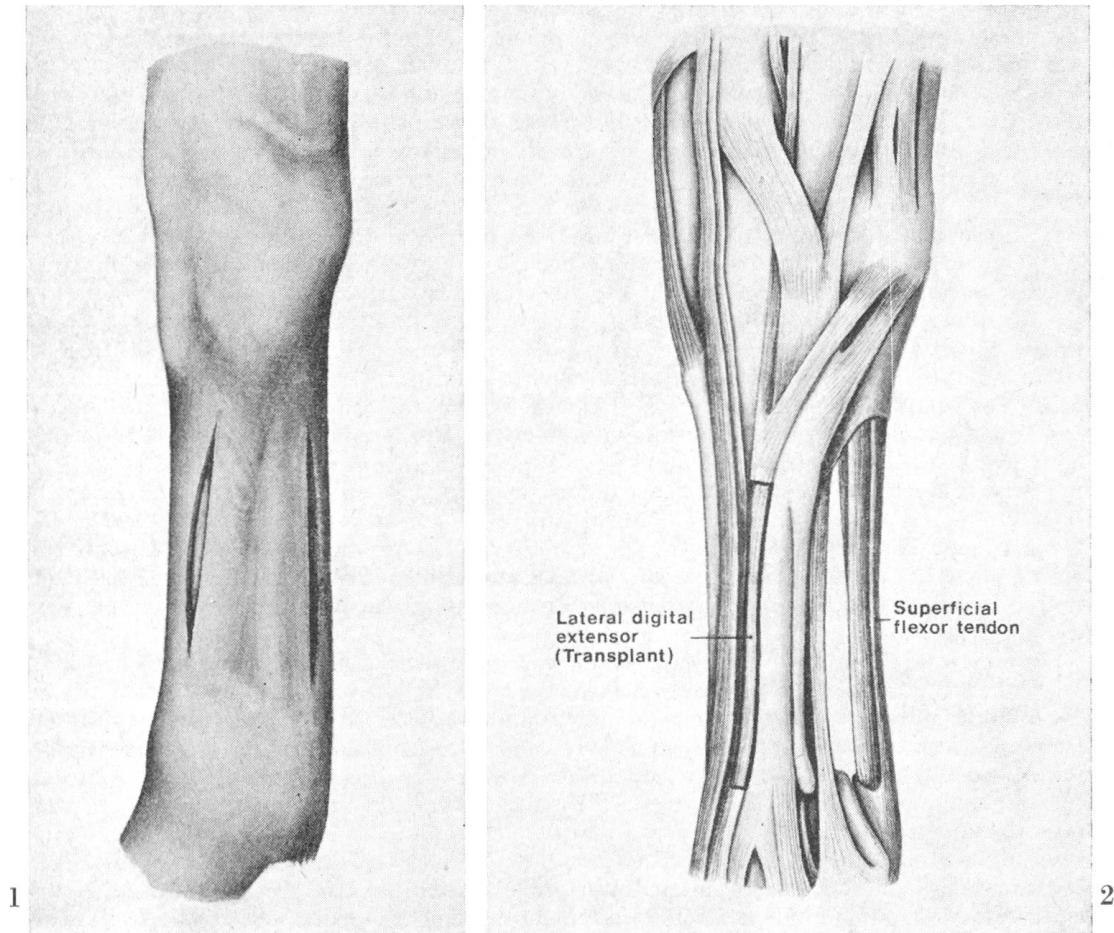


Fig. 1. The skin incisions for the exposure of the lateral digital extensor tendon and the superficial flexor tendon are located in the dorsolateral and posterolateral metacarpus respectively.

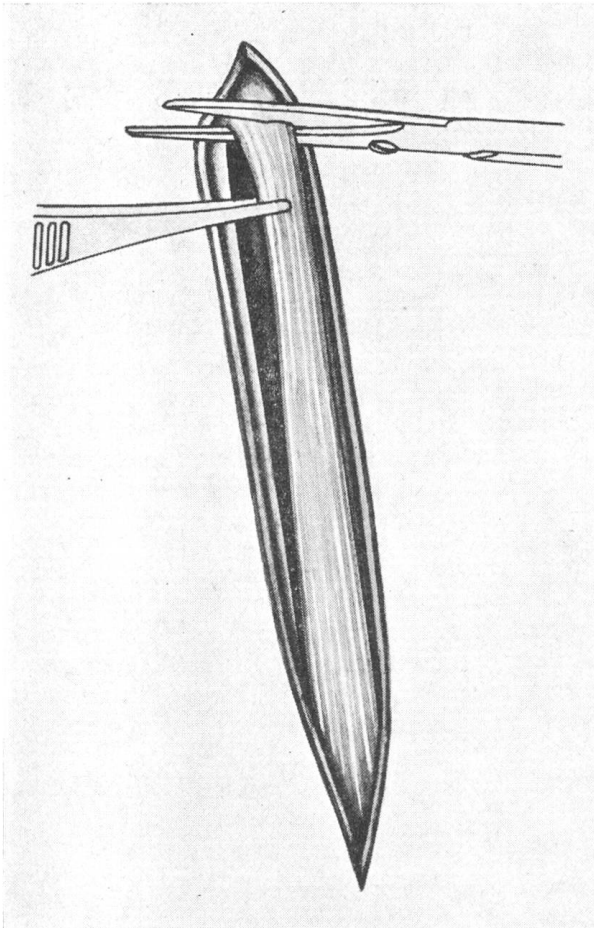
Fig. 2. This anatomic drawing illustrates the size and spatial relations of the transplant (bold line) and recipient tendons.

Nilson (1971) reiterates the method and presents good results in a more clinically oriented article wherein he claims 70–75% healing of lesions of the superficial digital flexor.

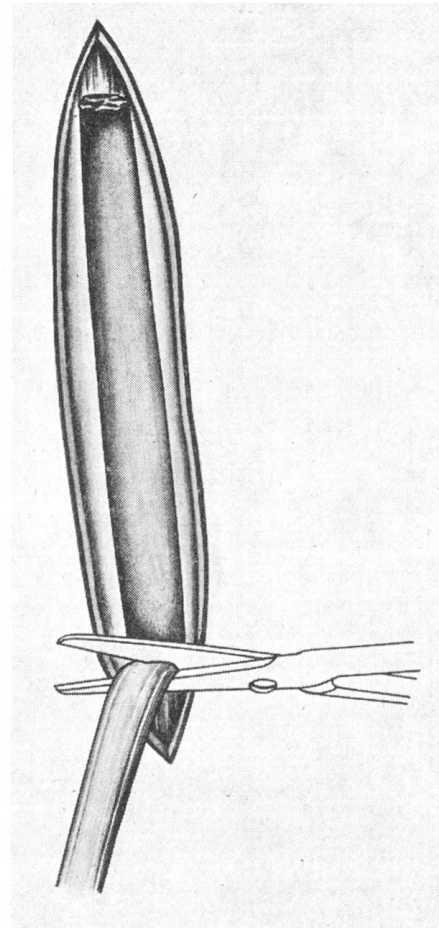
The major work of Strömberg (1971) lends credence to the assumption that an increase in the blood supply to the interior of an injured tendon is of therapeutic value. He demonstrates that, conversely, an area of sparse blood supply in a tendon is predisposed to degenerative changes and ultimate rupture.

Materials and Methods

Ten normal horses ranging in age from 8 to 22 years were operated upon in connection with this study. General anesthesia was induced by the administration of 0,8 gm/100 kg sodium pentothal preceded by 1,2 gm/100 kg propiomazine tranquilizer and 2 mg/100 kg atropine sulfate, and maintained



3



4

Fig. 3. The lateral digital extensor tendon is laid free along its metacarpal extent and transected first at the proximal end of the skin incision.

Fig. 4. The section of tendon to be transplanted is reflected distad and freed from all fascial attachments.

with halothane. The animal's respirations were assisted with the Bird Mark 9 Respirator and the blood pH monitored according to the method described by Backes and Skarda (1972).

The operative field was clipped, shaved and prepared for aseptic surgery in the usual manner, the patient being placed in lateral recumbency with the

leg to be operated upon uppermost. The surgical technique corresponded to that described by Ammann and Fackelman (1972).

Following draping of the surgical field, an incision is made over the lateral digital extensor tendon in the anterolateral metacarpus (see Fig. 1). The tendon is carefully dissected free from the surrounding subcutaneous vessels and fascia and accurate hemostasis is carried out with electrocoagulation. A section of

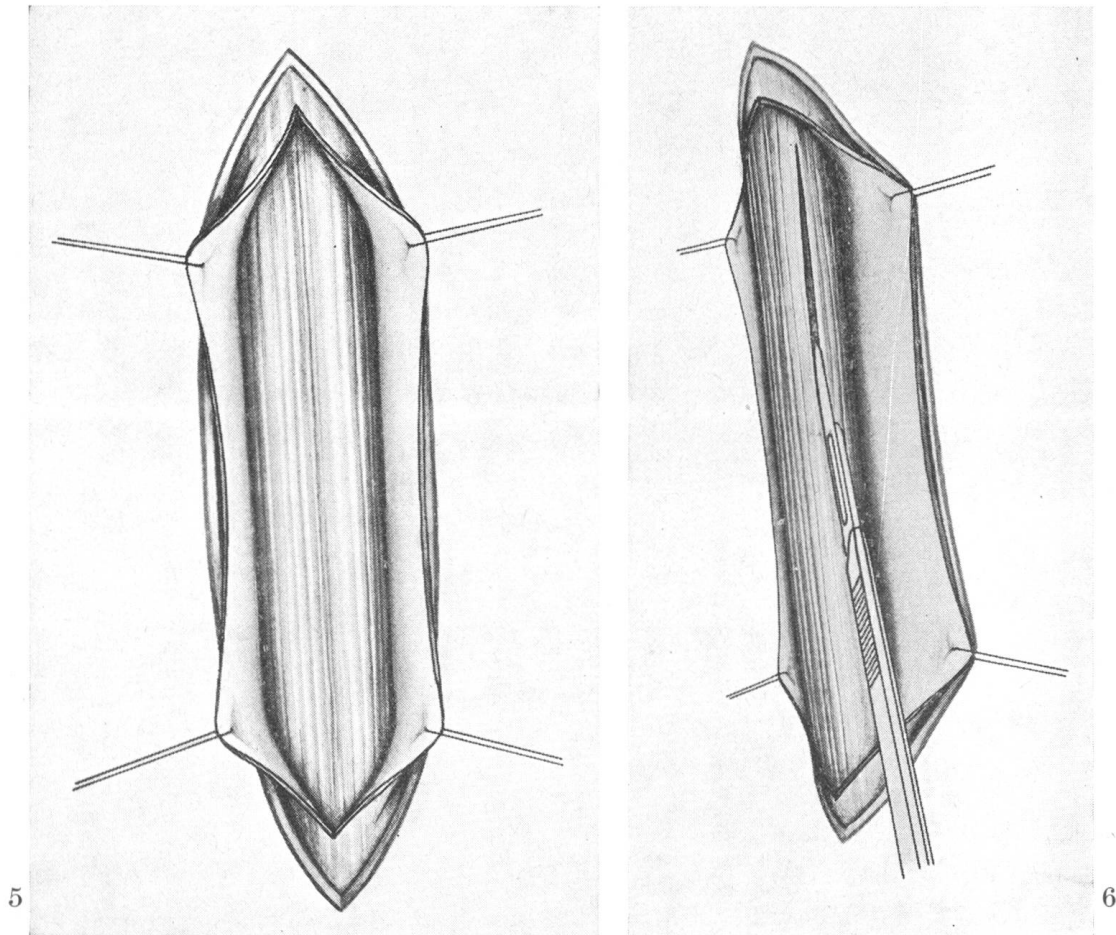


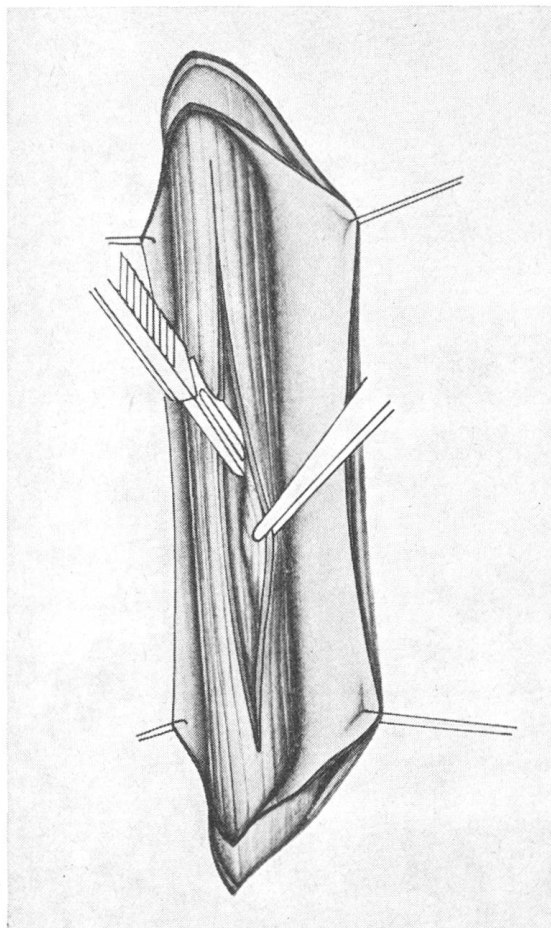
Fig. 5. The paratendon is incised, carefully prepared as a definitive layer, and reflected from the underlying flexor tendons.

Fig. 6. The initial incision in the flexor tendon is placed on the middle of its posterior surface parallel to its fibers, in a sagittal plane.

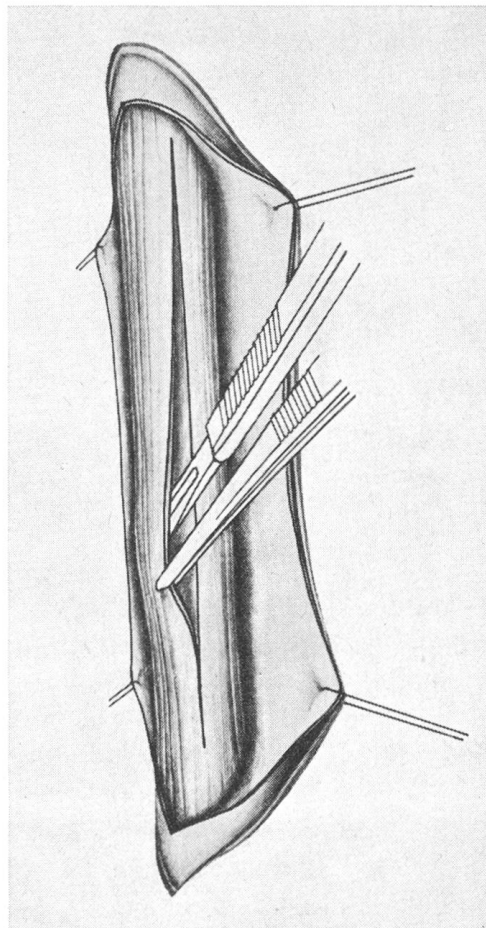
tendon 10–12 cm long is removed, the initial transection being at the proximal extremity of the skin incision (see Fig. 3 and 4). The resected tendon is then wrapped in a gauze sponge previously moistened in warm Ringer's saline solution. Closure of the incision consists of continuous suture in the loose areolar tissue and a line of interrupted Donati sutures in the skin. Suture

material used was 4-0 teflon¹ in the fascia and 3-0 polyamide² adapting the skin edges.

Draping having already been carried out so as to include the operative site over the superficial flexor tendon, one can immediately begin the second skin incision. If working as a team, the second incision may be made while the assistant surgeon closes the first.



7



8

Fig. 7. A secondary incision is made beginning within the primary split – this incision is made in a frontal plane, with the point of the scalpel directed medially.

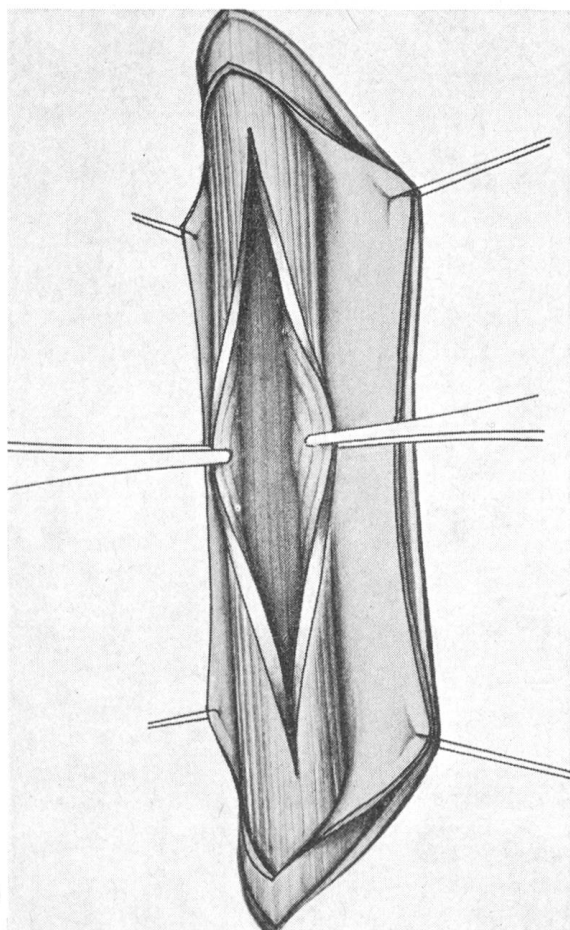
Fig. 8. Another secondary incision is placed in the tendon likewise beginning within the primary split and in a frontal plane. In this case, however, the point of the scalpel is directed laterally.

The incision for the exposure of the flexor tendons is placed postero-laterally. The paratenon is incised, carefully prepared as a definitive layer, and reflected from the underlying tendons (Fig. 5). The superficial flexor is

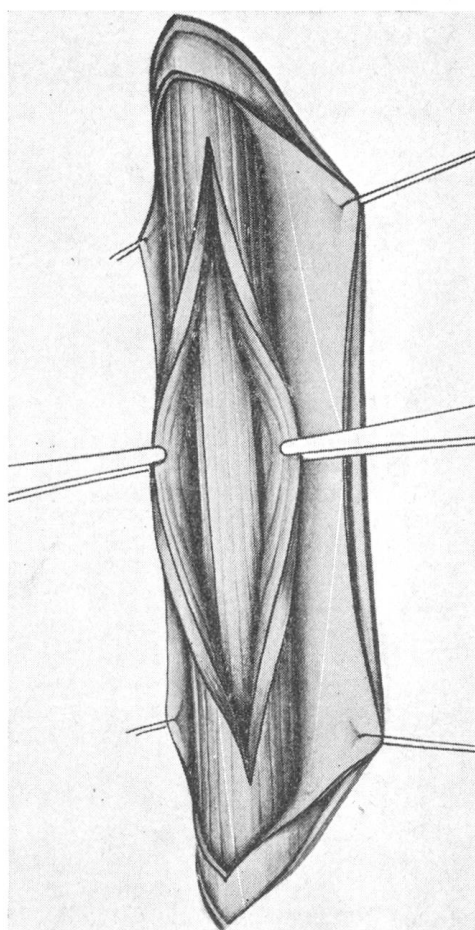
¹ Silky Polydek – Sterile Catgut Gesellschaft, Neuhausen.

² Supramid – Sterile Catgut Gesellschaft, Neuhausen.

freed from any adhesions to the deep tendon as has been suggested by Proctor (1963). It is then split sagittally halfway through its thickness at the middle of its posterior surface (see Fig. 6). The incision is carried proximally and distally at least to the boundaries of the tendon sheaths. If made necessary by the nature of the pathology present, these sheaths may also be



9



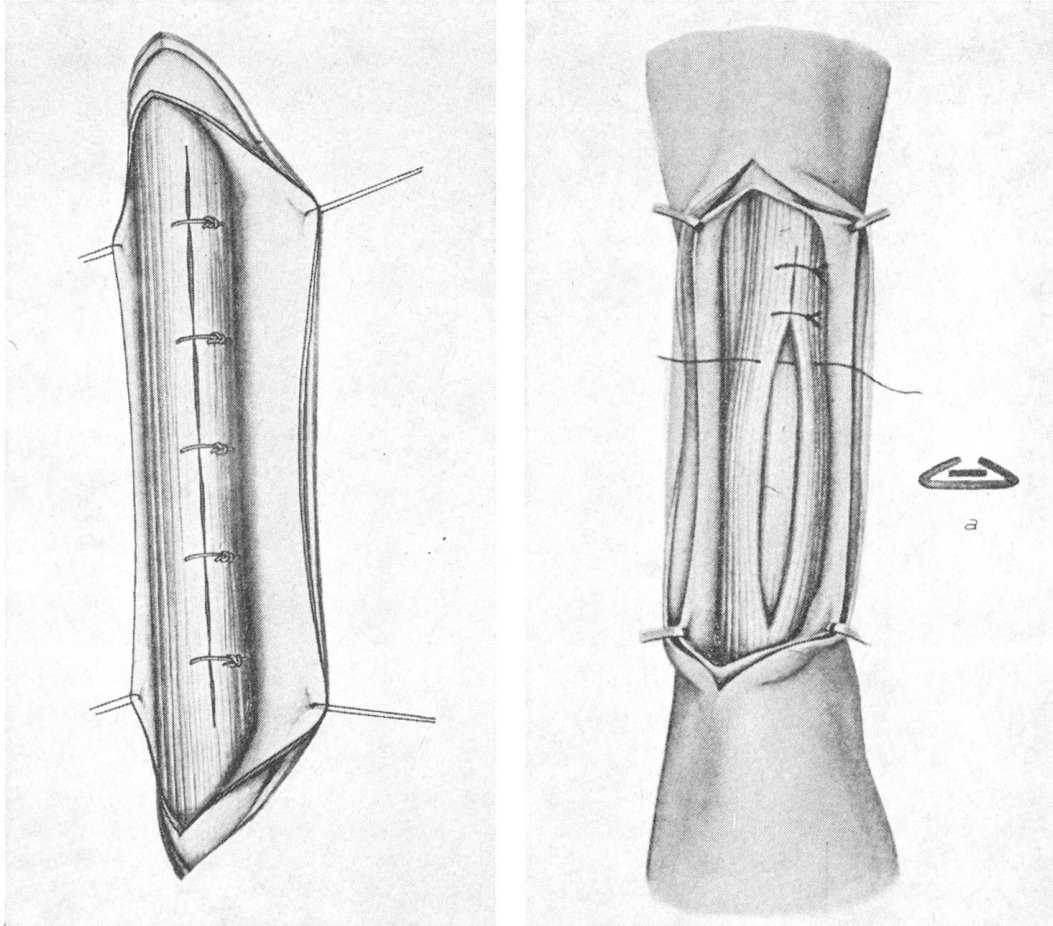
10

Fig. 9. Upon completion of the three incisions in the tendon, its interior can be everted and any hematoma or necrotic debris removed. The pocket in the flexor tendon is at this point ready to receive the transplant.

Fig. 10. The transplant is fitted into the cavity in the flexor tendon so that it just fills it. There should be no wrinkling, neither should the transplant be able to slide within its new surroundings.

invaded. Two further incisions are made in the tendon holding the scalpel parallel to the plane of the fibers, in a frontal plane, thus creating what in cross section resembles an inverted letter "T" (see Fig. 7 and 8). The flexor tendon may at this point be virtually turned inside out and any hematoma or damaged tissues removed from its interior (Fig. 9).

The transplant is trimmed free of any fascial remnants still attached to its edges and cut to the length desired. Any blood clots that have accumulated within the split tendon are carefully washed out with Ringer's solution and the transplant is fitted into its place within the flexor (see Fig. 10). A line of interrupted 4-0 teflon sutures is placed gently adapting the edges of the



12

Fig. 11. The edges of the split in the flexor tendon are adapted using fine atraumatic teflon suture material in a simple interrupted pattern.

Fig. 12. This sketch summarizes the operative procedure described thus far. At the right (a) is a diagrammatic representation of a cross-section taken through recipient and transplanted tendons to show their relationship to one another.

split tendon and its peritendineum (Fig. 11). The transplant is held firmly in position by the snugly fitting recipient tendon (see Fig. 12).

The perforated end of a polyethylene drainage tube is placed in contact with the tendon and the proximal end brought through the skin approximately 4 cm above the upper end of the major skin incision. Following closure of

the fascia, the tube is connected to a negative pressure drainage apparatus¹. It may help to prevent stoppage of this drainage system if one rinses it prior to installation with a dilute solution of heparin (ca. 5000 i.u.) in 20 ml Ringer's solution.

The fascia is closed over the drainage tube using 4-0 teflon suture material in a simple continuous pattern (Fig.13). The skin is closed as previously

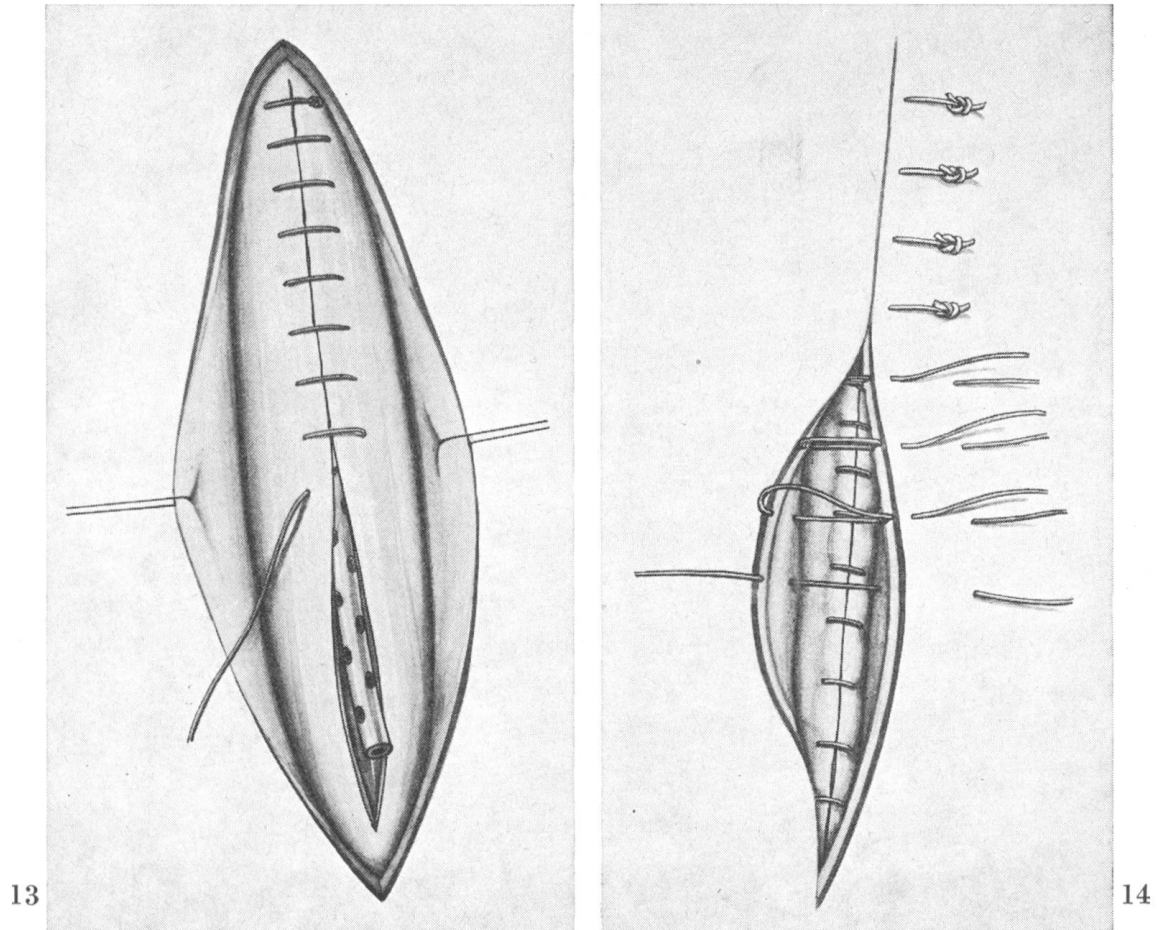


Fig. 13. A Redon drain is placed in contact with the tendon and the paratenon is closed over it with teflon in a simple continuous pattern.

Fig. 14. The skin is closed using polyamide in the Donati mattress suture pattern as modified by Allgöwer.

described for the lateral extensor using the Donati mattress suture as modified by Allgöwer (see Fig.14).

• Ten million i.u. of crystalline penicillin are infiltrated subcutaneously around the operative site to reinforce asepsis.

¹ Protovac - Protec AG, Bern

With the animal still in lateral recumbency, the extremity is elevated slightly, the wound dressed with a nitrofurantoin salve¹, and a fixation bandage applied. The latter is left in place 14 days postoperatively. The digital joints remain during this time in a slight ventroflexion (Fig. 15). The drainage tube can be removed independent of the bandage 4–6 days following surgery.

The patient receives 10 million i.u. crystalline sodium penicillin G b.i.d. routinely for 4 days post-surgically.

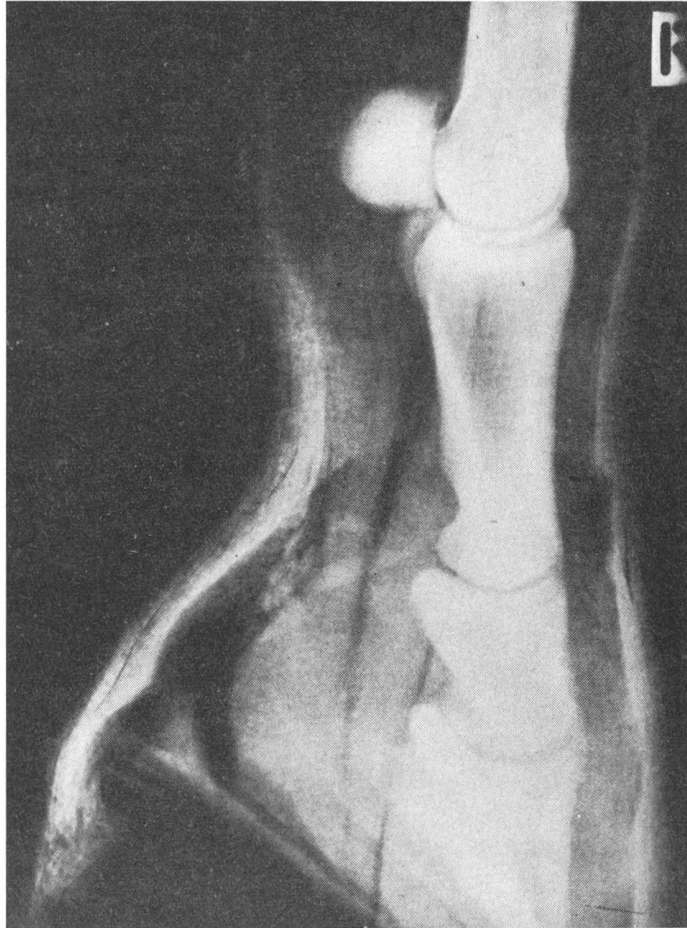

Fig. 15. Postoperatively, the leg is placed in a fiberglass – plaster of paris combination bandage so that the digital joints assume the position shown by this radiograph – one of slight ventroflexion.

Results

During the first 2–3 postoperative days the horse may show signs of acute pain and favor the operated leg markedly. This will disappear spontaneously, or if too severe may be ameliorated by the administration of salicylates or phenylbutazone.

¹ Escofuronsalbe – Streuli & Co., Uznach.

Neither in this group of experimental animals nor in any of the clinical cases operated upon, have rejection reactions been observed. Histological studies show that the transplanted tendon segments remain tendinous. They receive their blood supply from vessels that proliferate from the paratenon and enter mainly along the split in the flexor tendon.

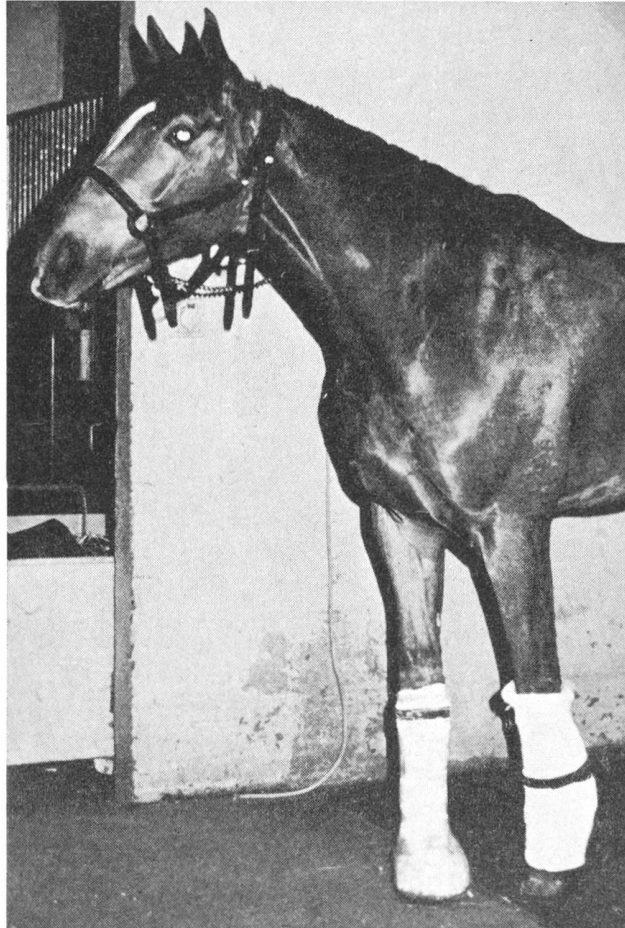

Fig. 15a. The horse in this photograph underwent tendon transplant surgery 10 days previously. He is able to bear full weight upon his operated limb without placing the flexor tendons under tension.

The results of the small number of clinical cases operated upon thus far have been gratifying. All of these horses had been returned to work within 6 months, and one animal is being successfully jumped one year following surgery.

Additional clinical cases, as well as the microangiographic evaluation of the above technique and one utilizing homologous tendons will be the subject of another paper.

Histology

Connective tissue is made up of 3 types of fibers and several different types of cells. Depending upon the function of the particular type of connective tissue studied, one or the other of these fibers and certain combinations of the cellular elements will predominate. The possible types of fibers are referred to as elastic, reticular or collagenous. The cells are, according to Copenhaver and Johnson (1958): fibroblasts, histiocytes, plasma cells, mast cells and wandering cells from the blood. The histiocytes have been proven identical with the clasmatocytes referred to earlier by Ellenberger and Trautmann (1921).

In normal tendinous tissue, only fibroblasts and white collagenous fibers are present. The fibers are all arranged longitudinally and form aggregations or bundles composed of several individual fibers bound together by ground substance. The cells are arranged surrounding these fiber bundles so that they appear stellate on cross section and stretched out on longitudinal section. These permanent residents of tendinous tissue are variously referred to as tenoblasts or tenocytes, but are in fact no different from fibroblasts anywhere else. They have the capability of producing tropocollagen which will ultimately polymerize to collagen. Copenhaver and Johnson (1958) state that an individual molecule of tropocollagen is 2600–3000 Å long and 15 Å wide. They link together in a staggered fashion with an average periodicity of 640 Å and this creates the cross striations seen in the individual collagen fibers.

This neat and orderly arrangement of tendon tissue is, of course, completely destroyed by injury, infection or surgery. Fibers will be interrupted, and cells destroyed; and the entire structure will be called upon to repair the damage. It was the purpose of the microscopic examinations presented here to discover what sort of response occurred when tendinous tissue was transplanted into the superficial flexor tendon of a horse. This was done preparative to eventually being able to replace traumatically damaged or degeneratively changed tissues in clinical cases of tendinitis or tendon rupture.

It was important to know what the long term effects of this kind of tendon transplantation were. Many previous authors [2, 7, 13, 16, 17, 19, 24, 32, 35, 42, 45, 46, 52] have studied the step by step revascularization of transplanted tendinous tissues from a few days up to 3–4 weeks. New ingrowth of blood vessels and the fibroblastic activity surrounding the new tissues may be observed as the acceptance of a graft gradually takes place. Tendon tissue appears to be hardy and allows itself to be moved about with relative impunity.

In this study, the initial acceptance was not the foremost consideration, but rather the actual survival of the graft as tendon tissue over a longer period of time, and its eventual integration into the recipient structure. No sections presented here were taken earlier than 4 weeks postoperatively and the eldest were 4 months old.

In that all transplants were accepted and well integrated in the surrounding tendinous tissue, no attempt was made to differentiate histologic response or to qualify acceptance according to age or sex of the animal involved.

Histologic sections were cut 6 microns thick and stained with hematoxylin and eosin, periodic acid-Schiff and Van Gieson's stain. No advantages over the

H and E technique were seen and later sections were prepared using this method exclusively. Preparatory to the material to be presented in a later paper, microangiography was performed in some of the animals. This resulted in a somewhat exaggerated prominence of the dilated and contrast medium¹ filled vessels in the histologic preparations.

Under low power, the impression gained of the recipient-transplant combination is one of a normal tendon with a basophilic staining central core. A generalized fibroplasia is seen surrounding the structures and running in channels between the transplant and the recipient tendon (see Fig. 16). At the ends of the transplant, streams of fibroblasts may be seen entering the tendon substance between the individual fiber bundles and coursing longitudinally toward the opposite end (see Fig. 17). Blood vessel anastomoses are seen between capillaries of the paratenon and those located within the transplant itself (see Fig. 18).

Upon closer inspection, the relative basophilia of the transplant is seen to be due to a predominance of nuclei in this region (see Fig. 20). The nuclei are those of new fibroblasts that have entered the field to repopulate the transplanted tendon. The recipient tendon as well becomes more cellular when compared with a normal, non-operated specimen (see Fig. 21). The cellularity of the flexor tendon is especially increased in those areas adjacent to the transplant or directly in contact with the paratenon.

As seen in the illustrations, this cellular and blood vessel invasion of the transplant is most marked in the four week old sections. As the tissue matures, its cellularity decreases and the remaining fibroblasts gradually take on the thin, elongated form and evenly spaced arrangement of tenocytes. A point is reached around the four month mark, where the cellularity of the transplant is about the same as that of the recipient tendon. The distinct channels of fibroblasts disappear and the junction zone between recipient and transplant becomes smooth and uninterrupted.

The operative procedure described in this report was no exception to the rule that tendon surgery is fraught with the danger of postoperative adhesions. In those cases where hemostasis was inadequate or drainage of the

¹ Micropaque - Damancy & Co. Ltd., Slough, Buckinghamshire, England.


Fig. 16. ($\times 50$) A section taken sagittally through the recipient - transplant combination shows, from left to right, fibroblastic proliferation of the paratenon, the more cellular than usual nature of the recipient tendon, and the tendon graft flanked by the channels of invading fibroblasts. (Four weeks post-op.)

Fig. 17. ($\times 130$) Streams of fibroblasts are seen invading the transplant at its proximal and distal ends. The tendon fibers are driven apart and appear as wavy, finger-like projections. (4 weeks.)

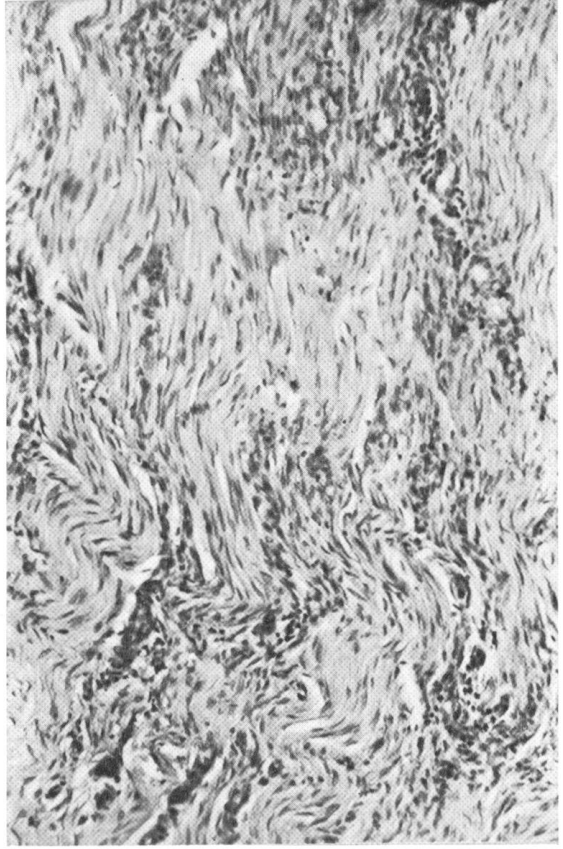
Fig. 18. ($\times 50$) Anastomoses are seen between blood vessels of the paratenon (right) and those within the substance of the transplant. The anastomotic vessels cross directly the tissue of the recipient tendon. (4 weeks.)

Fig. 19. ($\times 130$) The channel of fibroblasts surrounding the transplanted tissues supplies new tenoblasts and angioblasts necessary for the future well-being of the graft. (4 weeks.)

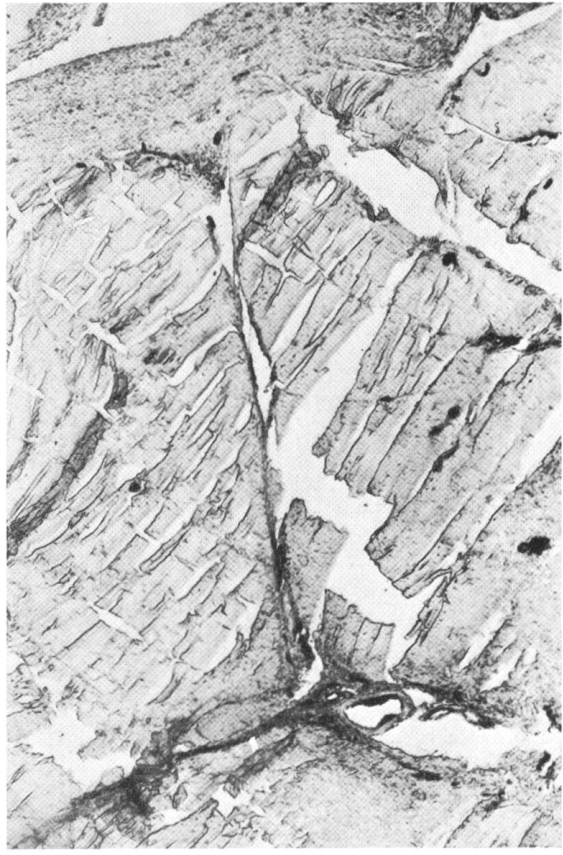16



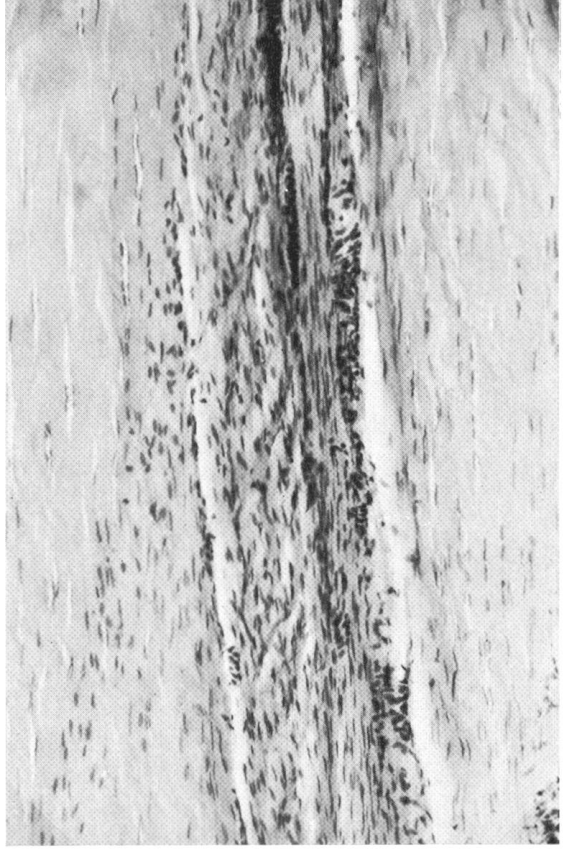
17



18



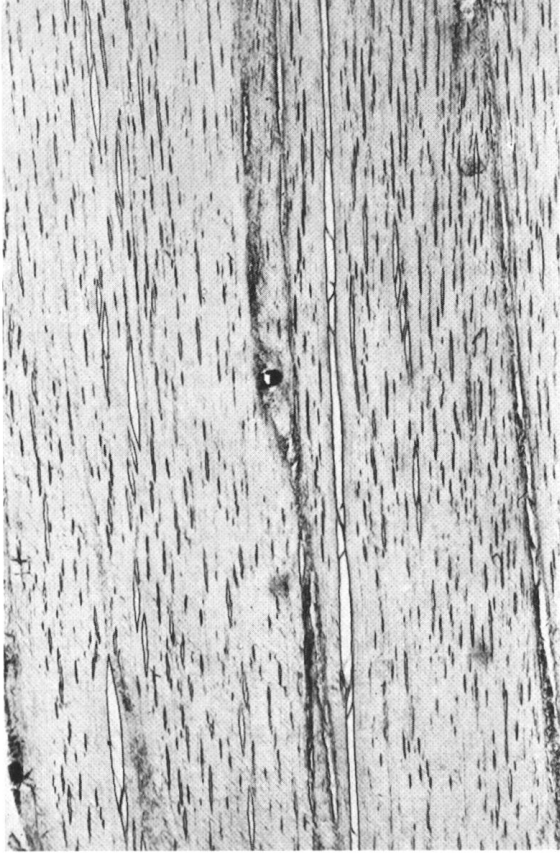19



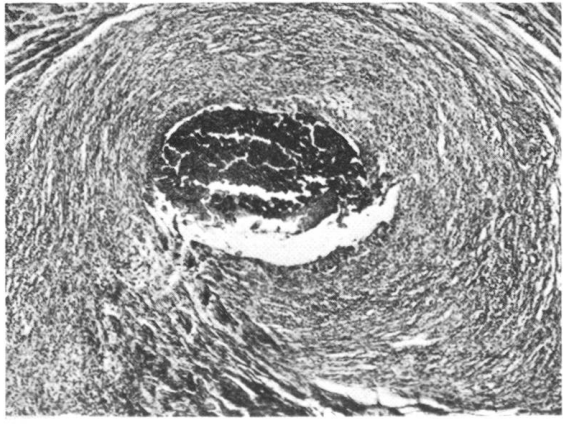
20



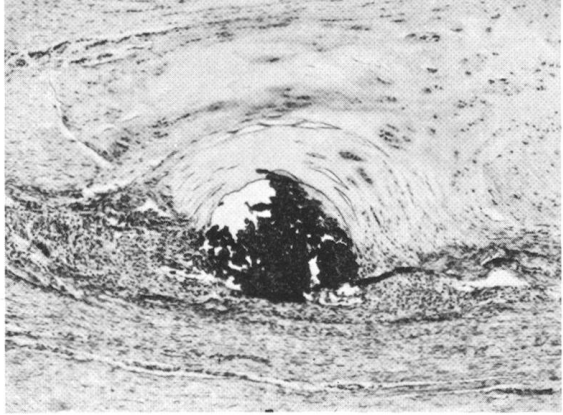
21



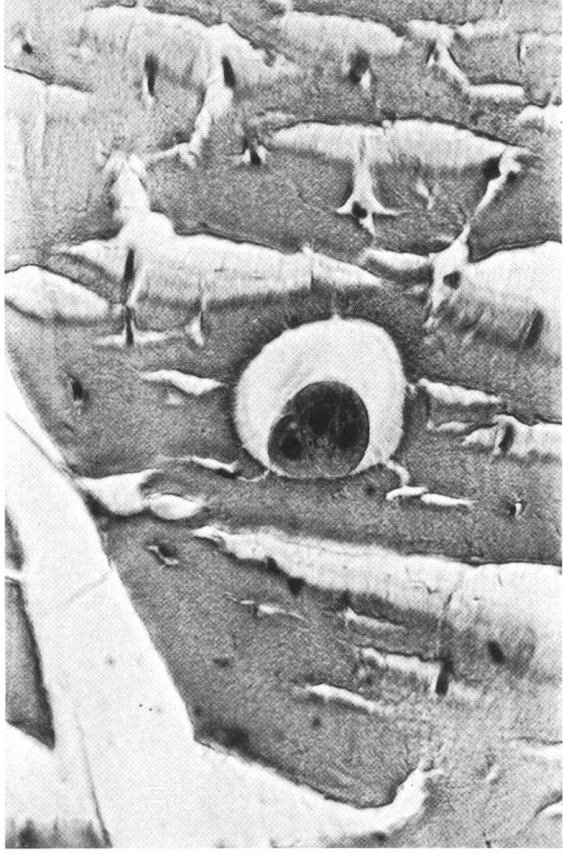
22a



22b



23



operative site suboptimal, marked proliferation of the fascial elements surrounding the tendons occurred. Microscopically, the paratenon was thickened to many times its normal dimensions and intimately adherent to the flexor tendon. In later cases, these problems were circumvented and the histologic appearance of the paratenon remained that of a thin layer of connective tissue rich in fibroblastic activity (Fig. 16 left). Histologic preparation was facilitated in that the tendon and its transplant were much easier to isolate when they were not encased in heavy granulations.

The siliconized silk suture material¹ employed in earlier cases was abandoned in favor of the lighter teflon material now recommended. This decision was based upon the marked reaction of the tissues to the former in spite of the manufacturer's claims that the silicone coating effectively prevented so-called stitch granulomas (Fig. 22a). Teflon sutures are well tolerated by equine tissue causing virtually no inflammatory reaction whatsoever (see Fig. 22b).

An interesting sidelight was presented by the cartilage metaplasia observed on several occasions. It pointed up the variable destiny of the primitive bradytrophic tissues being worked with. Apparently as a result of cellular anoxia or hypoxia, the versatile fibroblasts would revert to a cell type with a slower metabolic rate, the chondroblast. In this work, the hypoxic conditions were provided either by relative distance from the newly forming blood supply, as in the center of the transplant (Fig. 23), or by the tourniquet action of a suture placed in the tendinous tissue (see Fig. 22b right).

Discussion

For the sake of clarity, the "Discussion" has been divided into seven sections, corresponding to the seven major steps in the surgical procedure involved.

¹ Silk - Sterile Catgut Gesellschaft, Neuhausen.

Fig. 20. ($\times 50$) At 4 months postoperatively, a smooth junction is seen between transplant (above) and recipient (below). The transplant is recognizable by its wavier (newer) collagen fibers and its greater relative cellularity.

Fig. 21. ($\times 50$) A normal, non-operated superficial flexor tendon has very few tenoblasts. This microphoto of a normal tendon is presented for purposes of comparison with Fig. 20.

Fig. 22a. ($\times 50$) A siliconized silk suture is seen to evoke a substantial tissue reaction to its presence in equine tendon.

Fig. 22b. ($\times 50$) By comparison, a teflon suture is relatively inert. Note the cartilage metaplasia of the tendon tissue within the confines of the suture. This presumably is the result of the conditions of pressure and hypoxia prevailing at that location.

Fig. 23. ($\times 545$) Islands of cartilage metaplasia may be observed within the substance of the transplant. They are most common in the central core. Here, tenocytes have changed to chondrocytes and formed a lacuna.

1. Preoperative considerations

That this surgery must be performed under aseptic conditions should go without saying. The inclusion of any tissue, even if it originates from the same individual (i.e. autografting) into an area to which it is foreign, requires optimal conditions in the new milieu if the procedure is to be successful.

Minimal requirements for aseptic surgery in the equine are:

- (1) Shaving of the hair of the operative site to at least 1/20 mm.
- (2) Scrupulous scrubbing and disinfection of the operative site. The entire leg is prepared up to a point above the level of the carpus. The surgical scrub disinfectant contains povidone iodine¹, found by Close et al. (1964) to be extremely effective as a presurgical surface disinfectant.
- (3) Scrubbing and disinfection of the surgeon's hands and arms with povidone iodine.
- (4) Sterile rubber gloves.
- (5) Sterile long-sleeved operating gown.
- (6) Face mask and cap.
- (7) Draping of the patient so as to cover the entire body.
- (8) Sterile draping of the operative field to the incision site.

In addition, consideration should be given to the type of postoperative fixation to be used. If the type support bandage resembles that described later in this report, the horse should receive a wooden wedge applied to the volar surface of the hoof before he is brought to the operating theater. In the adult horse, the wedge should be 10–12 cm high at the heels tapering to ca. 1 cm in the toe region.

Provisions for accurate hemostasis should be included in the preparations for surgery, the ideal being an electrosurgical unit² sterilely draped and placed conveniently relative to the operative field.

2. Selection of a transplant

In 1969, Micheletto suggested the use of autogenous fascia lata in the repair of the flexor tendons in the horse. As cited above, this sort of work had already been done in dogs by Rehn (1914). A phase of remodelling of the fascia fibers was necessary to recreate the histological appearance of normal tendon. Heavy scarring and the attendant postoperative adhesions were noted to be inherent disadvantages of the technique. In an attempt to eliminate or at least minimize these pitfalls, we decided to take true tendon tissue from the start. Henze and Mayer's (1915) classic work on the substitution of various tissues and synthetic materials for the flexor tendons in man substantiates the soundness of this decision.

¹ Betadine – Purdue Frederick Co., Yonkers, N. Y., U.S.A.

² Blendtome – The Birtcher Corp., Los Angeles, Calif., U.S.A.

Based upon the observations made in the clinical treatment of deep wounds of the metacarpus, the premise that a horse's gait remained unaffected by the loss of the action of the lateral digital extensor seemed justified. Silbersiepe [6] points out this relative dispensability of the lateral extensor tendon in his discussion of the surgical treatment of injuries to the metacarpal region.

As a donor tendon for transplantation into the superficial flexor, the lateral digital extensor is ideally located to be included in one surgical field at operation. Its shape resembles that of a narrow ribbon, thus making it well suited to inclusion in a tendon having the contours of the superficial flexor in midmetacarpus. The loose-packed "stringy" fibers of the lateral digital extensor (LDE) present ready-made pathways for the ingrowth of new blood vessels and fibroblasts.

Microscopically, this loose packed nature is seen to be carried down to the level of the individual fiber bundles. The LDE tendon does not have a rich vascular supply and is relatively sparsely populated by tenocytes. Such a relative paucity or indeed the complete absence of tenocytes is considered by Seiffert (1967) to be of great importance to the prevention of postoperative adhesions surrounding a tendon transplant. Transplanted tenocytes die, and the resultant cellular debris must be disposed of. This disposal activity can only be accomplished by the ingrowth of blood vessels, which predicates a proliferation of granulation tissue. This fibrous tissue may, in turn, compromise the mobility of the tendon into which it has grown.

The secret of successful tendon surgery is to obtain enough of a proliferation of granulation tissue to supply sufficient blood vessels to the new tissues without afterward becoming a hindrance to motion.

Colville (1969) states that the underlying reason for postoperative adhesions following tendon transplantation is the new tissues' demand for a blood supply. This demand is answered by a proliferation of fibrous tissue. The strength of the demand is determined by the number of cells originally present and their distance from the existing vascular tree. Superficial layers can be nourished by plasmatic imbibition, deeper ones must be supplied by new capillaries.

The fact that necrosis of a transplanted lateral digital extensor tendon did not occur in any of the horses in this series would indicate that its morphology makes it well adapted to surviving the rigors of the grafting procedure described.

3. Preparation of the transplant

In order to prevent drying out and a denaturation process, the freshly excised tendon is wrapped in a moist gauze sponge. The importance of not overwetting the transplant is stressed by Clodius (1970), who advises against actually submerging the tissue prior to transplantation. Total immersion will tend to cause an edema-like swelling and works therefore disadvantageously

to future revascularization. Antibiotics may be added to the fluid used to moisten the sponge as a precautionary measure.

Any extraneous pieces of fascia clinging to the transplant will result in an increased call on the paratenon to proliferate, and are therefore to be trimmed away as accurately as possible. The importance of this point is stressed by Van der Meulen (1969), who takes great pains to remove all of the paratenon from his tendon-mesotenon transplant units.

4. *Incisions*

The convenience of having the incision for the removal of the transplant located on the same extremity as that necessary for the exposure of the recipient is pointed out by Snow (1968). He uses the ulnar half of the extensor digiti quinti proprius tendon for flexor tendon grafts in man. Preparation of the operative site is simplified and the time consumed in the actual surgical procedure reduced. The postoperative treatment consisting of cleansing and dressing the wounds is similarly facilitated.

The location of the skin incision over the superficial flexor was determined based upon its relation to the lateral extensor and the desire not to have the incisions in the skin and in the flexor tendon coincide with one another. The importance of this seemingly fine point is stressed repeatedly by such classical tendon surgeons as Sterling Bunnell (1918) and Erich Lexer (1927). The posterolateral approach to the superficial flexor provides good exposure and permits the careful resection of any adhesions between it and the deep tendon.

The superficial flexor tendon itself is incised along its posterior surface as in the Åsheim procedure. (See under "Review of the Literature".) This permits good exposure of the interior of the tendon for the removal of any hematomata or necrotic foci and paves the way for the further preparation of the transplant's tendinous bed. The major blood supply to the flexor tendon reaches it along its anterior, concave surface (Strömberg, 1971). This supply is left intact by the median longitudinal incision placed on the posterior surface. That the normal circulation of a tendon remains as undisturbed as possible by a plastic procedure is considered of utmost importance by Lindholm (1959) who developed his operation for the repair of ruptured Achilles tendon in man keeping its similar, anteriorly located, blood supply foremost in mind.

The further incisions in the flexor tendon were developed for the purpose of providing a smooth bed or capsule for the lateral extensor tendon about to be implanted.

Through the execution of this compound incision, the superficial flexor may be turned inside out without markedly disturbing either tendon fibers or the normal blood supply. The advantages as regards the removal of possible degenerative or hemorrhagic tissues have already been stated. The more necrotic and hemorrhagic debris removed from a clinical case, the milder the

inflammatory reaction and the fewer the postoperative adhesions. The sizing of the cavity is made easy by merely comparing the bulk of the transplant to that of the incised recipient tendon. The superficial flexor is incised to such an extent that the ends of the transplant lie securely within healthy tissues above and below the injury, and the transplant is trimmed to the proper length. There should be no wrinkling of the transplant (indicating an undersized cavity), nor should it have the freedom to slide about within its new vestments.

All incisions should be made exercising the utmost respect for the tissues being invaded (Bunnell, 1921). Less trauma inflicted means less trouble with postoperative fibrosis. Sharp dissection should be employed exclusively. The scalpel blade with which the skin was incised should be discarded and a new one used for the deeper incisions.

The good surgeon's "unswerving attention to apparently meaningless detail" will be amply rewarded.

5. Postoperative drainage

The importance of this part of tendon surgery cannot be overemphasized. As pointed out by Schink et al. (1968), any injury to a tendon results in swelling and local exudation. If this exudate is not transported away from the operative field, the result may be a tendon that is cosmetically and functionally worse than it was prior to surgery. Nicolle (1969) also stresses the importance of not allowing tissue fluids to collect in the wound in the prevention of adhesions.

The old "gravitational" method of conducting exudates and blood away from the surgical field by means of gauze setons or rubber tubes has been found inadequate for the demands placed upon it by tendon surgery in the equine. Secretion often significantly exceeds the drain's ability to conduct, and accumulation results. This may be further complicated by fibrinous proliferations at the drainage opening which render the passive flow mechanism involved totally impotent.

A simple apparatus¹ similar to that described for use in the horse by Boyd and Joyce (1971) has been used to great advantage. It consists of an accordion-like bellows attached to a plastic tube (Fig. 24) imbedded in the surgical wound. The distal end of the tube has many collateral openings for the influx of wound secretions so that stopping-up is rarely a problem. The bellows is light and durable and may readily be attached to the animal's body by means of a girth or a martingale-type arrangement. It has a capacity of up to 300 ml of fluid. Heparinization of the conducting tube is a good idea in view of the relatively great lengths of tubing sometimes made necessary by taller horses. Drainage of this sort is routinely left in position

¹ Protovac - Protec AG, Bern

4 to 6 days postoperatively and has never caused any animal upon which it has been used any apparent discomfort. Its removal independent of the surrounding fixation bandages is accomplished in a matter of seconds.

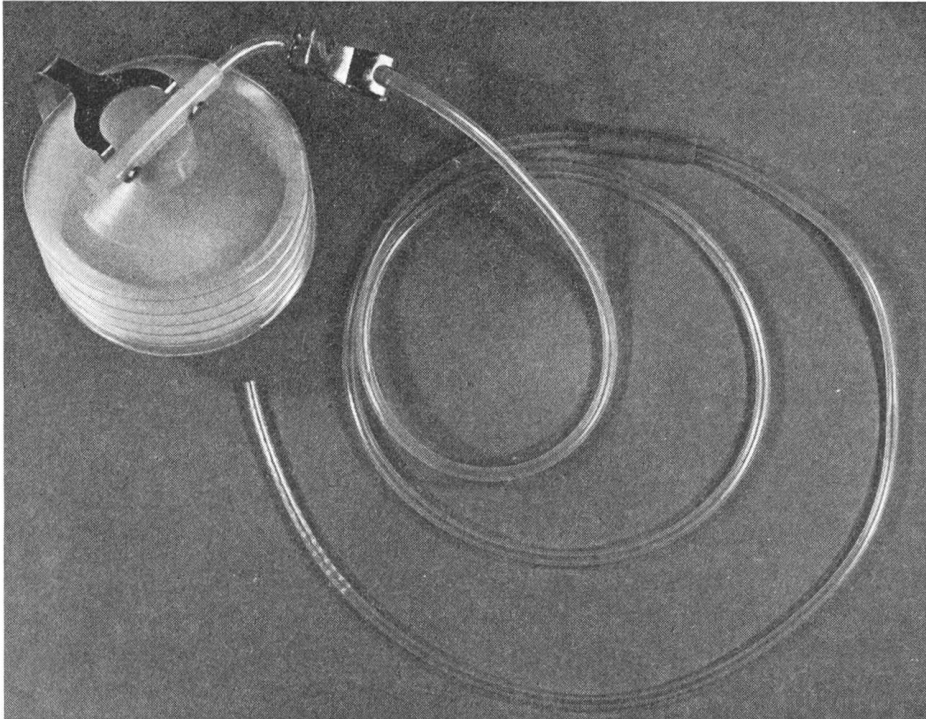


Fig. 24. The suction drainage apparatus used in connection with this surgery consists of a Redon drainage tube, a conducting tube and a spring-loaded bellows device which places the whole system under negative pressure. The entire appliance is light in weight and is carried by the animal without hindering his normal movements.

6. Sutures

As mentioned above in the section entitled "Histology", the siliconized suture material used in earlier cases was later replaced by the less reactive material, teflon. All sutures are of the atraumatic type, having fine, swedged-on, reverse cutting edge needles.

The tissues are adapted exercising the same respect and avoidance of traumatic insult with which they were incised.

The edges of the split in the recipient tendon are approximated using 4-0 teflon in an interrupted pattern, placing just enough sutures to bring the lips of the wound gently over the transplant. Excess tension is to be avoided in tying the individual sutures so that the blood supply to the tissues included within the loop of suture material will be compromised as little as possible.

The fascia or "gliding tissue", as it is referred to by Peacock (1964), is closed with the same material as the tendon, this time using a simple

continuous pattern. The drainage tube is included beneath this layer and brought out through a stab incision in the skin ca. 4 cm proximal to the proximal end of the skin incision. No particular fixation of the tube in the wound is necessary.

The skin is closed using an interrupted Donati pattern, employing 3-0 polyamide¹. This suture pattern can withstand a good deal of tension occasioned by postoperative swelling without cutting into the wound edges. The fact that it does not pierce the skin on one side of the incision means that the superficial circulation near the incision remains intact and can participate in the healing process.

7. Postoperative fixation

Experience has shown the importance of fixation or at least relatively reduced tension in freshly operated tendons. This has already been mentioned in the "Review of the Literature" in connection with the healing process vs. tensile strength as presented by Mason and Allen (1941).

Åsheim (1964), in describing his technique for tendon splitting in horses, recommends plaster of Paris bandages for eight weeks postoperatively. Goldman et al. (1969), working with the Achilles tendon in man, recommend cast fixation with the foot in equinus for a period of two to three weeks. Subsequently they encourage "protected ambulation" and activity. Nicolle (1969) immobilizes his patients' hands twelve to fourteen days postoperatively following grafting procedures on the flexor tendons.

The fixation of a horse's limb in a position that provides for the relaxation of tension on the flexor tendons and the maintenance of this position over a period of several weeks is not an easy problem to solve. The bandage about to be described has proven capable of fulfilling these rather strenuous requirements, and is in this author's opinion practical, safe and easy to apply.

The fixation devised for this operation, but useful for others as well, consists in part of the well-known combination of plaster of Paris and fiberglass² (see Fig. 15). This in itself is no innovation but the method of application includes a few tricks that vastly improve the final product.

The main objection to the plaster-fiberglass combinations as heretofore propagandized, was that the plaster within the shell of the fiberglass did not dry. The exchange of moisture between the plaster and the atmosphere was seriously inhibited by the interposition of the relatively air-tight fiberglass layer. There remained therefore in contact with the wound, a wet soggy mass not conducive to the healing process trying to go on under it. The plaster had very little strength in this condition and could contribute only minimally to the support function of the bandage.

Plaster bandages alone disintegrated when subjected to the rigors of stall

¹ Supramid - Sterile Catgut Gesellschaft, Neuhausen

² agv Verband - Ciba/Geigy, Basel.

life and were of questionable value in terms of fixation within eight to fourteen days. This was especially true if the foot was placed in a non-physiologic position.

One solution was the inclusion of metal implants to strengthen the structure. However, this often resulted in an unsightly unwieldy apparatus on the end of the animal's leg. A better solution for the fixation of a freshly operated extremity had to be found.

Padding with either foam rubber or orthopedic felt is necessary at two locations: over the coronary band and directly below the carpus. Otherwise the leg is merely covered with a single layer of stockinette.

The leg is brought into a position whereby the digital joints assume a slight ventroflexion. This can be most easily effected and maintained by the application of a tourniquet above the carpus. The tension produced in the flexors through this appliance will bring the foot into the desired position and hold it there. As mentioned earlier, in certain heavier animals, one may elect to apply a wooden wedge to the heel.

The plaster bandages are applied in the usual fashion, being careful, especially in the inner layers, not to place any tension on the bandage material but rather to sculpt it to the contours of the leg. Wire embryotomy saws are included medially and laterally, and the cast is sawed open about fifteen minutes following its application. This entire procedure is carried out *preoperatively* beginning on the horse immediately after he has been placed in lateral recumbency.

The cast may now be laid aside and will have a chance to dry out and harden during the ensuing operation. The drying process may be expedited by placing the cast in a warm oven or in the usual "drying cage" present in many small animal departments.

Postoperatively, the wound is dressed and gauze bandage impregnated with zinc oxide ointment is applied to the leg. A new stockinette is applied and the plaster shells are refitted to the leg and held in position with adhesive tape.

The outside of the plaster cast is now reinforced and waterproofed by the application of the fiberglass bandage. The fiberglass can be made to conform nicely to the outer contours of the plaster by applying an old elastic bandage to its surface and placing it under slight tension.

This fixation bandage has proven strong enough to withstand the torments of horses up to 650 kg. The plaster is in good condition after up to four weeks of fixation and the wound healing is in no way placed at a disadvantage.

Such a bandage was applied to the animal from which the radiograph in Fig. 15 was made. The collateral splits in the plaster are visible. The size relationships are perhaps better seen in Fig. 15a.

Upon removal of the fixation, the sutures are removed and the surgical wound redressed. The elevation of the heels by means of the wooden wedge

is also removed. A well padded, snug-fitting elastic bandage is applied and left in position for another two weeks. At this time it is replaced by a lighter stall bandage.

The animal is rested a further two weeks. After this, he is given exercise on the hand for one month, and light work beginning with gentle exercise at the walk and gradually increasing in intensity over a period of 12 weeks.

Conclusion

Tendon transplantation as presented here offers a new method of treating the partially degenerative, partially traumatic disease of tendinitis in horses. The technique aims at reestablishing a normal cross-section of functional tendinous tissue within the framework of the damaged original structure. The macroscopically apparent success is borne out histologically, in that the transplanted tissue remains tendinous in nature and forms an intimate bond with the recipient flexor tendon. Microangiography, a relatively new procedure in veterinary medicine, proved applicable to the examination of newly transplanted tendons and presented an additional method of studying the response of the blood vascular system to the presence of new tissues. The results of these studies will be presented in a further paper.

It is obvious that tendon surgery in general and tendon transplantation in particular should not be undertaken lightly in the equine or any other species. The equipment and knowledge at the disposal of the modern veterinarian should, however, render the difficulties inherent in such surgery only temporary.

Summary

A technique for the transplantation of autologous tendon tissue in the horse is described whereby the lateral digital extensor tendon is implanted into the core of the superficial flexor. The histologic fate of the transplanted tissues is presented following the course of events involved in acceptance from 4 weeks to 4 months postoperatively.

Zusammenfassung

Es wird eine Methode der autologen Sehnen transplantation beim Pferd beschrieben, wobei die Sehne des Musculus extensor digitorum lateralis in die oberflächliche Beuge-sehne implantiert wird. Die mit dem Einwachsen des Transplantates verbundenen histologischen Vorgänge von 4 Wochen bis 4 Monate postoperativ werden präsentiert.

Résumé

Une méthode de transplantation autologue de tendons chez le cheval est décrite. Le tendon du muscle Extensor digitorum lateralis est implanté dans le tendon fléchisseur superficiel. Les processus histologiques relatifs à l'intégration du transplant dans le tissu récepteur sont décrits pour la période de 4 semaines jusqu'à 4 mois après l'opération.

Riassunto

Si descrive un metodo di trapianto autologo di tendine nel cavallo. Il tendine del muscolo Extensor digitorum lateralis è collocato come trapianto nel tendine flessore super-

ficiale. Sono presentati i processi istologici relativi all'integrazione del trapianto nel tessuto ricettore, per il periodo di 4 settimane a 4 mesi dopo l'intervento.

Literatur

- [1] Ammann K. and Fackelman G.: Autologe Sehnen transplantation beim Pferd. Schweiz. Arch. Tierheilk. 114 (1972): 8. - [2] Andreef I., Dimoff G. and Metschkarski R.: A comparative study on transplantation of autogenous and homogenous tendon tissue. Acta orthoped. scand. 38 (1967): 35. - [3] Åsheim A.: Surgical treatment of tendon injuries in horses. JAVMA 145 (1964): 447. - [4] Åsheim A. and Knudsen O.: Percutaneous tendon splitting. Proc. 13th AAEP Congr. (1967): 255. - [5] Backes G. and Skarda R.: Die Verbesserung der Lungenventilation mit dem Respirator Mark 9 während der Allgemeinanaesthesie beim Pferd. Schweiz. Arch. Tierheilk. 114 (1972): 13. - [6] Berge E. and Müller H.: *Silbersiepe-Berge Lehrbuch der speziellen Chirurgie für Tierärzte und Studierende*. Ferdinand Enke, Stuttgart 1965. - [7] Berglung L.: Vascular reaction in tendon healing. Angiology 21 (1970): 375. - [8] Berkin C.R.: Effects of cortisone on the healing of tendons in rabbits. Proc. Roy. Soc. Med. 48 (1954): 610. - [9] Boyd C.L. and Joyce J.R.: A closed system negative pressure surgical drain. Southwest. Vet. 24 (1971): 67. - [10] Bunnell S.: Repair of tendons in the fingers and description of two new instruments. Surg., Gynec. & Obstetr. 26 (1918): 103. - [11] Bunnell S.: An essential in reconstructive surgery - atraumatic technique. Calif. State Journ. Med. 19 (1921): 204. - [12] Bunnell S.: *Surgery of the Hand*. J.B. Lippincott, Philadelphia 1944. - [13] Cameron R.R., Conrad R.N., Sell K.W. and Latham W.D.: Freeze-dried composite tendon allografts: an experimental study. Surgery 47 (1971): 39. - [14] Clodius L.: Personal communication (1970). - [15] Close A.S., Stengel B.F., Love H.H., Koch M.L. and Smith M.B.: Presurgical disinfection with povidone iodine. Am. J. Surg. 108 (1964): 398. - [16] Colville J., Callison J.R. and White W.L.: The rôle of the mesotenon in tendon blood supply. Plast. and Reconstr. Surg. 43 (1969): 53. - [17] Conway H., Smith J.W. and Elliot M.P.: Studies on the revascularization of tendons sutured by the silicone rod technique. Plast. and Reconstr. Surg. 46 (1970): 582. - [18] Copenhaver W.M. and Johnson D.D.: *Bailey's Textbook of Histology*. Williams and Wilkins, Baltimore 1958. - [19] Edshage S., Goldie I. and Niebauer J.J.: Tissue surrounding grafted tendons in dogs. Acta orthoped. scand. 41 (1970): 292. - [20] Ellenberger W. and Trautmann A.: *Grundriss der vergleichenden Histologie der Haussäugetiere*. Paul Parey, Berlin 1921. - [21] Forssell E.G.: Sehnenleiden, in *Tierheilkunde und Tierzucht* ed. Stang, V. and Wirth, D. Urban und Schwarzenberg, Berlin und Vienna 1931. - [22] Garner L.: Osseous metaplasia, a complication of local corticosteroid treatment in the horse. Nord. Vet. Med. 17 (1965): 516. - [23] Goldman S., Linscheid R.L. and Bickel W.: Disruptions of the tendon Achilles. Mayo Clinic Proc. 44, (1969): 28. - [24] Gresham R.B.: Freeze-drying of human tissue for clinical use. Cryobiology 1 (1964): 156. - [25] Henze C.W. and Mayer L.: Experimentelle Untersuchungen über Sehnenverpflanzungen und seidene Sehnen mit besonderer Berücksichtigung der Verhinderung von Verwachsungen. Zeitschr. f. orthoped. Chir. 35 (1915): 867. - [26] Ketchum L.D.: The effects of triamcinolone on tendon healing and function. Plast. and Reconstr. Surg. 47 (1971): 471. - [27] Lexer E.: Die Verwertung der freien Sehnen transplantation. Arch. f. klin. Chir. 98 (1912): 818. - [28] Lindholm Å.: A new method of operation in subcutaneous rupture of the Achilles tendon. Acta chir. scand. 117 (1959): 261. - [29] Mason M.L. and Allen H.S.: Rate of healing in tendons. Experimental study of tensile strength. Ann. Surg. 113 (1941): 424. - [30] Micheletto B.: Sostituzione segmentaria di tendini con autoinnesti liberi di fascia lata. Ricerche sperimentali. Ann. Fac. Med. Vet. Torino 18 (1969): 1. - [31] Milne F.J.: Thoughts and observations on counter-irritation in horses. Dissertation Zürich 1960. - [32] Nicolle F.V.: A silastic prosthesis as an adjunct to flexor tendon grafting: an experimental and clinical evaluation. Brit. Journ. Plast. Surg. 22 (1971): 56. - [33] Nilsson G.: Tendon splitting for chronic tendinitis in horses. Mod. Vet. Pract. 52 (1971): 56. - [34] Peacock E.A. Jr.: Fundamental aspects of wound repair relating to the restoration of gliding functions after tendon repair. Surg., Gynec. and Obstetr. 119 (1964): 241. - [35] Peacock E.A. Jr.: Physiology of tendon repair. Am. Journ. Surg. 109 (1965): 283. - [36] Potenza A.D.: Critical evaluation of flexor tendon healing and adhesion formation within artificial digital sheaths. J. Bone and Jt. Surg. 45-A (1962): 1217. - [37] Proctor D.L.: Tendinitis, in *Equine Medicine and Surgery*, Amer. Vet. Publications Inc., Santa Barbara (1963): 728. - [38] Pulvertaft R.G.: Repair of tendon injuries in the hand. Ann. Roy. Coll. Surg. 3 (1948): 3. - [39] Rehn E. and Miyanchi W.: Zur Frage des Ersatzes grosser Sehnen defekte. Arch. klin. Chir. 105 (1914): 1. - [40] Rehn E.: Zur Frage der Transplantation, Regeneration und Ortseinsetzenden Metaplasie.

Arch. klin. Chir. 112 (1919): 622. – [41] Roberts E.J.: Lecture. The surgery of tendons. 8th Ann B.E.V.A. Congr., Cambridge 1969. – [42] Rydell N.: Decreased granulation tissue reaction after installation of hyaluronic acid. Acta orthoped. scand. 41 (1970): 307. – [43] Schenk R.: Lecture. ASIF Congress, Davos 1971. – [44] Schink W., Brückle H. and Gehlen W.: Eine Stellungnahme zur Sehnenchirurgie und zur thermischen Kontraktion von Sehnengewebe. Monatschr. f. Unfallheilkunde 71 (1968): 607. – [45] Seiffert K.E.: Biologische Grundlagen der homologen Transplantation konservierter Bindegewebe. Hefte Unfallheilkunde 93 (1967): 1. – [46] Seiffert K.E.: Experimentelle Untersuchungen zum Längenwachstum transplantierte Sehnen. Med. Monatsschr. 24 (1970): 153. – [47] Sevelius F.: Surgical treatment of bowed tendons and strained suspensory ligaments by Åsheim's method. Proc. 3rd Ann. Congr. B.E.V.A. (1964): 28. – [48] Skoog T. and Persson B.H.: An experimental study of early healing of tendons. Plast. and Reconstr. Surg. 13 (1954): 384. – [49] Snow J.W.: Ulnar half of the extensor digiti quinti proprius for flexor tendon grafts. Plast. and Reconstr. Surg. 42 (1968): 603. – [50] Smith J.W.: The blood supply of tendons. Am. Journ. Surg. 190 (1965): 272. – [51] Strömberg B.: The normal and diseased superficial flexor tendon in race horses. Acta radiolog. Suppl. 305 (1971). – [52] Van der Meulen T.C.: Healing of tendons. Ann. Chir. Plast. 14 (1969): 168. – [53] Wheat J.D.: The use of hydrocortisone in the treatment of joint and tendon disorders in large animals. JAVMA 127 (1955): 64.

REFERATE

Hysterektomie beim Rind. Von H.P. Polland. Wiener Tierärztl. Monatsschrift 60/1, 21–27 (1973).

Indikationen zu dieser Operation sind: Unmöglichkeit, den post partum vorgefallenen Uterus zu reponieren, und Verletzung der puerperalen Gebärmutter, entweder wenn sie prolabiert ist oder in situ. Der Verfasser hat 60 Amputationen erlebt. Günstige Umstände sieht er in der robusten Verfassung des Höhenviehs in seiner Praxis und in vor der Operation durchgeführter Kreislaufbehandlung. Was er zu den in Lehrbüchern mehrfach besprochenen Operationen beitragen möchte, ist folgendes: Vor dem Anlegen der elastischen Ligatur bringt er etwas vor der Mitte der Cervix eine Rebschnur oder eine ähnlich starke Umschnürung an, in Form einer Kastrationsschlinge, zunächst nur locker. Dann geht er mit einer Hand durch eine bestehende oder künstlich erzeugte Uteruswunde bis zur Cervix vor und stößt eventuell im Vorfalle befindliche Darmabschnitte oder die Blase, mitunter auch beides, in die Bauchhöhle zurück. Schwierigkeiten sollen sich dabei nur dann ergeben, wenn die Operation nicht im Stehen oder liegend nicht unter Beckenhochlagerung durchgeführt wird. Die Kastrationsschlinge wird leicht angezogen, so daß sie für die Hand fühlbar wird, erst jetzt wird die Hand bis zur Ligaturstelle zurückgezogen, unter langsamem weiterem Anziehen der Schlinge, die nun über die keilförmig geformte Hand «hinunterrutscht». Erst nach immer wieder erfolgter Kontrolle mit zwei, dann mit einem Finger auf eingestülpte Darmteile wird die Kastrationsschlinge fest angezogen, wiederum unter langsamem Zurückziehen des letzten Fingers. Diese Manipulation erscheint etwas umständlich, sie verhindert aber mit großer Sicherheit das Abschnüren von Eingeweideteilen. Jetzt wird etwa daumenbreit hinter der Rebschnur-Ligatur, anatomisch cranial, eine elastische Ligatur angelegt, am besten ein 4 mm starker Vierkantgummi. Ein starker Perlonfaden, der vor dem Anziehen quer unter der Gummiligatur eingelegt wird, hält die langsam und stark angezogene Ligatur besser fest als ein Knoten. Dieses Anziehen kann 2–3mal wiederholt werden, wodurch ein absolut sicherer Sitz der elastischen Ligatur gewährleistet wird. Jetzt wird die vorher angelegte Kastrationsschlinge durch Darunterschieben eines geknöpften Skalpells langsam aufgemacht. Beim nun folgenden Absetzen des Uterus soll kein Cervixgewebe miterfaßt werden.

Die Arbeit ist sehr ausführlich, mit Literaturangaben und persönlichen Erfahrungen versehen. Wer diese Operation perfektionieren möchte, tut gut daran, das Original zu lesen.

A. Leuthold, Bern