

Ultrastructural modifications of lamb testicle spermatids induced by oestradiol and trenbolone acetate

Autor(en): **Blanco, A. / Méndez, A. / Mozos, E.**

Objekttyp: **Article**

Zeitschrift: **Schweizer Archiv für Tierheilkunde SAT : die Fachzeitschrift für Tierärztinnen und Tierärzte = Archives Suisses de Médecine Vétérinaire ASMV : la revue professionnelle des vétérinaires**

Band (Jahr): **132 (1990)**

Heft 8

PDF erstellt am: **26.05.2024**

Persistenter Link: <https://doi.org/10.5169/seals-592968>

Nutzungsbedingungen

Die ETH-Bibliothek ist Anbieterin der digitalisierten Zeitschriften. Sie besitzt keine Urheberrechte an den Inhalten der Zeitschriften. Die Rechte liegen in der Regel bei den Herausgebern.

Die auf der Plattform e-periodica veröffentlichten Dokumente stehen für nicht-kommerzielle Zwecke in Lehre und Forschung sowie für die private Nutzung frei zur Verfügung. Einzelne Dateien oder Ausdrucke aus diesem Angebot können zusammen mit diesen Nutzungsbedingungen und den korrekten Herkunftsbezeichnungen weitergegeben werden.

Das Veröffentlichen von Bildern in Print- und Online-Publikationen ist nur mit vorheriger Genehmigung der Rechteinhaber erlaubt. Die systematische Speicherung von Teilen des elektronischen Angebots auf anderen Servern bedarf ebenfalls des schriftlichen Einverständnisses der Rechteinhaber.

Haftungsausschluss

Alle Angaben erfolgen ohne Gewähr für Vollständigkeit oder Richtigkeit. Es wird keine Haftung übernommen für Schäden durch die Verwendung von Informationen aus diesem Online-Angebot oder durch das Fehlen von Informationen. Dies gilt auch für Inhalte Dritter, die über dieses Angebot zugänglich sind.

In all treated animals there were only few cell layers (two to four) as in the luteal stage of the normal sexual cycle, but in this case there was complete absence of corpora lutea.

In conclusion the most important findings are represented by the ovarian inactivity associated to the atrophy, or a delayed development of the rest of the genital tract. This hypothesis is supported also by the significant difference between ovarian and uterine weight in treated and control pigs and particularly by the histological findings of the endometrial, cervical and vaginal epithelial structures. The detection of ER was slightly prevalent in treated animals and was consistent with the quantitative investigations described in «Note 1». Although the number of subjects employed in the experiment needs to be increased to better understand and confirm the detected lesions, we assume that they may represent the consequence of long time administration of β -agonists to fattening pigs, which may influence the metabolism of some cell populations of the genital tract, like for example the granulosa cells which are provided of membrane receptors for β -agonists (Hsueh et al. 1984).

References

1. Leizer R. et al. (1988): Tierärztl. Prax. 16, 261-280. — 2. Hsueh A. J. et al. (1984): Endocr. Reviews, 5, 76-127. — 3. Hanrahan J. P. (1987): Elsevier Appl. Sci. Publishers LTD, London, New York. — 4. Fiems L. O. (1987): Ann. Zootech., 36, 271-290.

Dpto. Anatomía, Anatomía Patológica Comparadas. Vet. Faculty. University of Córdoba, Spain

ULTRASTRUCTURAL MODIFICATIONS OF LAMB TESTICLE SPERMATIDS INDUCED BY OESTRADIOL AND TRENBOLONE ACETATE

A. Blanco, A. Méndez, E. Mozos, J. L. Rodríguez, V. Toledo

Oestradiol and trenbolone acetate are commonly used as anabolics in order to improve the yield of stock animals, as well as the appearance and quality of their meat. According to Michel and Beaulieu (1983), these substances act in a direct fashion via specific receptors.

The continuous use of hormones may induce carcinogenesis (Hoffman, 1986). On the other hand, Rao and Chinoy (1984) and Bellido and Gaytán (1985) found the administration of oestrogens in male rats to induce marked testicle atrophy.

Material and methods

The study was carried out on 16 thirty-day-old lambs, in 12 of which pellets were implanted subcutaneously containing 2.5 mg oestradiol and 17.5 mg trenbolone acetate. The other 4 lambs were used as controls (see Table 1).

Results

Lot I: Of the various cells occurring in the seminiferous duct, spermatids are worth mentioning on account of their atypical morphological features. They occurred in small numbers and were located in the central zone of the seminiferous ducts, related by thin peduncles to Sertoli cells; they were spherical to elliptical in shape,

Tab. 1 – summary of results

pig n.	weight of ovary (g)		uterus (g)	pig (kg)	ER-ICA	stage of sexual cycle
	right	left				
TREATED						
1	2.47	2.59	308	140	+	—
2	3.66	3.51	267	127.5	+	—
3	4.32	3.97	187	136	—	—
4	3.30	3.70	280	126	++	—
average weight	3.44	264.5	132.4			
CONTROLS						
5	3.86	4.33	661	134±		metestrus
6	6.77	16.16	583	141—		middle diestrus
7	6	5.72	851	172±		proestrus
8	4.11	6.44	932	165±		middle diestrus
average weight	6.62	765.75	153			

and the electron density of their hyaloplasm and nucleus was quite low. Their nucleus was spherical, with outstanding nucleolus.

Cytoplasmic organellae occurred in small numbers and their mitochondria had elongated shapes. The chromatoid body was quite prominent, with clear signs of fragmentation.

Lot II: Spermatids were more abundant in this group. They were elongated in shape and occasionally binucleate, with outstanding nucleoli.

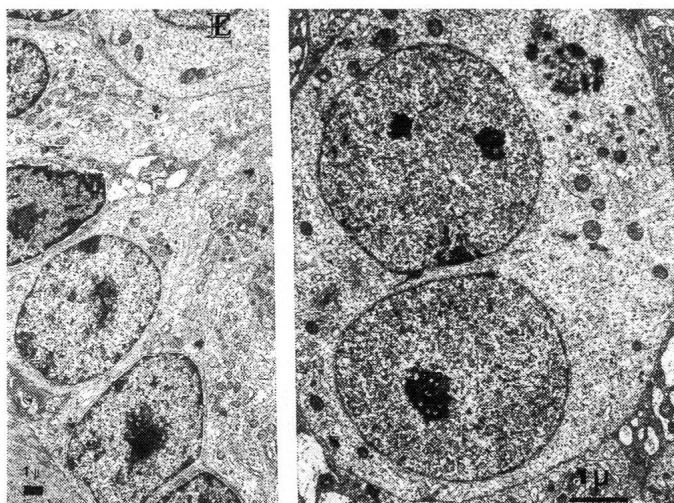
The cytoplasm was clearly seen and the granular endoplasmic reticulum (GER) and particularly the Golgi complex were poorly developed. Like in Group I, mitochondria were elongated in shape; the chromatoid body, fragmented and occasionally related to non-specific vesicles, lay prominently at one of the cell poles, close to the nucleus.

Control group: Neither group showed this type of altered spermatids.

Discussion

The spermatid cells found in the experimental animals were different from those of the control animals in their undifferentiation and even in their binucleate nature, which is indicative of a dysfunction of the seminiferous epithelium, consistent with earlier findings by Wiggins et al. (1980). Occasionally, the experimental animals also showed no connection between their spermatids and Sertoli cells.

Fig. 1. Group I: Seminiferous duct with immature spermatids.
Fig. 2. Group II: Immature binucleated spermatidy with poor developed Golgi complex; fragmented chromatoid body.



The anomalies found in the cytoplasmic organellae prevented spermatozoal development. We want to emphasize the fact that fragmentations in the chromatoid bodies prevented the formation of flagellae.

Div. Experimental Pathology, Inst. Animal Pathology, University of Berne

HYPOTHALAMO-PITUITARY-GONADAL AXIS OF AGED FEMALE RATS. A FUNCTIONAL AND MORPHOLOGICAL STUDY

C. E. Boujon, G. E. Bestetti, M. J. Raymond, G. L. Rossi

Median eminence (ME) and mediobasal hypothalamus (MBH) LHRH and plasma FSH, LH, and progesterone were measured by RIA in young diestrus (age 3 months) and old recurrently pseudo-pregnant (RPP; age 23–24 months) female Long-Evans rats. Lateral ME (LME) LHRH as well as pituitary FSH and LH contents were also evaluated by morphometry and densitometrical immunocytochemistry. Further, by light microscopy we classified and counted the number of ovarian follicles and corpora lutea.

By RIA hypothalamic LHRH, plasma LH and progesterone were similar in the two groups while plasma FSH was higher in old than in young animals.

Dep. Compar. & Experim. Pathology, College of Vet. Med., University of Florida, Gainesville

NATURAL ACANTHAMOEBA INFECTION IN GREYHOUND DOGS

C. D. Buergett, L. R. Harrison, A. D. Liggett, R. W. Bauer

Naturally occurring epizootics of acanthamoebiasis were diagnosed on six greyhound farms from Northern Florida and Southern Georgia. Three of the outbreaks occurred in the summer and fall of 1985 and 3 more happened in the summer of 1988. The dogs affected ranged in age from 8 weeks to 13 months, with clustering in the 5 to 7 month range. Clinical signs included oculonasal discharge, anorexia, lethargy, coughing, dyspnea, hemoptysis and neurologic disturbances.

Although further evidence may be required, we believe that undifferentiated spermatids are a sign of tumour development of the seminiferous epithelium due to extended treatment with anabolic hormones.

Table 1.

	lots	animals	sacrifice age	inoculated time
experimental group	I	6	75 days	30 days
	II	6	105 days	60 days
control group	I	6	75 days	
	II	6	105 days	

References

1. Bellido C., Gaytan F. (1985): Biol Reprod vol. 33, 381–387.
2. Hoffman B. (1986): Agora ONE. Jornadas Técnicas de vacuno de carne. Palacio de Cristal, Lérida, 30 Mayo–2 de Junio de 1986.
3. Michel G., Baulieu E. E. (1983): En: Anabólicos en Producción Pecuaria, Simposio celebrado en la O.I.E. pág. 55–66, Paris 1983.
4. Rao MV, Chinoy NJ (1984): Exp Clin Endocrinol 34, 211–217.
5. Wiggins JP et al. (1980): Am J Vet Res vol. 41, 487–492.

The number of LHRH-labeled axons was reduced in the LME of old rats. Further, the pattern of pixel distribution into classes of increasing gray levels was different in the two groups. The number of nucleated FSH-labeled cells and the total FSH area and immunoreactivity were almost twice in old compared with young animals. The measurements of LH-labeled cells were not different in the two groups. In old rats the number of ovarian follicles and corpora lutea was reduced and that of atretic follicles increased.

In conclusion, our data indicate that decreased LME LHRH associated with increased FSH-gonadotropes and plasma FSH occur in old RPP rats. These changes may contribute to explain the complex hormonal disarrangement responsible for the decline of reproductive functions in old female rats.

Cadavers and tissues from 14 cases were examined. Gross necropsy findings included acute, multifocal, nectrotizing pneumonia, and/or multifocal, hemorrhagic meningoencephalitis. Microscopically, a necrohemorrhagic pneumonia with an interstitial pattern and numerous protozoal organisms resembling amebic trophozoites were diagnosed. Brain lesions were multifocal granulomas with vasculitis and necrosis. Amebic organisms similar to these in the lung were present within the necrotic cerebral foci. Lesions in other tissues were