

Miscellanea : Topographical distribution of mast cells in human skin : pathogenesis of tropical elephantiasis : preliminary report

Autor(en): **Fernex, M. / Sarasin, R.**

Objektyp: **Article**

Zeitschrift: **Acta Tropica**

Band (Jahr): **19 (1962)**

Heft 3

PDF erstellt am: **29.06.2024**

Persistenter Link: <https://doi.org/10.5169/seals-311030>

Nutzungsbedingungen

Die ETH-Bibliothek ist Anbieterin der digitalisierten Zeitschriften. Sie besitzt keine Urheberrechte an den Inhalten der Zeitschriften. Die Rechte liegen in der Regel bei den Herausgebern.

Die auf der Plattform e-periodica veröffentlichten Dokumente stehen für nicht-kommerzielle Zwecke in Lehre und Forschung sowie für die private Nutzung frei zur Verfügung. Einzelne Dateien oder Ausdrucke aus diesem Angebot können zusammen mit diesen Nutzungsbedingungen und den korrekten Herkunftsbezeichnungen weitergegeben werden.

Das Veröffentlichen von Bildern in Print- und Online-Publikationen ist nur mit vorheriger Genehmigung der Rechteinhaber erlaubt. Die systematische Speicherung von Teilen des elektronischen Angebots auf anderen Servern bedarf ebenfalls des schriftlichen Einverständnisses der Rechteinhaber.

Haftungsausschluss

Alle Angaben erfolgen ohne Gewähr für Vollständigkeit oder Richtigkeit. Es wird keine Haftung übernommen für Schäden durch die Verwendung von Informationen aus diesem Online-Angebot oder durch das Fehlen von Informationen. Dies gilt auch für Inhalte Dritter, die über dieses Angebot zugänglich sind.

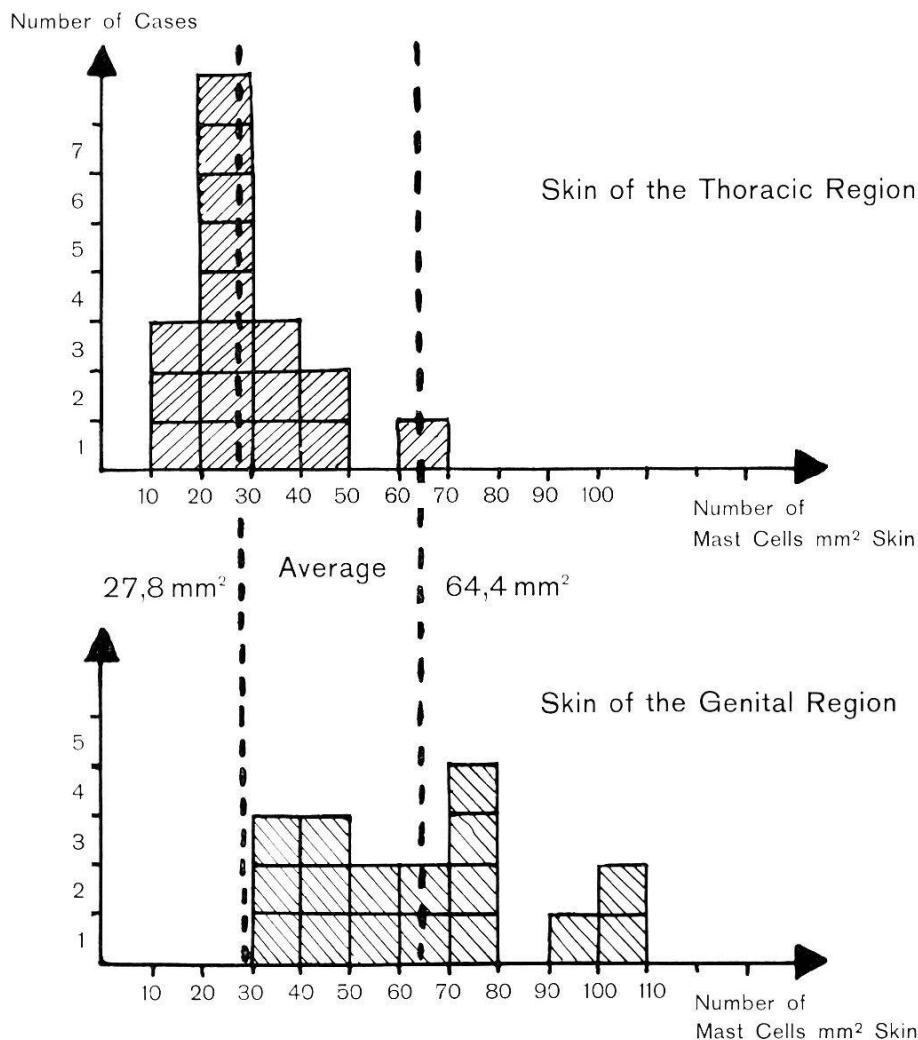
Topographical Distribution of Mast Cells in Human Skin. Pathogenesis of Tropical Elephantiasis.

(Preliminary Report.) *

By M. FERNEX and R. SARASIN,
Swiss Tropical Institute and Pathological Institute, Basle

The pathogenesis of tropical elephantiasis, a late complication of *Wuchereria bancrofti* and other filarial infections is not quite understood (1). The lymphostasis plays of course a determining role. Adult worms of *Wuchereria*

TABLE I.
Topographical distribution of mast cells in human skin.



Comparison between the mast cell number of the thoracic skin, average 27.8 MC/mm², and the mast cell number of scrotum and vulva, average 64.4 MC/mm².

bancrofti live in the lymphatics. The inflammation around dead adults or more seldom microfilarias produces a progressive obstruction of the lymphatic

* Financial assistance for these investigations was kindly provided by a grant from the Swiss National Foundation for Scientific Research.

vessels. The consequence of this may be lymphostasis, lymphangiectasis, and sometimes an important hypertrophic sclerosis which can lead to a huge tumorous proliferation of the connective tissue.

The most frequent sites of these elephantiasic tumours are the leg, the scrotum, the vulva and the breast.

Organs such as scrotum and breast have a very rich and complex lymphatic drainage. If lymph vessels obstruction would be the only mechanism for elephantiasis, it would become difficult to appreciate why these two organs in particular are so frequently the site of tumorous hyperplasia of connective tissue, and why the arms for instance with a much simpler lymphatic supply are so rarely elephantiasic, even when the axillary lymphatic glands are involved.

Indeed, there must exist a local factor other than stasis, perhaps an *abnormal reactivity of the connective tissue* of certain regions, making possible the tumorous hyperplasia of the subcutaneous or interstitial tissues, even if only a slight, but long-lasting lymphostasis occurs.

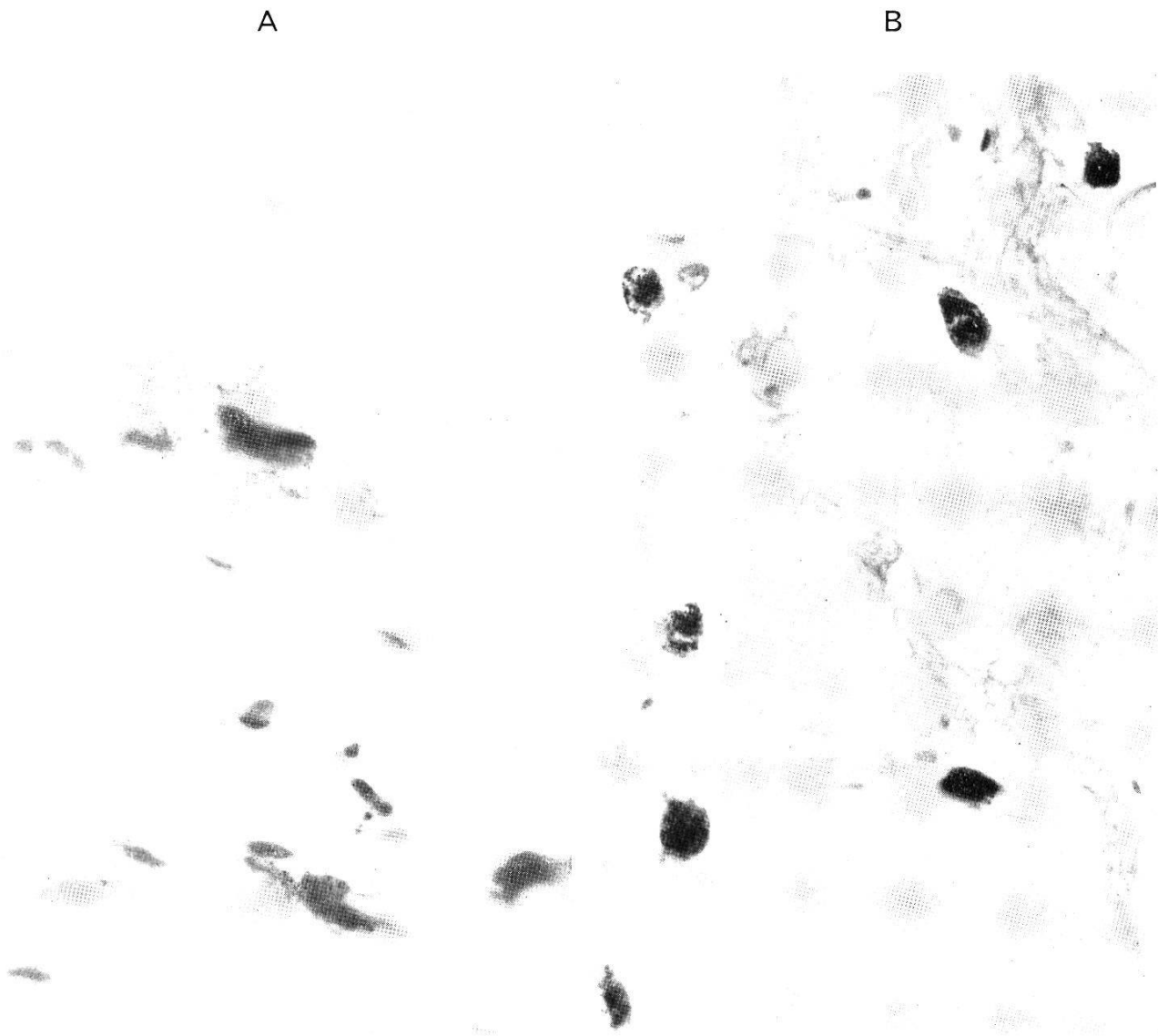


Fig. 1. Mast cells stained with toluidine blue, magnification $1000\times$. A. Very active mast cells with granules scattered in the connective tissue of the dermis in a case of filariasis. B. Numerous rather inactive round-shaped mast cells in the connective tissue of the breast (25-year-old African female who died from acute malaria attack).

Procedure.

In a series of autopsies performed in Basle, the skin is sampled from the thoracic and genital region. The material is fixed in formalin 10% embedded in paraffin, cut at 7 microns, and stained with toluidine blue. The mast cells are counted in 40 microscopic fields of $\frac{1}{4}$ mm², and their number expressed per square millimeter.

The results are compared in Table I.

Result.

In all but a single case the number of mast cells was higher in the genital region than in the thoracic region. It is probable that this difference would be even more accentuated in younger people having more active sexual endocrine secretions.

The connective tissue of the breast might also be exceedingly rich in mast cells (4) (Fig. 1 B).

Discussion and conclusion.

Helminthic diseases such as filariasis produce a proliferation of the pre-existing mast cells which are very active elements of connective tissue (2) (Fig. 1 A). In certain regions, scrotum, vulva and breast, there exist normally mast cells in particularly great number, and they play an important role in the genesis of tumorous elephantiasis, as will be demonstrated in a forthcoming paper (3).

We may conclude that the large population of mast cells of the normal genital skin and breast, increased by helminthic infections, may be the *local substratum* which makes possible the development of *tumorous elephantiasis* of scrotum, vulva and breast in cases of filarial infections involving lymphatic vessels.

References

1. BRUMPT, E. (1947). Filarioses et elephantiasis. — Ann. Soc. belge Méd. trop. Liber jubilaris J. Rodhain, p. 103-120.
 2. FERNEX, M. (1962). Mastocytose et éosinophilie. Contribution à l'étude physiopathologique des hyperéosinophilies. — Bull. Soc. Path. exot. 55 (séance du 8 mai, à paraître).
 3. FERNEX, M. & BÉZES, H. Pathogenesis of tropical elephantiasis (in press).
 4. HIGUCHI, K. (1930). Die Gewebsmastzellen der Mamma. — Folia haemat. (Lpz) 41, 401.
-