

Miscellanea : Sclerosis of Oddi's Sphincter

Autor(en): **Vinke, B.**

Objektyp: **Article**

Zeitschrift: **Acta Tropica**

Band (Jahr): **22 (1965)**

Heft 2

PDF erstellt am: **08.08.2024**

Persistenter Link: <https://doi.org/10.5169/seals-311267>

Nutzungsbedingungen

Die ETH-Bibliothek ist Anbieterin der digitalisierten Zeitschriften. Sie besitzt keine Urheberrechte an den Inhalten der Zeitschriften. Die Rechte liegen in der Regel bei den Herausgebern.

Die auf der Plattform e-periodica veröffentlichten Dokumente stehen für nicht-kommerzielle Zwecke in Lehre und Forschung sowie für die private Nutzung frei zur Verfügung. Einzelne Dateien oder Ausdrucke aus diesem Angebot können zusammen mit diesen Nutzungsbedingungen und den korrekten Herkunftsbezeichnungen weitergegeben werden.

Das Veröffentlichen von Bildern in Print- und Online-Publikationen ist nur mit vorheriger Genehmigung der Rechteinhaber erlaubt. Die systematische Speicherung von Teilen des elektronischen Angebots auf anderen Servern bedarf ebenfalls des schriftlichen Einverständnisses der Rechteinhaber.

Haftungsausschluss

Alle Angaben erfolgen ohne Gewähr für Vollständigkeit oder Richtigkeit. Es wird keine Haftung übernommen für Schäden durch die Verwendung von Informationen aus diesem Online-Angebot oder durch das Fehlen von Informationen. Dies gilt auch für Inhalte Dritter, die über dieses Angebot zugänglich sind.

Sclerosis of Oddi's Sphincter.

By B. VINKE.

Dept. of Internal Medicine, St. Elisabeth Hospital, Curaçao.

In the tropics a great many patients are found to be suffering from vague abdominal complaints. The correct diagnosis of their ailment is depending on the clinical experience of the treating physician and the technical facilities available. One of the relatively rare and easily missed causes is formed by benign sclerosis of the sphincter of Oddi, which may only be diagnosed by an intravenous cholecystogram. It therefore seems to merit extra publicity, as the latter examination is not considered to be a routine procedure.

Stenosis of Oddi's sphincter exists, if the diameter of the ostium is less than 3 mm. At operation a probe of this size or less may not be passed, while a normal sphincter gives an easy passage to a probe of 3 to 7 mm in diameter. On palpation—at operation—the sphincter often is of firm consistency. The tissues around it may be hypertrophied, giving it the aspect of a papilloma. The common duct may be grossly dilated.

Histological examination of the sphincter shows that the muscle fibers have disappeared and have been replaced by strands of fibrous tissues with fibrocytes.

The aetiology of sclerosis of Oddi's sphincter is not completely clear. It is thought to be due to a chronic spasm of this muscle, which ultimately leads to a fibrosis. According to DEL VALLE (1928) this spasm and the fibrotic infiltration may become more severe and hastened by chronic inflammation. Apart from due to this primary spasm a number of cases may develop secondary to inflammation of, or due to an impediment in the sphincter. The clinical entirety has to be differentiated from the obstruction caused at this point by a stone in the common duct, by pancreatitis or by a tumor either of the papil of Vater or of the head of the pancreas. These causes may give rise to an obstruction which is essentially of another nature.

The majority of the patients are over 40 years, more often female than male.

Their complaints may vary from vague discomfort in the upper abdomen to distinct pain in the liver region, which may even be of the colicky type. According to DEL VALLE the character of the pain originating from obstruction of the sphincter of Oddi should be typical. It irradiates from the gallbladder region to the vertebral column (L.I.) and the left scapular region, contrary to the pain of gallbladder disease which irradiates to the mid-thorax, the right hemithorax and the right scapular area. However in CATTELL's experience (1957) this typical description as given by DEL VALLE was not or not often met with, and their patients complained of pain in the liver region or epigastrium, extending to the mid-dorsal or right shoulder area. Signs of biliary obstruction may be present, as transient jaundice (46% in CATTELL's cases), episodes of dark coloured urine associated with light coloured stools or slight diarrhoea due to fatty stools.

The duration of the complaints may be from some weeks to many years.

The diagnosis, as said before, may only be made by the intravenous cholecystogram, which presents a typical widening of the common duct, most times without the presence of stones. WISE and O'BRIEN (1956) think every duct, which has a diameter from 15 mm or more on the X-ray to be highly suspect for an obstruction at the sphincter of Oddi. If the diameter is between 8 and 15 mm, obstruction may or may not be present, but the probability rises if the picture taken after two hours shows a greater density of the duct, than the one taken after one hour.

The differentiation of this disease from other abdominal complaints may be extremely difficult, especially if one not constantly has the possibility in mind. This probably explains, why CATTELL is able to collect 100 cases in 40 months, while BARTLETT and QUINBY (1957) do not even mention the diagnosis in their 92 patients, that needed reoperation after unsuccessful gallbladder surgery. As we met with 4 cases in about 430 gallbladder operations the frequency of this ailment seems to be more than generally thought. Gallbladder and liver disease as well colitis are the ones to be differentiated from stenosis of the sphincter of Oddi as may be seen in the following case histories.

Hepatic amoebiasis with its variable clinical picture may—often also due to the similar laboratory findings—give rise to difficulties as can be seen in our first patient. The presence of nausea however should have been a warning, that the case was not so simple as originally thought.

F. B., old 70 years, complained about her stomach. She often felt nauseated and had to vomit specially after meals. No pains and no pyrosis. Urine and stools had a normal aspect. The nausea was progressive in the last 3 months and was treated by her physician with largactyl. She had never been seriously ill apart from a thrombophlebitis in the previous year. Examination showed as only positive findings pain on tapping the liver region, a blood pressure of 180/110, and a low fever between 37.9° and 38.2°C.

Laboratorium: BSR 90 mm after 1 hour. Hb. 11.4 g%. WBC 21,200/mm³. Diff.: stabs 3%, segments 71%, lymphoc. 22%, monoc. 4%. Thymol 1.1 U, alk. phosph. 17.1 U (K.A.). Bilirubin dir. 1 mg, indir. neg. Cholesterol 351 mg%, esters 233 mg%. Total protein 7.4%. Urine apart from a trace urobilin normal. Stools contained *E. histolytica*.

Diagnosis: It was thought, that the patient was suffering from a liver amoebiasis, seen the pain on tapping the liver region, the raised BSR, the raised alk. phosphatase and the positive stools.

Clinical course: Patient was treated with emetine, aralen, yatren and carbason. The nausea, the pain on tapping the liver and the fever disappeared. However the BSR did not fall below 57 mm after 1 hour and the alk. phosphatase not below 12.2 U K.A. As these results were not according to the ones to be expected in amoebic liver disease an X-ray of the gallbladder was made. On the oral cholecystogram stones in the gallbladder were present. An intravenous cholecystogram seemed indicated to exclude stones in the common duct. The common duct was very wide (fig. 1). As no stones seemed present the diagnosis of the sphincter of Oddi was made. At operations the sphincter was about 2 mm in diameter and was treated with transduodenal division. The gallbladder was removed.

Cholangitis was the initial diagnosis in the next very interesting case, which furthermore demonstrates that probing the bileducts is no absolute proof for patency of the sphincter of Oddi.

H. P., female, born in 1907, was admitted in 1954 with hypertension. Also a positive Wassermann reaction and a polycythaemia were found. Hb. 17.8 g%, RBC 5,920,000/mm³. She had a palpable spleen. From the liverfunction tests only the BSP of 30% retention was abnormal. She was treated for the polycythaemia with Daraprim with good result. November 1956 she was readmitted with jaundice and fever. Spleen still palpable, liver could not be felt. Hb. 14 g%, RBC 4,750,000/mm³, retic. 1.2%, alk. phosphatase 27 U (K.A.). Thymol T.T. 1.1 U. Cholesterol 300 mg%, esters 90 mg%. Bloodculture demonstrated *B. pyocyaneus*. Despite treatment with several antibiotics it was impossible to lower

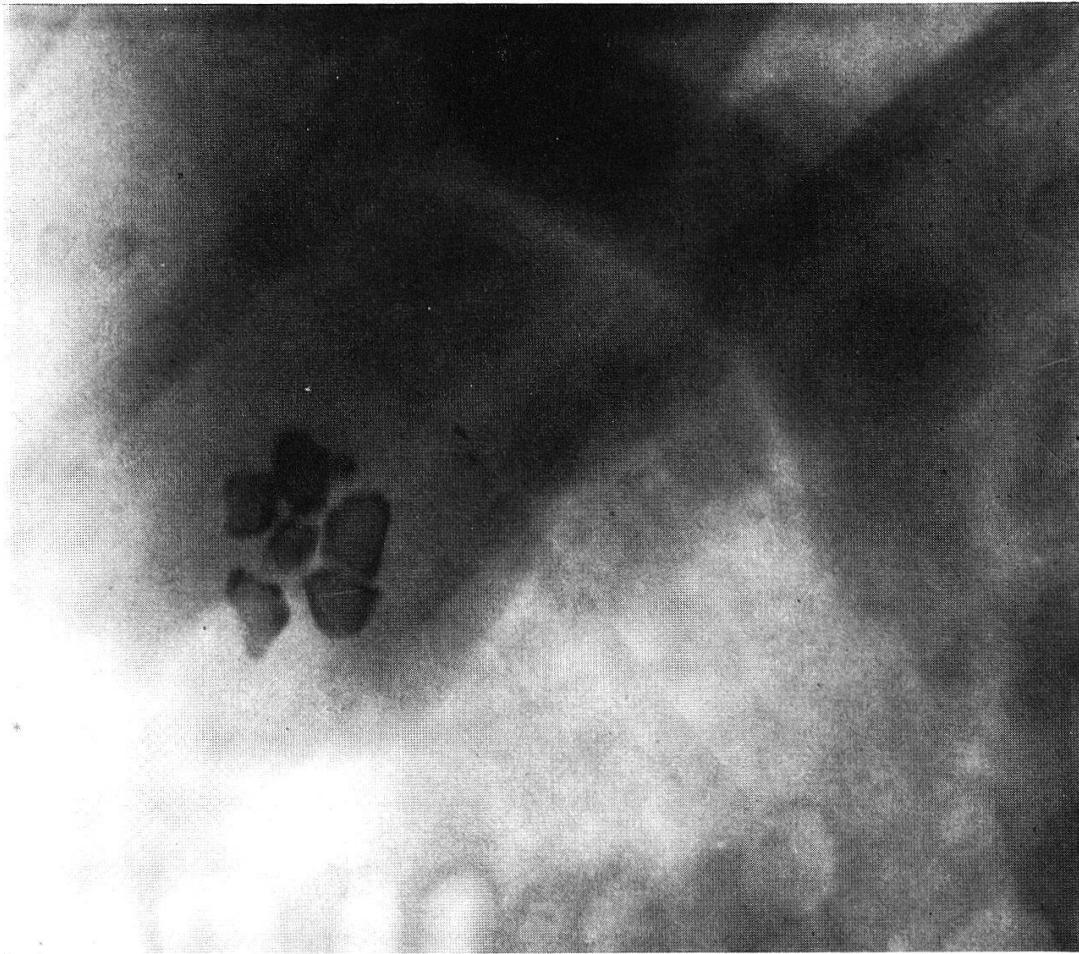


Fig. 1. The gallbladder contains stones, the common duct is extremely wide, but does not contain stones.

the temperature. Ultimately she reacted to achromycine, but started a period of normal temperature, which was interrupted by several peaks of high fever lasting two to three days. This was accompanied by a rise of the blood bilirubin, which disappeared with the fever. Operation was decided on and a chronic inflamed gallbladder was removed, which did not contain stones. The gallducts were probed to either side and apparently were normal. After the operation the wellknown bouts continued. There was little healing tendency of the wound after the removal of the T drain. Patient was discharged in reasonable condition 4 months after admission with as diagnosis cholecystitis with cholangitis. Readmission was necessary a month later due to the presence of a gallfistel. If the wound was open she was in good condition, when closed she had bouts of fever with araised blood bilirubin.

The stools contained bile, but were lightly coloured. Patient was reoperated with as diagnosis: Sclerosis of the sphincter of Oddi. A preoperative trial to visualise the gallducts through the fistule was a failure, but one made during the operation showed a stop at the height of the papil of Vater (fig. 2). The sphincter was sclerotic and had a lumen of 1 mm diameter. Transduodenal division of the sphincter resulted in a complete cure. She did not report to the outpatient department, but was readmitted in Jan. 1962 with a ruptured spleen after a fall.

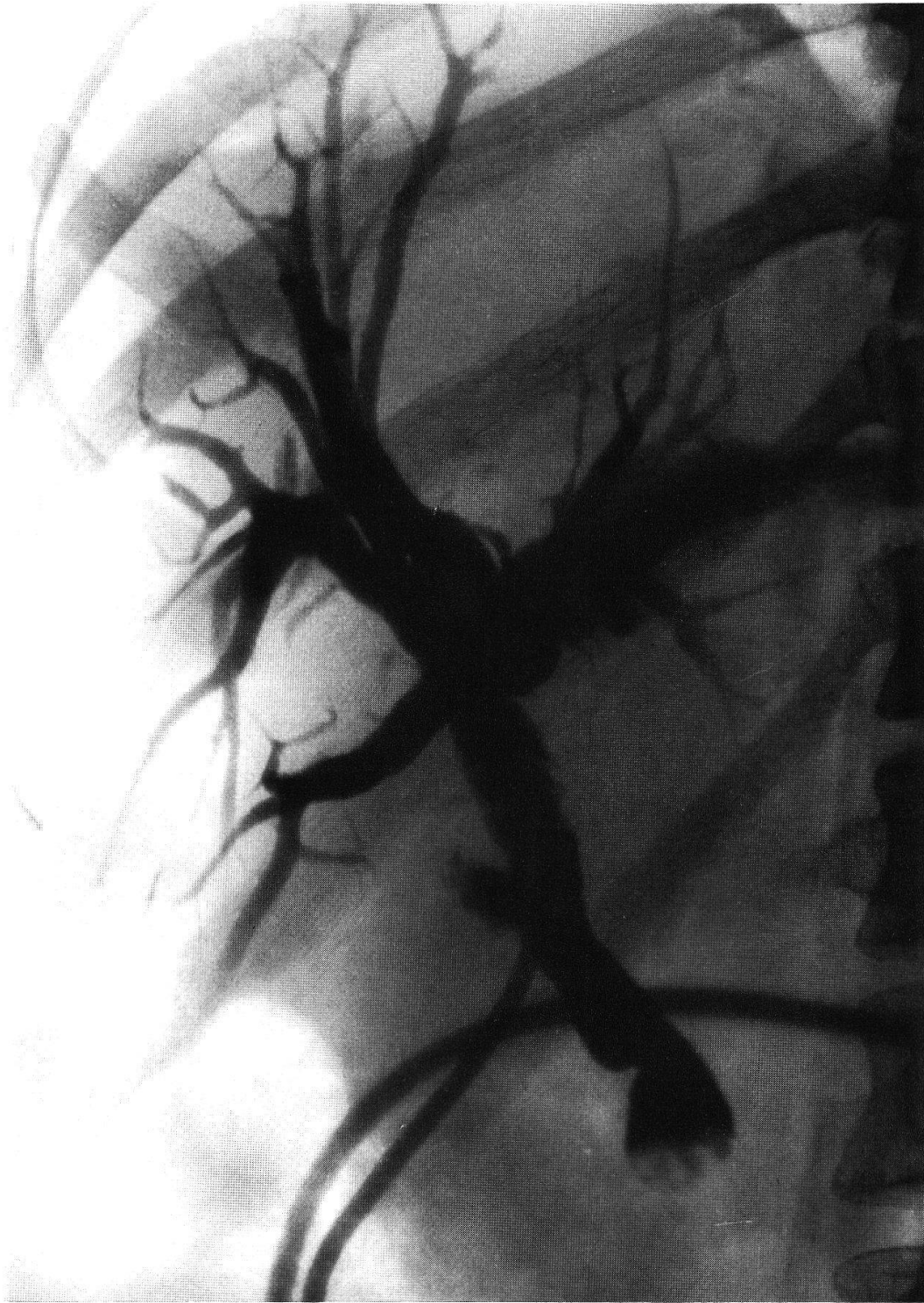


Fig. 2. The cholangiogram, made during the operation demonstrates the absence of stones. The ducts are wide, with a complete stop at the Papil of Vater. Even after 15 minutes no dye is excreted in the gut.

Cholelithiasis with a stone in the common duct may be complicated by a sclerosis of the sphincter. This surprising finding was present in one of our patients.

J. M., female, aged 44, was admitted to the hospital in November 1958, suspected by her general practitioner of a commencing hepatitis. A week before she had fallen from a staircase, complained later of low back aigue and had difficulties in walking. Three days later she suffered pain in the right costal margin especially in the afternoon, accompanied with nausea and sometimes vomiting. Two days later her urine was dark, suggesting the development of hepatitis. The past history after careful questioning revealed longstanding vague dyspepsia. She had never been ill. Examination showed no abnormalities. BSR 62 mm after 1 hour, Hb. 12.8 g%, WBC 5,500/mm³ with normal differentiation. Bilirubin dir. 0.2 mg, indir. 0.4 mg. Thymol T.T. 1.5 U. Alk. phosph. 19.5 U (K.A.). BSP 2% retention after 30 min. Cholesterol 295 mg%, esters 135 mg%. Total protein 7% with a normal electrophoresis. Urine urobilinogen trace. Stools no parasites, benzidine reaction negative. Fractioned testmeal: low acid values. Duodenal entubage no B-gall. Oral cholecystogram no visualisation of the gallbladder. Intravenous cholecystogram: cholelithiasis with a stone in the sphincter of Oddi. Operation showed apart from the wellknown stones in gallbladder and the common duct a sclerosis of the sphincter of Oddi, which had a diameter of about 1 mm. A transduodenal division was performed.

A colitis like picture was presented by another of our patients. This diagnosis seemed to be confirmed by a diverticulosis of the colon, demonstrated on the X-ray. An attack of cholecystitis three months later, after which the diagnosis sclerosis of Oddi's sphincter was made, made one wonder if the initial complaints had not already been caused by this obstruction in the bileducts.

G. B., aged 61, complained about a "heavy feeling" in epigastrio. The past year she suffered from chronic constipation with bouts of diarrhoea due to overdosage of purgatives. She had lost weight. Examination showed a slight anaemia (11.2 g%). X-ray of the colon showed a diverticulosis mainly of the caecum and ascending colon. Patient was treated with aureomycin after she felt much better. Three months later she was admitted due to a severe colic in the liver region, which irradiated to the back (thoracal vertebral body 12). She ran a fever of 38.2°C and was nauseated. The liver was painful on tapping and in the gallbladder region muscular rigidity was found. BSR 7 mm, rose to 63 mm after 1 hour. Bilirubin dir. 0.6 mg%, indir. 0.6 mg%, SGOT 118 U, SGPT 95 U. Lactic acid dehydrogenase 510 U. The alkaline phosphatasis which on admission was 8.9 U, rose to 21.4 U (K.A.). Patient was treated with bedrest and antibiotica. After normalisation of the liverfunction tests an X-ray of the gallbladder was performed. Intravenous cholecystogram, after a negative oral one, showed a normal gallbladder but a greatly widened common duct. At operation the gallbladder did not contain stones, neither did the common duct, but the sphincter of Oddi was sclerotic. Transduodenal division was performed. A biopsy showed the normal topography of the mucosa and muscular layers to be disturbed by layers of newly formed fibrotic tissue and polymorphic inflammatory infiltration. No signs of malignancy were present.

From the given examples it seems that the case histories show a great variety. As a clearcut clinical picture does not exist, the diagnosis should be considered in cases of vague abdominal complaints for which no good reason can be found.

As the treatment of stenosis of the sphincter of Oddi is a surgical one and failure to correct it, in cases of gallbladder disease, leads to recurrence of the complaints it is of great importance to make the diagnosis either before or during the operations. Probing the common duct during operation decreases the possibility of missing an obstruction, but is in no way proof that the sphincter is patent. It is possible, that the probe only invaginates the duct in the duodenum (MAHORNER and BROWNE 1955). Forcible dilatation as a way of treatment is unreliable and may give rise to uncontrolled tears in the sphincter.

A side to side anastomosis between the common duct and the duodenum, provides an open communication between the intestine and the gallducts. This might give rise to a cholangitis. However this infection does not seem to be very frequent, as HOSFORD (1957) did not meet this complication in 21 patients, in which he performed the anastomosis operation. If however the common duct and the pancreatic duct are separate, but both enclosed by the sphincter of Oddi, a failure to alleviate the obstruction, may result in permanent damage to the pancreas.

The treatment of choice therefore seems to be the transduodenal division. The great advantage is that the division may be performed with good visualisation of the sphincter. This method however also has its dangers, being intestinal haemorrhage and pancreatitis (CATTELL, 1957).

References.

- BARTLETT, M. K. & QUINBY, W. C. (1957). Surgery of the biliary tract. — *New Engl. J. Med.* 256, 11-15
- CATTELL, R. B., COLCOCK, B. P. & POLLACK, J. L. (1957). Stenosis of the sphincter of Oddi. — *New Engl. J. Med.* 256, 429-435
- DEL VALLE, D., Jr. (1928). Patologia del esfinter de Oddi. — *Rev. bras. Med. Pharm.* 4, 479-489
- HOSFORD, J. (1957). Treatment of stone in common bile duct. — *Brit. med. J.* I, 1202-1205
- MAHORNER, H. & BROWNE, E. R. (1955). Results following transduodenal choledochampulotomy. — *Ann. Surg.* 141, 607-614
- WISE, R. E. & O'BRIEN, R. G. (1956). Interpretation of the intravenous cholangiogram. — *J. Amer. med. Ass.* 160, 819-827