

The occurrence of an intraerythrocytic microorganism "*Neitzella rezendei*" gen. nov. sp. nov. (Microtatorbiotes, Rickettsiales) of poultry in Brazil

Autor(en): **Massard, C.L. / Lopes, C.W.G. / Cunha, Daisy W. da**

Objektyp: **Article**

Zeitschrift: **Acta Tropica**

Band (Jahr): **33 (1976)**

Heft 1

PDF erstellt am: **08.08.2024**

Persistenter Link: <https://doi.org/10.5169/seals-312216>

Nutzungsbedingungen

Die ETH-Bibliothek ist Anbieterin der digitalisierten Zeitschriften. Sie besitzt keine Urheberrechte an den Inhalten der Zeitschriften. Die Rechte liegen in der Regel bei den Herausgebern.

Die auf der Plattform e-periodica veröffentlichten Dokumente stehen für nicht-kommerzielle Zwecke in Lehre und Forschung sowie für die private Nutzung frei zur Verfügung. Einzelne Dateien oder Ausdrucke aus diesem Angebot können zusammen mit diesen Nutzungsbedingungen und den korrekten Herkunftsbezeichnungen weitergegeben werden.

Das Veröffentlichen von Bildern in Print- und Online-Publikationen ist nur mit vorheriger Genehmigung der Rechteinhaber erlaubt. Die systematische Speicherung von Teilen des elektronischen Angebots auf anderen Servern bedarf ebenfalls des schriftlichen Einverständnisses der Rechteinhaber.

Haftungsausschluss

Alle Angaben erfolgen ohne Gewähr für Vollständigkeit oder Richtigkeit. Es wird keine Haftung übernommen für Schäden durch die Verwendung von Informationen aus diesem Online-Angebot oder durch das Fehlen von Informationen. Dies gilt auch für Inhalte Dritter, die über dieses Angebot zugänglich sind.

The Occurrence of an Intraerythrocytic Microorganism *Neitziella rezendei* gen. nov. sp. nov. (Microtatobiotes, Rickettsiales) of Poultry in Brazil

C. L. MASSARD¹, C. W. G. LOPES¹, DAISY W. DA CUNHA¹
and CLAUDETTE DE A. MASSARD²

Introduction

Investigations on an intraerythrocytic microorganism of poultry followed a request from the owner of the Campo Verde estate in the state of Minas Gerais, Brazil, for the writers to determine the possible cause of illthrift in his flock of 50 turkeys. In contrast the fowls, ducks, geese and swans on this estate were thriving well. Feed for the poultry consisted of crushed yellow maize. They roamed freely on the farm and had free access to the lush green vegetation. When illthrift became evident among the turkeys, the owner supplemented the poultry diet with a balanced feed consisting of proteins, carbohydrates, vitamins, minerals and trace elements. As no improvement was noticed during the ensuing month, one of us (C.L.M.) prepared blood films from 25 turkeys of different age groups and from 9 fowls. Microscopical examination of the Giemsa-stained films revealed that all turkeys harboured intraerythrocytic microorganisms varying approximately from 0.3 to 1.0 μ in size while the films from the fowls were all negative for blood parasites as recorded in Table 1.

The estate was visited again six weeks later. The condition of the turkeys showed a distinct improvement. A second set of blood films were prepared from the same turkeys. The examination showed that only 11 of these birds showed a low grade microscopic infection.

This unexpected finding naturally prompted us to continue the investigations in order to determine the identity, pathogenicity and distribution of the microorganism.

Materials and Methods

1. Origin of the naturally infected avian hosts

Investigations conducted on the Campo Verde estate (M.G.) were extended to establish the incidence and distribution of the microorganism in turkeys, fowls and ducks on four farms in the state of Rio de Janeiro and in a turkey and a duck on a farm in the state of Espirito Santo. The farmers were cooperative and kindly donated several naturally infected turkeys, chickens and ducks to the University of Rio

¹ Department of Animal Biology, Universidade Federal Rural do Rio de Janeiro.

² Stipendiary of the National Research Council, Rio de Janeiro, Brazil.

de Janeiro for research. Their origin is listed in Table 1. They were kept in isolation to obviate accidental infections with other pathogens and received a daily ration of an antibiotic-free feed to exclude a possible therapeutic action on the microorganism. The isolation facilities at the Veterinary Research Institute of the Ministry of Agriculture of Brazil were kindly provided by Dr. J. Langenegger.

2. Origin of susceptible birds

Healthy day-old poults, ducklings and a chicken were purchased from certified breeders. Blood films from them were examined before they were employed for biological tests. These proved to be parasitic-free in all instances. They were maintained in isolation at the Institute of Parasitology of the Department of Animal Biology of the University of Rio de Janeiro.

3. Films prepared from the peripheral blood or from organs were fixed with methyl alcohol and stained with Giemsa stain.

4. Field observations

Results of the surveys are listed in Table 1. They include a record of the poultry population on the farms, the incidence of naturally infected turkeys, fowls and ducks and the degree of infection in different age groups. It will be seen that natural infections occurred in three species in three Brazilian states. Several of the donated birds were used to determine the duration of the parasitic carrier state or as reservoirs for establishing the host range. Data are presented in Table 2.

5. Laboratory investigations

(a) Maintenance of the pathogen for research

For systematic investigations it is essential to maintain an infectious agent in readily available reservoirs. Observations made at the Campo Verde estate (Table 1) showed that 11 out of the 25 turkeys harboured a microscopic infection for a period of 6 weeks. This suggested that a labile infection might persist for even longer periods. In order to prove such a possibility, two of the donated turkeys (No. 13 and 28) from the estate were selected to determine the duration of the carrier state. Giemsa-stained blood films were prepared and examined at regular intermittent intervals from 10. 6. 1974 to 30. 11. 1974.

At the beginning of the microscopical studies some difficulty was experienced in differentiating between the extremely polymorphic intracytoplasmic microorganisms and epicellularly situated minute (hemokonia) and larger (plastid) cell fragments which sometimes float in avian serum and completely detached nuclear particles occurring within the cytoplasm of some erythrocytes. However, as time progressed the morphological pattern of the parasites together with their response to

Table 1. Observations on the distribution and incidence of the avian intraerythrocytic organism

State Town Farm Owner	Poultry population		History of poultry	Microscopical examination of blood films			
	Species	No.		Date	Species	Group	No. Percent- age rate of infec- tion
Minas Gerais Barbacena Campo Verde Dr. J. A. Castilho	Turkeys	50	Adults (3-4 years), poults (A, 6-7 months, B, 4-6 weeks); flock unthrifty. Presented 5 turkeys for research	27. 04. 74	25 Turkeys	Adults	4 20
					9 Fowls	Adults	2 60
				08. 06. 74	25 Turkeys	Poults, A	12 20
						Poults, A	1 60
	Fowls	30	Adults (1-2 years), healthy			Poults, B	6 5
	Ducks	20	Adults (1-2 years), healthy ¹			Adults	9 0
	Geese	20	Adults (1-2 years), healthy ¹			Adults	6 0
	Swans	2	Adults (2 years), healthy ¹			Poults, A	5 5
						Poults, A	8 0
						Poults, B	6 5
Rio de Janeiro Passa Tres Brasilave Manager	Turkeys	3,000	Apparently healthy flock but 6 poults (C, 9 months) emaciated sequel to coryza, chronic respi- ratory disease and diarrhoea Presented 2 poults (D, 6 months) for research	22. 05. 74	6 Turkeys	Poults, C	6 20
					2 Turkeys	Poults, D	1 40
	Fowls	30	Adults (1-2 years), healthy ¹				1 0
	Turkeys	12	Adults (1-2 years), 8 healthy, 3 unthrifty (E), 1 emaciated and suffering from advanced cochlio- myiasis and died on 29.05.74 (F)	25. 09. 74 29. 09. 74	4 Turkeys	Adults, E, F	4 30
Seropédica Campus of U.F.R.R.J. Mrs. A. S. Vas- concelos					4 Turkeys	Adults, E	1 20
						Adults, E	2 5
						Adults, F	1 30

Table 1 (continued)

State Town Farm Owner	Poultry population		History of poultry	Microscopical examination of blood films			
	Species	No.		Date	Species	Group	No. Percent- age rate of infec- tion
Rio de Janeiro Seropédica Km – 49 Mr. P. Pereira	Fowls	30	Adults (1–2 years) and chickens (2 months) all unthrifty Presented 2 chickens for research	23. 11. 74	6 Fowls	Adult Chickens	1 0 3 ² 20 2 0
	Duck	1	Adult (1 year) emaciated		1 Duck	Adult	1 10
Barra Mansa Vista Alegre Mr. J. J. Meirelles	Fowls Ducks	40 10	Adults (1–2 years), healthy ¹ Adults (1–2 years), healthy. Pre- sented 2 ducks for research	12. 09. 74	2 Ducks	Adult	1 30 1 20
Espirito Santo Município Alegre Vila Café Mr. C. V. Thiebaut Mr. F. Magalhaes	Turkey	1	Adult (1 year), emaciated	13. 10. 74	1 Turkey	Adult	1 30
	Fowls	40	Adults (1–2 years) and chickens (1–3 months), healthy ¹				
	Ducks	10	Adults (1 year), healthy	13. 10. 74	1 Duck	Adult	1 20

¹ No blood films were prepared. ² One of the chickens died within 18 hours after having been admitted to Institute of Biology of the University of Rio de Janeiro.

Table 2. Determination of the host range of the intraerythrocytic avian microorganism

Donors		Recipients			Experimental transmission			Reaction					
No.	Species and origin	Parasitic carrier state	Age in days	No.	Species	Age in days	Date	Inoculum	Dose in ml.	Route	Incubation period in days	Ensnuing microscopic observation period in days	Variation in the erythrocytic percentage in infection rate
13	Turkey Campo Verde Barbacena M G	Microscopic parasitosis following a natural infection	200	C	Fowl	250	12. 06. 74	Blood	1.0	i p	26	142	5-30
28	Turkey as for No. 13	As for No. 13	200	1	Poult	7	20. 11. 74	Blood	1.0	i p	6	2	5-10
				2	Poult	7	20. 11. 74	Blood	1.0	i p	6	2 (died on 2nd day of reaction)	5
5	Duck Vista	Microscopic parasitosis following a natural infection	400	7	Duckling	7	8. 11. 74	Lung suspens.:	1.0	i p	10	11	5-10
	Alegre Barra Mansa R J	natural infection		8	Duckling	7	8. 11. 74	Liver	1.0	i p	13	11	5-10
				9	Duckling	7	8. 11. 74	Kidney	1.0	i p	14	11	5-10
				10	Duckling	7	8. 11. 74	Spleen	1.0	i p	14	11	5-10
				11	Duckling	7	8. 11. 74	Brain	1.0	i p	14	11	5-10
				12	Poult	7	8. 11. 74	Kidney	1.0	i p	18	11	5-15
				13	Poult	7	8. 11. 74	Lung	1.0	i p	13	11	5-10

Table 2 (continued)

Donors		Recipients			Experimental transmission			Reaction					
No.	Species and origin	Parasitic carrier state	Age in days	No.	Species	Age in days	Date	Inoculum	Dose in ml.	Route	Incubation period in days	Ensuing observation period in days	Variation in the erythrocytic percentage in infection rate
1	Duck Vista Alegre Barra Mansa R J	Microscopic parasitosis following a natural infection	400	2	Duckling	48	11. 10. 74	Blood	1.5	i p	18	29	5-10
2	Duckling	Microscopic parasitosis following an experimental infection	88	14 15	Poult Poult	7 7	20. 11. 74 20. 11. 74	Blood Blood	1.0 1.0	i p i p	8 8	2 2	5-10 5-10

i p = intraperitoneal.

the Giemsa stain (red, red-violet or deep purple) served as guides for their identification.

Studies revealed that a microscopic infection in the two turkeys, which persisted for 3 to 4 weeks, was followed by periods of a sub-microscopic infection which lasted for about 1 to 2 weeks. Microscopic infections were interrupted by submicroscopic ones over a period of 217 days.

Additional observations conducted on two ducks from the Vista Alegre farm (Tables 1 and 2) showed that the carrier state following a natural infection persisted for at least 57 days. The experimentally infected Fowl C (Table 2) harboured the infectious agent for 168 days.

Although the time of the natural infections is unknown, there is good reason to believe that the two turkeys acted as carriers of the pathogen for more than 217 days and the ducks for longer than 57 days. The end point of a labile infection in avian hosts still needs to be determined.

(b) The host range

The demonstration of microscopically identical microorganisms in naturally infected turkeys, ducks and chickens (listed in Table 1) naturally raised the question whether or not they belong to the same species. Consideration of these observations made it apparent that conclusive evidence would depend upon results biological tests listed in Table 2. The information includes the origin of the parasitized avian hosts from which blood or organs were derived and the recipients which received either blood or organ suspensions in normal saline by the intraperitoneal route. The examination of Giemsa-stained blood films showed that all recipients developed a microscopic infection after incubation periods which varied from 6 to 26 days. Microorganisms harboured by two turkeys developed in two poults and a fowl while those from 3 ducks were successfully transmitted to 6 ducklings and 4 poults. The microscopic observation periods of the poults and ducklings varied from 2 to 29 days and the erythrocytic infection rate varied from 5 to 15%. The observation period of the fowl lasted for 142 days and the degree of the erythrocytic infection rate varied from 5 to 30%.

The examination of blood and tissue films from Duck 5 (Table 2), which was sacrificed for the preparation of lung, liver, kidney, spleen and brain suspensions, failed to reveal any microorganisms in cells other than the erythrocytes. During the course of the experiments a 2-month-old infected chicken (Table 1) and a 9-day-old infected poult (Table 2) died. Autopsy of the chicken showed that decomposition was far advanced while that of the poult failed to reveal any macroscopical lesions. Blood and tissue films failed to reveal any parasites in cells other than erythrocytes. Critical experiments need to be undertaken

Table 3. The host range of the intraerythrocytic avian microorganism

Parasite	Host				Distribution
Class Order Family	Class Order Family	Genus and species	Vernacular name	Inci- dence	States of Brazil
Microtatobiotres Rickettsiales	Aves Galliformes Meleagridae	<i>Meleagris gallopavo</i> L.	North American domesticated turkey	Enzootic	Minas Gerais Rio de Janeiro Espírito Santo
<i>Neitzziella rezendei</i> gen. nov., sp. nov.	Phasianidae	<i>Gallus domesticus</i> L.	Fowl	Enzootic	Rio de Janeiro
	Anseriformes Anatidae	<i>Anas borchas</i> L.	Duck	Enzootic	Rio de Janeiro Espírito Santo
		<i>Cairina moschata</i> L.	Muscovy duck Perching duck	Enzootic	Rio de Janeiro

to determine whether or not the erythrocyte is the only host cell for the microorganisms.

6. Protophytology

(a) Habitat

The preceding experiments have shown that the infectious agent is a heteroxenous parasite. The present state of our knowledge shows that the natural source of infection is among two members of the order Galliformes and two members of the order Anseriformes (Table 3). There are good reasons to believe that other members of these orders are also susceptible. The possible susceptibility of members of other avian orders needs to be determined. The natural mode of transmission is unknown.

Blood film examinations of two turkeys over a period of more than 200 days revealed that a microscopic infection is periodically interrupted by a submicroscopic infection. A complete absence of parasites may be followed by a gradual increase in the erythrocytic infection of up to 70%. In most instances a single organism is situated midway between the nucleus and margin of the host cell. The presence of two, three or four parasites in a single erythrocyte is not uncommon. Occasionally the infection rate may be as high as 12 organisms.

(b) Morphology

In Giemsa-stained blood films the parasite appears as red, red-violet or deep purple bodies. It is extremely polymorphic (Fig. 1). The

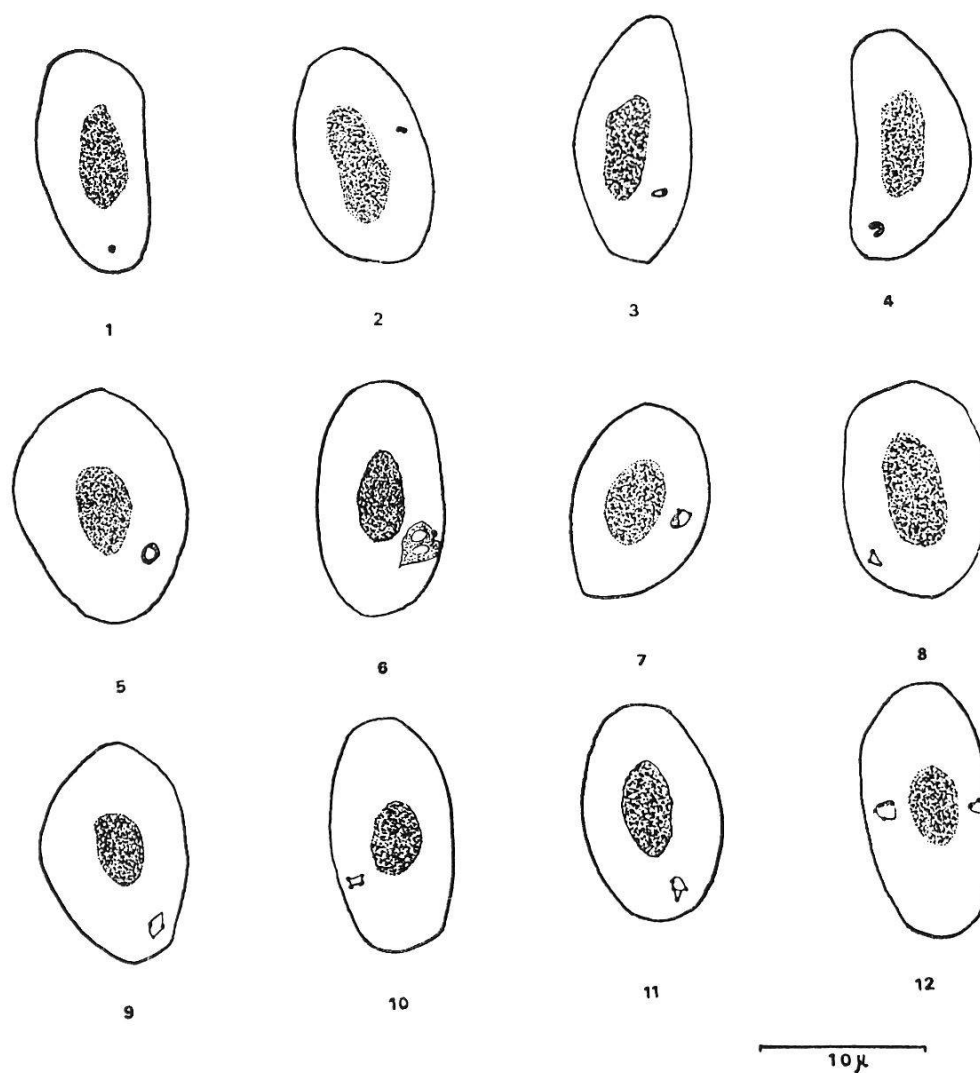


Fig. 1. 1. Coccoid form. 2. Paired coccoid form. 3. Small vacuolated comma-shaped form. 4. Large vacuolated comma-shaped form. 5. Round filamentous form. 6. Exceptionally large double-vacuolated filamentous form with a single granule. 7. Circular form comprised of a filamentous section laced with a fine thread showing two granules. 8. Triangular form showing two granules. 9. Quadrangular form showing two granules. 10. Quadrangular form showing four granules. 11. Ovoid form comprised of partially entangled thread showing four granules. 12. Triangular form showing four granules and an ovoid form comprised of a narrow filamentous section laced with a fine thread showing two granules.

greatest morphological range is preceded by a period varying from 3 to 5 days during which deep purple coccoid forms ($0.4\text{--}0.7\ \mu$) predominate (Fig. 1, 1). In addition, relatively few rod-shaped forms ($0.5\text{--}0.8\ \mu \times 0.3\text{--}0.4\ \mu$) are seen. They may possibly be precursors of paired ($0.5\text{--}0.9\ \mu \times 0.4\text{--}0.5\ \mu$, Fig. 1, 2), triple ($0.7\text{--}0.9\ \mu$) or quadruple ($0.7\text{--}1.1\ \mu$) groups of coccoid forms. When the components of a paired group part they remain linked to each other by very fine filamentous threads and appear as a V-shaped structure with a granule at each free end, a triangle (Fig. 1, 8) with a granule at two angles or a quadrangle

(Fig. 1, 9) with a granule at each of the diagonally opposite angles. When three components of a group part, they form a triangle (Fig. 1, 12) with a granule at each angle while those with four components produce an oblong quadrangle (Fig. 1, 10) or a square with a granule at each angle. The lengths of the linking threads vary from $0.7\text{--}1.1\ \mu$. It appears that ovoid (Fig. 1, 11) or round forms with four granules at different sites along the course of the filamentous thread are also derived from quadruple groups of coccoid forms. Circular (Fig. 1, 7) or ovoid forms (Fig. 1, 12) comprised of a strip of filamentous material the ends of which are linked with a fine, curved thread harbouring two granules have also been seen. Their origin and fate are obscure.

Besides the above-described forms a fairly large number of red-violet or deep purple comma-shaped parasites ($0.5\text{--}0.8\ \mu \times 0.3\text{--}0.4\ \mu$) with a small or large granule at the broader end and with (Fig. 1, 3 and 4) or without a vacuole have also been seen. These forms appear to give rise to round vacuolated ($0.6\text{--}0.8\ \mu$, Fig. 1, 5) woven red-violet filamentous threads. These threads become disentangled and give rise to 8 or 12 minute round, red "initial bodies" $0.2\text{--}0.3\ \mu$ in diameter. Very rarely exceptionally large, double vacuolated, irregularly shaped filamentous structures up to $2.5\ \mu$ in size (Fig. 1, 6) may be encountered. Their fate could not be determined.

The above-described observations have been made with a light microscope so that the interpretation given to various forms are not necessarily a true reflection of the development phases. It is anticipated that electron-microscopic studies would provide a reliable account that would also afford a more solid basis for a taxonomical grouping.

(c) Taxonomy

The acquired knowledge, though incomplete, on the morphology, habitat and biology of the Brazilian microorganism appears to be adequate for a tentative taxonomical evaluation. The intraerythrocytic parasite shows no differentiation of nucleus and cytoplasm. It is extremely polymorphic and possesses heteroxenous features and qualifies to be included in the phylum Protozoa, class Microsporidians and order Rickettsiales. Its heteroxenous character made it necessary to ascertain the occurrence of other related intraerythrocytic parasites harboured by avian hosts. A survey of the literature shows that only two named species, *Aegyptianella pullorum* CARPANO, 1928 and *Grahamella gallinarum* CARPANO, 1935, have been described in birds. *A. pullorum* is a heteroxenous parasite which has been recorded from the fowl, quail and turkey (order Galliformes), the duck and goose (order Anseriformes) and the ostrich (*Struthio camelus* L., order Struthioniformes). It appears that *G. gallinarum* has been only encountered in the fowl.

At this stage of the discussion it should be stated that CARPANO (1928) believed that *A. pullorum* is a protozoon and included it in the sporozoan family Piroplasmidae. However, electronmicroscopical studies by GOTHE (1967a) brought forward evidence that *A. pullorum* is a member of the class Microtatorbiotes. GOTHE (1967b) describes three developmental phases. During Phase 1 there appear round or oval compact initial bodies varying from $0.5\text{--}0.8\ \mu$ in size. In Phase 2 the growth of the $0.8\ \mu$ sized bodies continues, resulting in the development of round-, pear- or polygonal-shaped parasites of up to $3.2\ \mu$ in size. Nuclear material accumulates along the periphery or moves to one pole or alternatively divides and then shifts to each pole while in other instances the divided material settles on the opposite sides of the parasite where they assume a semilunar shape. This is followed by the development of small bodies of up to $0.8\ \mu$ in size within the parasite. Phase 3 is represented by $3.9\ \mu$ sized round or oval mature forms harbouring more than 4 and up to 16 small $0.5\text{--}0.7\ \mu$ sized initial bodies which after liberation invade other erythrocytes.

Comparison between the morphology of *A. pullorum* with that of the Brazilian parasite makes it apparent that the former organism is less polymorphous but much larger and more solid than the latter. Furthermore, the divisional form of Phase 2, which shows an accumulation of nuclear material at one or two sites, which is followed by the formation of individual small bodies within the parasite and the liberation of initial bodies by the mature form of Phase 3. Such phases have not been seen in the Brazilian microorganism which shows no differentiation of nucleus and cytoplasm. The divisional form appears as a filamentous structure in which the threads separate, divide and then contract to form round $0.2\text{--}0.3\ \mu$ sized "initial bodies". An invasion of erythrocytes by them has not been observed.

The rod-shaped forms of *G. gallinarum* are up to $3.0\ \mu$ in length and inhabit approximately 3% of the erythrocytes. Its structure is completely different from that of the Brazilian microorganism.

Consideration of the morphological features of the Brazilian intra-erythrocytic avian microorganism makes it apparent that these are distinct from those presented by the genera of the families Rickettsiaceae, Bartonellaceae, Anaplasmataceae and the genus *Aegyptianella*. The writers feel justified to conclude that it is a hitherto undescribed genus and species, for which the generic name *Neitzziella* and species name *rezendei* are proposed in honour of Prof. Dr. W. O. Neitz and Prof. Dr. H. E. B. de Rezende for their guidance, assistance and encouragement throughout the course of the investigations.

No attempt will be made to consider the family status of the parasite as it is anticipated that studies with an electronmicroscope will reveal a more detailed account of its morphological features for grouping.

Summary and Conclusion

1. An extremely polymorphous intraerythrocytic microorganism occurring in naturally infected turkeys, ducks and fowls has been discovered in the states of Minas Gerais, Rio de Janeiro and Espírito Santo.

2. Studies on the morphology and biology have shown that it is a hitherto undescribed heteroxenous parasite for which the name *Neitzella rezendei* gen. nov., sp. nov. is proposed.

3. Its morphological features permit its inclusion in the class Microtobiotes and order Rickettsiales.

4. Microscopical examination of blood films have shown that the parasitic carrier state in turkeys persists for more than 200 days (end-point not determined).

5. The natural mode of transmission needs to be determined.

6. The suspicion that the parasite may cause illthrift and deaths in poultry requires confirmation.

Acknowledgements

The writers wish to record their indebtedness to the farmers, mentioned in the text, for their cooperation and their donations of infected birds for research and to Dr. J. Langenegger for providing excellent facilities for the isolation of the above-mentioned birds. Thanks are also due to Mr. Waldir Jacintho de Silva for his technical assistance. Mr. A. M. du Bruyn, Veterinary Research Institute, Onderstepoort, is thanked for preparing the photomicrographs and Mrs. J. M. Vorster, Pretoria, South Africa, for typing the manuscript.

References

- CARPANO, M. (1928). Piroplasmosis in Egyptian fowls (*Aegyptianella pullorum*). – Bull. Minist. Agric. Egypt. 86, 1–12.
- CARPANO, M. (1935). Sur un nouveau microparasite du type *Grahamella-Rickettsia*, observé chez les poulets (*Grahamella gallinarum*). – Ann. Parasit. 13, 238–242.
- GOTHE, R. (1967a). Ein Beitrag zur systematischen Stellung von *Aegyptianella pullorum* Carpano, 1928. – Z. Parasitenk. 29, 119–129.
- GOTHE, R. (1967b). Untersuchungen über die Entwicklung und den Infektionsverlauf von *Aegyptianella pullorum* Carpano, 1928 im Huhn. – Z. Parasitenk. 29, 149–158.