

# **Immunological studies on onchocerciasis : varying skin hypersensitivity and leucocyte migration inhibition in a clinical spectrum of the disease**

Autor(en): **Ngu, J.L.**

Objektyp: **Article**

Zeitschrift: **Acta Tropica**

Band (Jahr): **35 (1978)**

Heft 3

PDF erstellt am: **12.07.2024**

Persistenter Link: <https://doi.org/10.5169/seals-312390>

## **Nutzungsbedingungen**

Die ETH-Bibliothek ist Anbieterin der digitalisierten Zeitschriften. Sie besitzt keine Urheberrechte an den Inhalten der Zeitschriften. Die Rechte liegen in der Regel bei den Herausgebern.

Die auf der Plattform e-periodica veröffentlichten Dokumente stehen für nicht-kommerzielle Zwecke in Lehre und Forschung sowie für die private Nutzung frei zur Verfügung. Einzelne Dateien oder Ausdrucke aus diesem Angebot können zusammen mit diesen Nutzungsbedingungen und den korrekten Herkunftsbezeichnungen weitergegeben werden.

Das Veröffentlichen von Bildern in Print- und Online-Publikationen ist nur mit vorheriger Genehmigung der Rechteinhaber erlaubt. Die systematische Speicherung von Teilen des elektronischen Angebots auf anderen Servern bedarf ebenfalls des schriftlichen Einverständnisses der Rechteinhaber.

## **Haftungsausschluss**

Alle Angaben erfolgen ohne Gewähr für Vollständigkeit oder Richtigkeit. Es wird keine Haftung übernommen für Schäden durch die Verwendung von Informationen aus diesem Online-Angebot oder durch das Fehlen von Informationen. Dies gilt auch für Inhalte Dritter, die über dieses Angebot zugänglich sind.

University Center for Health Sciences (C.U.S.S.), University of Yaoundé, Cameroon

## Immunological studies on onchocerciasis

### Varying skin hypersensitivity and leucocyte migration inhibition in a clinical spectrum of the disease

J. L. NGU

#### Summary

Soluble antigen was prepared from adult worms and microfilariae of *Onchocerca volvulus*. In 27 patients clinically characterized as having generalized type (17) and localized reactive type (10) onchocerciasis, the response to this antigen was assessed in vivo by skin testing and in vitro by leucocyte migration inhibition assay. Three varieties of skin hypersensitivity were observed: Immediate, Arthus-type and delayed or type IV hypersensitivity. The first 2 occurred in all patients, but type IV hypersensitivity was noted only in 10, eight of whom had localized reactive type onchocerciasis, whilst the other 2 had mild generalized lesions which had for the most part healed with treatment. The leucocyte migration inhibition assay showed a spectrum of responsiveness with significant inhibition in the presence of antigen in 8 patients with localized lesions and in 2 others with mild generalized disease which had largely healed. – The specificity of the skin reaction and leucocyte migration inhibition to the antigen used was confirmed by the results obtained when a control group of 18 subjects, with no evidence of previous filarial infection, was similarly tested. 16 of them showed no skin hypersensitivity and 2 had a doubtful immediate reaction. No significant inhibition of leucocyte migration in the presence of antigen was noted in this group.

*Key words:* localized reactive type onchocerciasis; generalized onchocerciasis; skin hypersensitivity; leucocyte migration inhibition; *Onchocerca volvulus*.

#### Introduction

Onchocerciasis often presents a spectrum of clinical and histopathological lesions, most clearly demonstrated in the skin manifestations of the disease. In

---

Correspondence: Prof. Dr. J. L. Ngu, University Centre for Health Sciences (C.U.S.S.), University of Yaoundé, Yaoundé, United Republic of Cameroon

the majority of patients in hyperendemic areas in Africa the disease is generalized and microfilariae of *Onchocerca volvulus* are easily demonstrable in skin snips. The common manifestations in this group are hyperpigmentation, lymphoedema, lymphadenopathy, papular eruptions from which clear fluid or pus may be extruded (gale filarienne) and atrophic skin in the late stages, with areas of depigmentation. The histological picture varies with the stage and type of lesion but constant features include increase of fibroblasts and reticulum fibres in the dermis, with acid mucosaccharide deposits and melanin within phagocytes.

In a small percentage of cases, the lesions are localized and typically involve one lower extremity only. The affected area is dark, thickened and intensely pruritic. The name, Sowda (Arabic for black), is used to describe this type which predominates in Yemen (Gasparini, 1962). Microfilaria are few and difficult to find except in full thickness skin biopsies of these lesions. Microscopically hyperkeratosis and acanthosis are prominent, but the most striking feature is the extensive inflammatory cell infiltrate of many plasma cells, fewer lymphocytes and a small number of histiocytes (Connor, 1974).

There are, however, many patients in hyperendemic areas with little or no itching and no obvious skin changes, despite demonstrable microfilariae infiltration of their skin (Anderson et al., 1974a).

The reasons for this diversity of clinical and histopathological picture are obscure. It has been proposed that this could be due to variation in the pathogenicity of infective larvae either within or between endemic areas (Duke and Anderson, 1972; Anderson et al., 1974b; Bryceson et al., 1976). An alternative hypothesis is that heterogeneity of host response to *O. volvulus* parasitization could perhaps account for the clinical spectrum. A similar situation exists in other chronic persistent infections such as syphilis and leprosy (Turk and Bryceson, 1971; Friedman and Turk, 1975), where the clinical picture parallels the immune response of the host.

In some of these infections, the specific immunity acquired is mediated through such effector responses as T-cell dependent cytotoxicity, lymphocyte-dependent antibody-mediated lysis and macrophage-dependent cytotoxicity. Failure of this cellular immunity, as occurs in leprosy or diffuse cutaneous leishmaniasis, is associated with organisms lying free throughout the tissues without any lymphocytic infiltrate (Turk and Bryceson, 1971). In addition there is no delayed hypersensitivity to specific antigens in these cases. In others, such as malaria, acquired immunity is primarily associated with specific antibodies. In onchocerciasis, however, the various roles of antibodies and T-cell mediated cellular immunity are still unclear. Although immune sera will cause complete immobilization in vitro of microfilariae of *O. volvulus* (Schiller – personal communication) there is evidence of involvement of antibodies in the pathogenesis of lesions (WHO Report, 1977). On the other hand, it has been suggested that the degree of containment of the infection parallels the cellular immune re-

sponse of the host (Ngu and Blackett, 1976). Quite clearly further studies are needed.

One method for assessing T-cell dependent cellular immunity is to assay products of activated T-lymphocytes. Inhibition of leucocyte migration (LMI) in the presence of antigen has been widely used for this purpose (Clausen and Søborg, 1969; Rosenberg, 1971; Søborg and Bendixen, 1967). We have therefore studied LMI and skin hypersensitivity to antigen of *O. volvulus* in patients clinically characterized as having either localized reactive type or generalized onchocerciasis, and also in healthy controls.

## Materials and methods

### *Patients* (Table 1)

Two groups of patients with onchocerciasis were studied. They comprised:

1. Seventeen with the generalized form of the disease. In three, Nos. 19, 26, 27, the disease was relatively mild in that most of the scabies had healed.

2. Ten with localized onchocerciasis affecting predominantly one limb or part of a limb, except patient 3 who had skin lesions in both lower limbs, and patient 5 whose dermatitis was in the left upper limb spilling over to the left shoulder and scapular region. Two of these were Europeans, patients 4 and 5, and the rest were Cameroonians. The diagnosis of onchocerciasis in this group was made primarily on clinical grounds, namely, pruritus and dermatitis. However, the subsequent observation that symptoms and signs were intensified at the beginning of treatment with diethylcarbamazine (DEC) and that the serum antibody titres were raised confirmed the diagnosis. In two cases complete remission was obtained with suramine and DEC therapy.

Informed consent was obtained from all the patients in this study.

### *Controls* (Table 2)

Eighteen healthy subjects from within Yaoundé were studied for comparison. Four of these were Europeans who had lived in Yaoundé for more than 18 months, 1 other was from Madagascar and the rest were Cameroonians, mainly students. None of them had had previously any symptoms suggestive of filariasis.

### *Clinical and paraclinical examinations*

The overt manifestations of onchocerciasis or lack of these were noted in all subjects. Skin snips taken with a corneo-scleral punch were immersed in saline and after a suitable interval microfilariae counts were made microscopically. Blood and stools were examined to establish the over-all parasitological profile.

### *Antigen preparation*

Live adult worms were teased out from onchocercomata using aseptic techniques. They were washed several times with normal saline and left immersed in it for ½ h. After centrifugation at 2000 rpm for 15 min the sediment of adult worms and microfilariae was transferred to sterile chilled mortar containing sterilized coarse sand and ground for 15 min in a deep freeze compartment. Cold distilled water was added to the mixture, stirred and left to stand for a few minutes. The supernatant was decanted and a drop of it examined microscopically. The fragments of adult worms and microfilariae in the suspension were then subjected to ultrasonic disintegration (Sonic Dismembrator, Artek, Framingdale, N.Y.) several 1 min bursts over a 15 min period followed by centrifugation at 5000 rpm for 15 min at 4° C. The supernatant was stored and the precipitate stirred continuously in 2M NaCl at 0° C for 60 min. This was then centrifuged at 5000 rpm for 30 min at 4° C. The supernatants were pooled and dialysed at 4° C for 24 h against several changes of distilled water.

Table 1. Clinical and parasitological profiles of patients studied

Patient, Age (yrs), sex	Microfilarial count/skin snip	Nodules	Other parasites					Previous therapy
			Asc.	Nec.	Tr.	LL.	Per.	
<i>Localized disease</i>								
1. 15, ♀	0	nil	+	+	-	-	+	DEC
2. 20, ♀	0	nil	nil					DEC
3. 14, ♀	0	nil	+	+	+	-	-	-
4. 43, ♂	0	nil	nil					DEC
5. 22, ♀	0	nil	nil					-
6. 27, ♀	1	nil	+	+	+	+	-	-
7. 38, ♂	2	nil	+	-	-	+	-	DEC
8. 38, ♂	0	nil	nil					DEC
9. 26, ♀	0	nil	nil					DEC
10. 30, ♀	0	nil	nil					DEC
<i>Generalized disease</i>								
11. 36, ♂	50	+	+	+	+	-	-	DEC
12. 40, ♀	38	+++	+	+	-	-	-	DEC
13. 60, ♂	40	++	+	+	-	+	+	DEC
14. 16, ♀	15	+	+	-	+	-	-	nil
15. 36, ♀	14	+	+	+	-	-	-	DEC
16. 28, ♂	80	++	-	-	+	-	-	DEC
17. 52, ♂	13	+	+	+	-	-	-	DEC
18. 35, ♂	31	+	-	+	-	-	-	nil
19. 40, ♂	12	-	+	+	+	-	+	nil
20. 12, ♂	34	+	-	+	+	-	-	nil
21. 27, ♂	25	-	nil					DEC
22. 56, ♂	27	+++	+	+	+	-	-	?
23. 38, ♀	111	+++	-	+	-	-	+	?
24. 36, ♀	240	+	-	+	+	+	-	nil
25. 40, ♂	120	++	nil					?DEC
26. 42, ♂	3	+	-	-	+	-	-	DEC
27. 34, ♀	1	-	nil					DEC

Asc. = *Ascaris lumbricoides*

LL. = *Loa loa*

Tr. = *Trichiuris trichiura*

Nec. = *Necator americanus*

Per. = *Dipetalonema perstans*

DEC = *Diethylcarbamazine*

The antigen dialysate was passed through a bacteriological filter, concentrated and its pH and protein content determined.

#### *Skin test*

0.05 ml of the antigen (protein content 1.08 mg/ml, pH 7.56) was injected intradermally into the volar aspect of the arm. The skin reactions were observed at 15 min, 30 min, 6 h, 24, 36, 48 and 72 h. Skin biopsies were taken at 6 h in 2 subjects, at 24 h in 1 and at 48 h in 3 others, 2 of whom had showed a delayed hypersensitivity reaction.

Table 2. Healthy Controls: Parasitological profile and results of skin hypersensitivity and leucocyte migration inhibition using *Onchocerca volvulus* antigen

Subject	Age (yrs), Sex	Microfilariae counts/skin snip	Other parasites	Skin reaction	Percentage migration
1.	24, ♀	nil	nil	negative	100
2.	24, ♀	nil	nil	negative	105
3.*	23, ♂	nil	nil	negative	94
4.	30, ♂	nil	Asc.	negative	85
5.	22, ♂	nil	nil	?imm	80
6.	27, ♂	nil	nil	negative	95
7.	28, ♂	nil	nil	negative	110
8.	24, ♀	nil	Tr.	negative	80
9.Δ	25, ♀	nil	nil	negative	95
10.Δ	23, ♂	nil	nil	negative	90
11.	31, ♂	nil	Asc.	?imm	85
12.	29, ♀	nil	nil	negative	85
13.Δ	30, ♀	nil	nil	negative	90
14.Δ	24, ♂	nil	nil	negative	88
15.	26, ♂	nil	nil	negative	100
16.	22, ♂	nil	nil	negative	105
17.	23, ♀	nil	nil	negative	100
18.	25, ♀	nil	nil	negative	85

Δ = European

\* = Madagascar

Asc. = *Ascaris lumbricoides*

Tr. = *Trichiuris trichiura*

?imm = Doubtful positive immediate hypersensitivity

#### *Enzyme linked immunosorbent assay (ELISA)*

The method of Bartlett et al. (1975) was adopted. Briefly, the cells in microhaemagglutination plates (Polystyrene) were sensitized with antigen at 37° C for 6 h and then washed with PBS/Tween. The test samples diluted 1/500 in PBS/Tween were added, left overnight at 4° C and washed as before. Any attached antibody was detected by incubation for 3 h with an alkaline phosphatase labelled antiglobulin, washing as before, and finally adding the enzyme substrate, P-nitrophenyl phosphate. The reaction was stopped with 3 M NaOH after 15 min. Spectrophotometric determination of the change in absorbance due to hydrolysis of the substrate was made at 405 nm.

Samples from patients or control subjects were analyzed simultaneously with three known negative control sera that had been collected and stored at -60° C a few months previously from expatriates who had never previously lived in the tropics.

#### *Leucocyte migration inhibition technique*

The method of Rosenberg and David (1971) was adapted with the following modifications: The heparinized blood was incubated at 37° C in a water bath to accelerate sedimentation. Migration experiments were carried out in Falcon sterile disposable dishes (3001, Fisher Scientific Co., Springfield, N.J.). RPMI was used as culture medium. The image of the migration fields was magnified and projected using Cooke's Microtitration Test reading mirror (Cooke Produkte AG), and then traced on transparent paper.

Cell viability was assessed in all cases by the exclusion of 0.2% trypan blue after the cells had been incubated with dye for 30 min at 37° C.



Antigen was used in a dilution of 1.08 mg protein per 5 cc of culture medium. Each test was performed in triplicate and all experiments were undertaken before skin testing and when patients had not been on any therapy for at least a week. Percentage migration in the presence of antigen was determined thus:

$$\frac{\text{Mean migration area with antigen}}{\text{Mean migration area without antigen}} \times 100$$

Some of the subjects were tested on two occasions.

## Results

### *Skin tests* (Tables 2 and 3)

Three varieties of reactions were encountered.

*Reaction 1:* By 15–30 min a wheal surrounded by a flare had appeared at the injection site. In a few, all of whom had extensive skin lesions, there was associated pruritus of mild to moderate intensity. The size of the wheal varied from 2–5 cm in the group with generalized disease, and from 0.4–2 cm in those with the localized form. The difference between the sizes of lesions in the 2 groups of patients was significant at the 5% level (Variance ratio test).

*Reaction 2:* The second reaction actually merged with the first and was evident at about 6 h. It had resolved by 24 h in most and in a few by 36 h. It was characterized by a diffuse swelling involving an area greater than that of the wheal with surrounding erythema. It was tender and warm. Biopsy of the swelling at 6 h, and at 24 h in one subject whose reaction was still evident at this time, showed marked oedema of the tissues with patches of cellular infiltration, predominantly polymorphs, seen interspersed with oedematous tissue. This reaction was thought to be of the Arthus-type.

Reactions 1 and 2 occurred in all patients although the reactions were more marked in the group with generalized than in those with localized reactive type onchocerciasis.

*Reaction 3:* This was observed in 10 patients 8 of whom had localized lesions whilst the remaining 2 had a mild form of generalized onchocerciasis. In nine of these an area of induration and palpable swelling was felt at the injection site at about 48 h and this gradually resolved over the subsequent weeks. There was no tenderness nor surrounding erythema (in fair skinned subjects). In a further patient, No 5, there was an overlap between reactions 2 and 3 at 48 h, but by 72 h reaction 2 had completely resolved leaving a well defined delayed hypersensitivity reaction. The skin indurations varied in size from 0.4–1.5 cm. There was no instance of necrosis. The histology of the biopsy of the lesion showed striking mononuclear cells perivascular infiltration (Fig. 1) typical of delayed hypersensitivity. The biopsy taken at 48 h in the patient with generalized onchocerciasis but with no delayed skin reaction by contrast did not show these findings.

Table 3. Results of skin hypersensitivity and leucocyte migration inhibition using *Onchocerca volvulus* antigen in patients

Patients, Age (yrs), Sex	Skin hypersensitivity			Percentage migration
	immediate (cm)	Arthus-type	delayed (cm)	
<i>Localized disease</i>				
1. 15, ♀	0.4	+	0.4	110
2. 20, ♀	0.8	+	1.5	40
3. 14, ♀	2.0	+	neg.	91
4. 43, ♂	1.4	+	0.7	63
5. 22, ♀	1.8	++	1.2	45
6. 27, ♀	1.8	+	1.0	67
7. 38, ♂	1.5	+	1.5	56
8. 38, ♂	0.9	+	1.3	58
9. 26, ♀	1.0	+	?+	78
10. 30, ♀	0.7	+	1.0	53
	<i>Mean</i> 1.23			<i>Mean</i> 66.1
	S.D. 0.54			S.D. 21.5
<i>Generalized disease</i>				
11. 36, ♂	2.8	+	neg.	90
12. 40, ♀	4.6	+	neg.	102
13. 60, ♂	2.0	+	neg.	78
14. 16, ♀	5.0	+	neg.	120
15. 36, ♀	4.8	+	neg.	108
16. 28, ♂	5.0	++	neg.	128
17. 52, ♂	5.0	++	neg.	97
18. 35, ♂	3.2	+	neg.	97
19. 40, ♂	3.0	+	neg.	85
20. 12, ♂	2.5	+	neg.	112
21. 27, ♂	4.0	++	neg.	102
22. 56, ♂	2.2	+	neg.	95
23. 38, ♀	4.0	++	neg.	108
24. 36, ♀	5.0	++	neg.	90
25. 40, ♂	2.3	+	neg.	82
26. 42, ♂	2.0	+	0.4	66
27. 34, ♀	2.5	+	0.6	62
	<i>Mean</i> 3.52			<i>Mean</i> 95.4
	S.D. 1.19			S.D. 18.3

+ = Positive

One of the patients with the localized disease, No. 3, had no delayed hypersensitivity and another, No. 9, had a doubtful positive reaction. The control group of subjects showed no hypersensitivity reaction to the antigen used except subjects 5 and 11 (Table 2) who had doubtful positive immediate reaction.



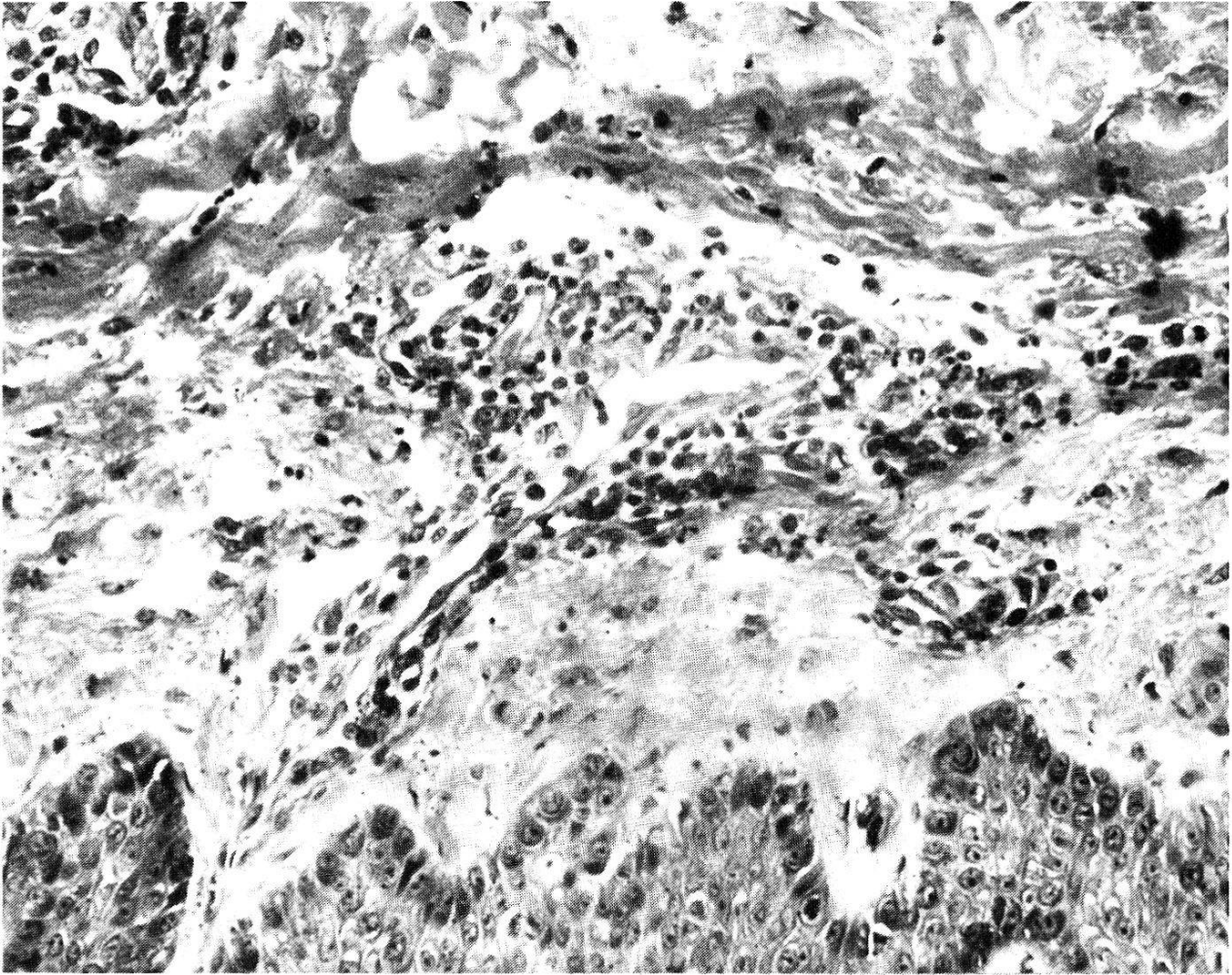


Fig. 1. Biopsy taken from injection site at 48 h in a patient with delayed hypersensitivity to *Onchocerca volvulus* antigen. Perivascular mononuclear cells infiltration can be seen. H. and E. Stain. Magnification  $\times 125$ .

#### *Leucocyte migration inhibition assay*

In all experiments the cell viability was more than 85%. The variations in the migration areas in the experiments performed in triplicate was from 5–10% and in 6 subjects the differences in results obtained on the 2 occasions of the test were from 3–15%. Details of percentage of mean migration of leucocytes in the presence of antigen in the patients are given in Table 3, and in healthy controls in Table 2.

The mean migration in patients with localized disease was 66.1% (standard deviation – S.D. 21.5%), and for those with generalized lesions 95.4% (S.D. 18.3%). The difference between the values of these two groups was highly significant ( $p < 0.005$  Student's *t* test). However, 3 of the subjects with generalized disease did show a percentage migration of less than 80% and in 2 of these most of the skin lesions had healed. Two subjects with localized lesions had normal percentage migration values; interestingly one of these 2 was the patient with no delayed hypersensitivity skin reaction.

The mean migration of leucocytes in the healthy controls was 88% (S.D.

10%). There was a significant difference between values from this group and those from patients with localized reactive-type onchocerciasis ( $p < 0.005$  Variance ratio test).

### ELISA

The antibody titres in the generalized disease ranged from 0.9–1.87 (mean 1.32) whereas in the localized disease the range was 0.65–1.27 (mean 0.86). The 3 known negative control sera had a range of 0.4–0.78 (mean 0.58), and the range in the 18 control subjects from Yaoundé was 0.35–0.86 (mean 0.67).

### Discussion

The results of this study clearly show that patients with onchocerciasis respond to challenge with *O. volvulus* antigen. Although immediate hypersensitivity to the antigen was evoked in all patients, Type IV (delayed) hypersensitivity response (classification of Coombs and Gell, 1968) clearly paralleled the clinical picture. Type IV reaction to *O. volvulus* antigen was on the whole associated with localized, rather than generalized, onchocerciasis indicating that cellular immunity is produced in the former and not the latter group of patients.

In man skin testing with the appropriate antigen is an important diagnostic test for cellular immunity. Leucocyte migration inhibition assay (LMI) has also been shown to be an in vitro correlate of T-cell dependent effector response (Rosenberg, 1971; Søborg and Bendixen, 1967). In this study although both parameters indicate broadly two groups of patients vis-a-vis T-cell dependent effector responses, the LMI assay shows a spectrum of responsiveness with overlapping between patients with localized and those with generalized form of the disease.

More than one hypersensitivity reaction can occur in the same subject. Thus animals infected with *Trypanosoma brucei* or *T. rhodesiense* exhibit both Arthus and delayed-type hypersensitivity (Tizard and Soltys, 1971). It is appreciated that the finding of positive reactivity at skin sites 24–48 h after testing does not necessarily equate with delayed-type hypersensitivity, since mononuclear chronic inflammatory cells can infiltrate sites damaged by strong immediate type or Arthus reactions. This is not likely to be the explanation for the delayed skin reactivity found in this series, since it occurred mainly in the subjects with localized reactive type onchocerciasis in whom immediate-type and Arthus reactions were less marked than in patients with generalized disease, who demonstrated no delayed-type hypersensitivity.

The role of cellular immunity in combating metazoal infections is known. Thus in *Litomosoides carinii* infection in rats, the acquisition of resistance is marked by adherence of lymphocyte and macrophages to microfilariae in the pleural cavity (Bagai and Subrahmanyam, 1970). In this series the loss of cellu-

lar immunity appears to be associated with the extensiveness and activity of infection.

We cannot explain why the patients with generalized lesions failed to demonstrate delayed hypersensitivity on intradermal challenge with *O. volvulus* antigen. Further, no antigen induced inhibition of leucocyte migration could be demonstrated in this group, additional indication of defective cell-mediated (Type IV) immune response. A similar failure has been reported in lepromatous leprosy, diffuse cutaneous leishmaniasis, kala-azar and syphilis, and in these situations organisms can be found free in tissues without any cellular infiltrate (Turk and Bryceson, 1971; Friedman and Turk, 1975).

Several explanations have been put forward for specific failure of cellular immune response. These include immune complexes inhibiting T-cell function (Hellstrom and Hellstrom, 1974), suppressor B cells (Katz et al., 1974), and parasite or its products inducing specific depression of cellular immune responses. Recently, Jayawardena and Waksman (1977) have demonstrated suppressor T-cells in other parasitic infections.

Circulating immune-complexes have been demonstrated in onchocerciasis (W.H.O. Technical Report, 1977), and in this study we have found higher levels of antibodies in generalized than in localized form of the disease. It is, however, not possible at present to define the precise mechanism(s) of the defective cell-mediated (Type IV) hypersensitivity.

There are other explanations to be considered for the localization of lesions in only some of the patients. The group with localized disease may not have been subjected to so constant and heavy a rate of infection with *O. volvulus* as the others. The two European patients in this series admit to only short periods of exposure to *Simulium damnosum* bites, which is in keeping with this view. The possibility of concurrent parasitic infections modifying the response to *O. volvulus* infection also has to be considered.

Further studies on host responses to various antigens of *O. volvulus*, and at various clinical stages of the disease are essential for a better understanding of the pathogenesis of onchocerciasis.

*Acknowledgment.* This study was supported by a grant from the World Health Organization. The author wishes to express his gratitude to Professor J. L. Turk of the Royal College of Surgeons of England for the photographs of the skin biopsy and his encouragement. The skillful technical assistance of Mrs. Bah is gratefully acknowledged.

- 1 Anderson J., Fuglsang H., Hamilton P. J. S., Marshall T. F. de C.: Studies on onchocerciasis in the United Cameroon Republic. I. Comparison of populations with and without *Onchocerca volvulus*. Trans. roy. Soc. trop. Med. Hyg. 68, 190–208 (1974a).
- 2 Anderson J., Fuglsang H., Hamilton P. J. S., Marshall T. F. de C.: Studies on onchocerciasis in the United Cameroon Republic. II. Comparison of onchocerciasis in rain-forest and Sudan-savanna. Trans. roy. Soc. trop. Med. Hyg. 68, 209–222 (1974b).
- 3 Bagai R. C., Subrahmanyam D.: Nature of acquired resistance to filarial infection in albino rats. Nature (Lond.) 228, 682–684 (1970).

- 4 Bartlett A., Bidwell D., Voller A.: Preliminary studies on the application of enzyme immunoassay in the detection of antibodies in onchocerciasis. *Tropenmed. Parasit.* 26, 370–374 (1975).
- 5 Bryceson A. D. M., van Veen K. S., Oduloju A. J., Duke B. O. L.: Antigenic diversity among *Onchocerca volvulus* in Nigeria and immunological differences between onchocerciasis in the savanna and forest in Cameroon. *Clin. exp. Immunol.* 24, 168–176 (1976).
- 6 Clausen J. E., Søborg M.: In vitro detection of tuberculin hypersensitivity in man. Specific migration inhibition of white blood cells from tuberculin-positive persons. *Acta med. scand.* 186, 227–235 (1969).
- 7 Connor D. H. jr.: Onchocerciasis – symptomatology, pathology, diagnosis (ed. by A. A. Buck), p. 10–14. World Health Organization, Geneva 1974.
- 8 Coombs R. R. A., Gell P. G. H. In: Clinical aspects of immunology (ed. by P. G. H. Gell and R. R. A. Coombs), 2nd ed. F. A. Davis Company, Philadelphia 1968.
- 9 Duke B. O. L., Anderson J.: Comparison of the lesions produced in the cornea of the rabbit eye by microfilariae of the forest and Sudan-savanna strains of *Onchocerca volvulus* from Cameroon. I. The clinical picture. *Tropenmed. Parasit.* 23, 354–368 (1972).
- 10 Friedmann P. S., Turk J. L.: A spectrum of lymphocyte responsiveness in human syphilis. *Clin. exp. Immunol.* 21, 59–64 (1975).
- 11 Gasparini G.: Surgical treatment of “sowda”. *Derm. trop.* 3, 43–47 (1975).
- 12 Hellstrom K. E., Hellstrom I.: Lymphocyte-mediated cytotoxicity and blocking serum activity to tumour antigens. *Advanc. Immunol.* 18, 209–277 (1974).
- 13 Jayawardena A. N., Waksman B. H.: Suppressor cells in experimental trypanosomiasis. *Nature (Lond.)* 265, 539–541 (1977).
- 14 Katz S. J., Parker D., Turk J. L.: B cell suppression of delayed hypersensitivity reactions. *Nature (Lond.)* 251, 550–551 (1974).
- 15 Ngu J. L., Blackett K.: Immunological studies on onchocerciasis in Cameroon. *Trop. geogr. Med.* 28, 111–120 (1976).
- 16 Rosenberg S. A., in: In vitro methods in cell-mediated immunity (ed. by B. R. Bloom and P. R. Glade), p. 19–20. Academic Press, New York/London 1971.
- 17 Rosenberg S. A., David P. R.: In vitro assay for inhibition of migration of human blood leucocytes. In: In vitro methods in cell-mediated immunity (ed. by B. R. Bloom and P. R. Glade), p. 297–300. Academic Press, New York/London 1971.
- 18 Søborg M., Bendixen G.: Human lymphocyte migration as a parameter of hypersensitivity. *Acta med. scand.* 181, 247–254 (1967).
- 19 Tizard J. R., Soltys M. A.: Cell-mediated hypersensitivity in rabbits infected with *Trypanosoma brucei* and *T. rhodesiense*. *Infect. Immunol.* 4, 674–681 (1971).
- 20 Turk J. L., Bryceson A. D. M.: Immunological phenomena in leprosy and related diseases. *Advanc. Immunol.* 13, 209 (1971).
- 21 W.H.O. Technical Report Series 606: The role of immune complexes in disease, p. 16–17. W.H.O., Geneva 1977.

