

Report of a case of a giant phytobezoar in a patient with a duodenal bulb ulcer

Autor(en): **Rashed-Mohassel, M.A.**

Objektyp: **Article**

Zeitschrift: **Acta Tropica**

Band (Jahr): **35 (1978)**

Heft 4

PDF erstellt am: **14.09.2024**

Persistenter Link: <https://doi.org/10.5169/seals-312401>

Nutzungsbedingungen

Die ETH-Bibliothek ist Anbieterin der digitalisierten Zeitschriften. Sie besitzt keine Urheberrechte an den Inhalten der Zeitschriften. Die Rechte liegen in der Regel bei den Herausgebern. Die auf der Plattform e-periodica veröffentlichten Dokumente stehen für nicht-kommerzielle Zwecke in Lehre und Forschung sowie für die private Nutzung frei zur Verfügung. Einzelne Dateien oder Ausdrucke aus diesem Angebot können zusammen mit diesen Nutzungsbedingungen und den korrekten Herkunftsbezeichnungen weitergegeben werden. Das Veröffentlichen von Bildern in Print- und Online-Publikationen ist nur mit vorheriger Genehmigung der Rechteinhaber erlaubt. Die systematische Speicherung von Teilen des elektronischen Angebots auf anderen Servern bedarf ebenfalls des schriftlichen Einverständnisses der Rechteinhaber.

Haftungsausschluss

Alle Angaben erfolgen ohne Gewähr für Vollständigkeit oder Richtigkeit. Es wird keine Haftung übernommen für Schäden durch die Verwendung von Informationen aus diesem Online-Angebot oder durch das Fehlen von Informationen. Dies gilt auch für Inhalte Dritter, die über dieses Angebot zugänglich sind.

Pahlavi Hospital, Tehran, Iran

Report of a case of a giant phytobezoar in a patient with a duodenal bulb ulcer

M. A. RASHED-MOHASSEL

Summary

A case of a large phytobezoar (750 g weight and with the length of 29 cm) due to Khormalou (Persimmon) is being reported in a young patient with chief complaint of abdominal pains and concomitant duodenal ulcer. Review of the literature in this subject shows that bezoars of this size and weight are relatively rare in healthy individuals.

Key words: giant phytobezoar; duodenal ulcer; case study.

Introduction

The term bezoar has been known in the Orient for many centuries, and according to the foundations and conceptions of mythology it was believed to be an essential remedy against poison. From an etymological viewpoint, certain authors refer to its origin in the Hebrew word “Beluzaar” [1] and others recall the persian word “Padzahr” or “Badzahr” which means “against poison” [2, 3].

Actually the bezoar is the general term for foreign bodies and the intragastric concretions composed of vegetable residu, food material and hair [1, 2, 4–7]. These bezoars are relatively rare in a healthy and nonoperated stomach [2]. We have recently observed a giant phytobezoar in a young student with a duodenal ulcer which we are going to report and then discuss its etiology, pathology and therapeutic problems.

Case report

Patient M. R. B. I., a 22-year-old student who weighs 64 kg and is 170 cm tall presented himself to us in December 1975 with epigastric pains when time to eat (hunger pains). These pains were diminished by ingesting a meal. In his past medical history, he recalls episodes of epigastric burning

Correspondence: Prof. M. A. Rashed, M.D., Medicine 3 Service, Pahlavi Hospital, Bayat Avenue, Tehran, Iran

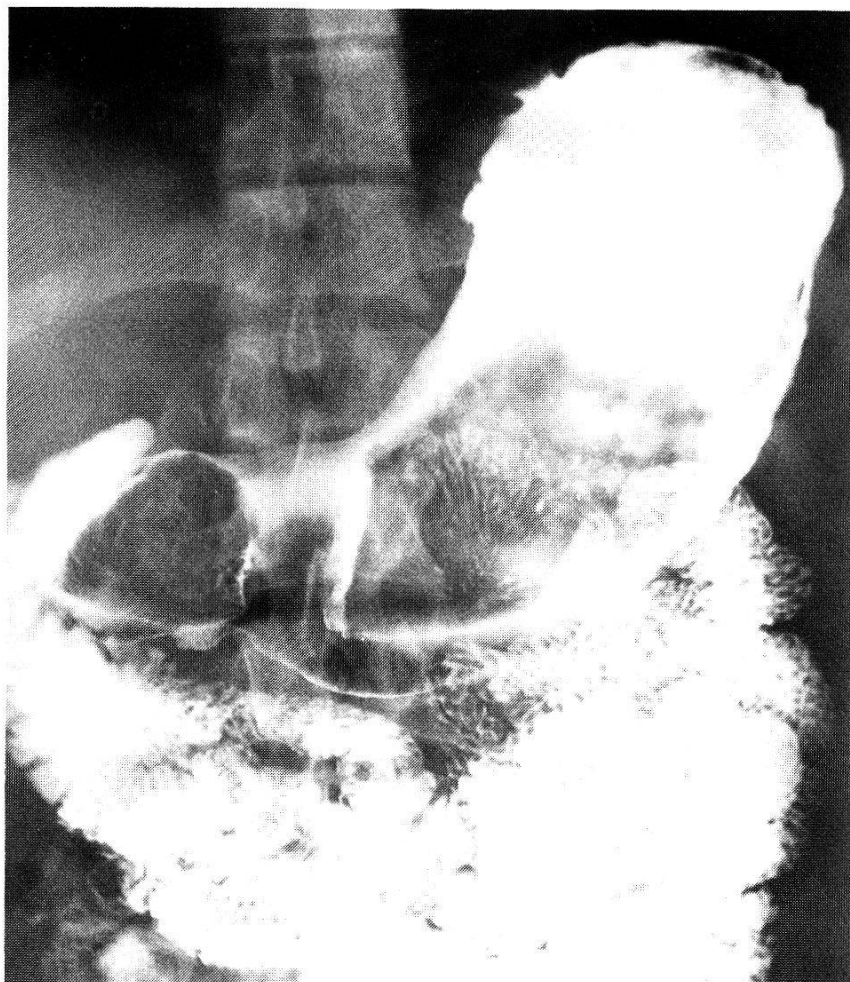


Fig. 1

and also a melena which lasted 24 h. In addition he had the habit of eating close to 1 kg of Kormalou (a type of Persimmon, resembling a tomato in size which is cultivated and raised in the central region of Iran "Yazd"), for almost 6 years.

During the clinical examination, the abdomen was supple to palpation and we found a mass more or less mobile situated in the left epigastric region and was not painful. The upper G.I. series showed an area of filling defects covering close to $\frac{3}{4}$ of the gastric cavity and permitting the barium to pass through by the periphery of the tumor in order to reach the pylorus (Fig. 1).

The gastroscopic examination was done and it was verified that a hard and greenish mass, composed of vegetable material, had invaded all the gastric cavity which did not permit the passage of the gastroscope through the antro-pyloric region. The air contrast study proved that there was not any adhesion present between the mass and the stomach wall. All the laboratory values were normal. We elected not to remove the mass by medical or instrumental methods for two reasons: the type and rigidity of the tumor.

Surgical intervention was done. A midline incision was made above the umbilicus and gastrostomy was performed. A greenish mass which weighed 750 g was carefully removed from the stomach. It was made up of two parts: a small part situated in the antral region and another larger part invading the body of the stomach. The length of the tumor was 29 cm (Fig. 2).

The postoperative course was uncomplicated. The patient left the hospital one week after the operation, and clinical symptoms were diminished. The pathological examination of the removed specimen confirmed the vegetable origin of the bezoar (Fig. 3).

One month later, the patient came back to us complaining of episodes of rhythmic and periodic pains.




Fig. 2

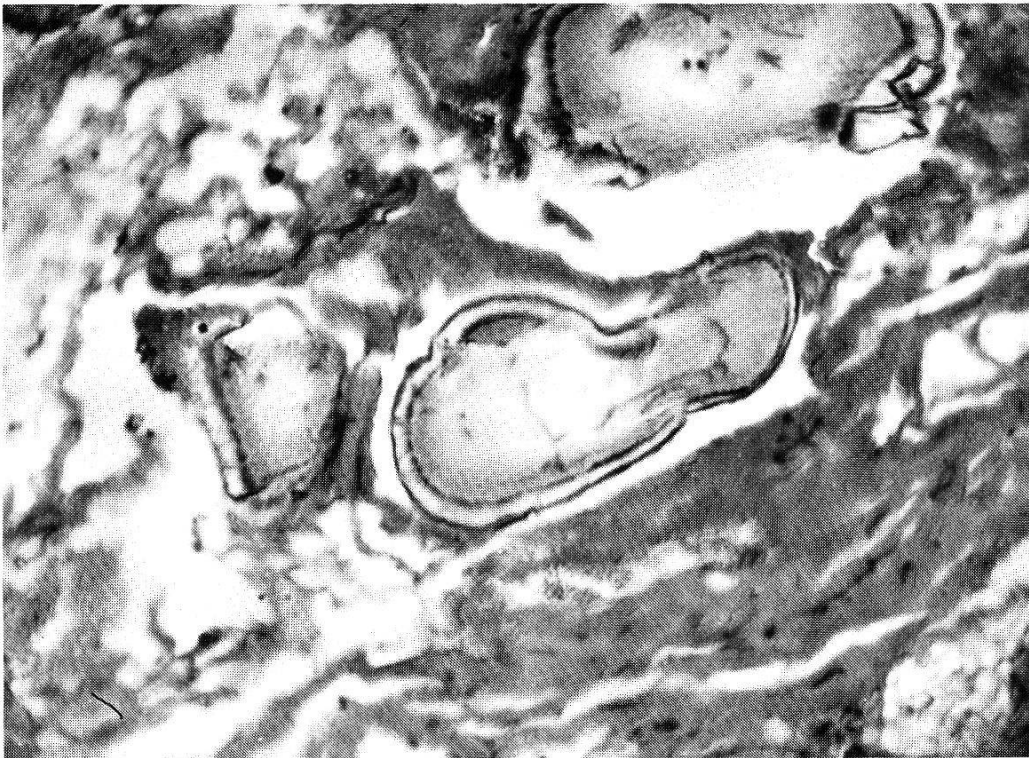


Fig. 3

An upper G.I. series performed in February 1976 showed an apparently normal stomach and the existence of an ulcer in the duodenal bulb. Gastroscopy was done which showed a normal appearing gastric mucosa. Gastric secretion analysis showed a volume of 60 ml (2.88 mEq/h) in 1 h and acid concentration of 48 mEq/l. The response to histamine was normal (100 ml/h or 5.00 mEq/h). Other laboratory results were as follows: hemoglobin 16.5 g%, hematocrit 49.0%, white blood cells 8200/mm³ with neutrophils 60%, eosinophils 3%, basophils 0%, band cells 1%, lymphocytes 34%, monocytes 2%. The patient was started on metoclopramide and antacids. His condition on discharge was satisfactory. Repeat gastroscopy showed a healed duodenal ulcer.

Discussion

The phytobezoar has been reported relatively rarely until recent years (311 cases until 1938 [2]). Its frequency appears to be increasing due to the fact that surgical intervention of the stomach has become more frequent in our times [8]. The first medical observation dates back to 1845 by Quin, and first surgical removal in 1854 by Schreiber [9].

In a nonoperated stomach the majority of cases are occupational and professional in origin, such as phytobezoar, lactobezoar, etc. [2, 5, 10], or trichobezoar made up of hair in an emotionally disturbed adult or child who habitually pulls out hair and swallows it [6, 7].

Predisposing factors

In a healthy stomach a diet rich in vegetable fibers has a special place in the formation and genesis of phytobezoars; the undigested debris of fruits form a primary nucleus of the bezoar [4, 9]. In DeBakey's series 40.4% were of phytobezoars of which the Persimmon formed the central core [2]. In our patient, excessive ingestion of Kormalou plays a role of primary importance in the formation of giant phytobezoars. This bezoar is presently at the Museum of Anatomical Pathology, Institute of Taj Pahlavi, Tehran, Iran.

Klein [12] reported a case of phytobezoar in a vegetarian suffering from a stomach ulcer.

Hypoacidity, pyloric stenosis, reduction in gastric motility are also predisposing factors for bezoar formation [13]. In our case, however, the patient had only a duodenal bulb ulcer without stenosis and with an acid secretion at the upper limit of normal. The gastric motility was well preserved. The only contingency that remains is the excessive ingestion of Khormalou which is covered by a rind full of Tannin which has not been well chewed. We can compare our case with Gilat's whose patient drank the juice of three grapefruits for several months.

Treatment

The treatment of a phytobezoar consists of enzymatic dissolution "cellulase or papain" [13–15]; occasionally in adding some pineapple [16], the endoscopic destruction [4], direct injection of the enzyme by endoscopy in the interior

of the bezoar [17], and finally in the case of failure surgical intervention is inevitable. In our patient, we did not even try the medical and instrumental approaches because at the time of endoscopy the rigidity of this voluminous bezoar was verified. In addition, the crushing of this mass could have caused serious complications [19]; such as intestinal obstruction, gastric hemorrhage, etc. [10]. Among the late complications of bezoars one can mention gastrointestinal fistulas and anemia [18]. One case of protein losing enteropathy also has even been reported in a patient carrying a bezoar which disappeared after removal of the bezoar [19].

- 1 Cocheton J. J., Poulet J.: Histoire des bézoards. De la croyance légendaire à la pathologie humaine. *Sem. Hôp. Paris* 49, 3581–3586 (1973).
- 2 Debakey M., Ochsner A.: Bezoars and concretions. A comprehensive review of the literature with an analysis of 303 collected cases and a presentation of eight additional cases. *Surgery* 5, 132–160 (1939).
- 3 Hillemand P.: *Maladie de l'estomac de l'œsophage et de duodénum*, p. 797–806. Flammarion, Paris 1967.
- 4 Rozen P., Gilat T.: Enzymatic softening and endoscopic destruction of a phytobezoar in an unoperated stomach. *Amer. J. Gastroent.* 64, 397–399 (1975).
- 5 Wexler H. A., Poole C. A.: Lactobezoar – a complication of overconcentrated milk formula. *J. pediat. Surg.* 11, 261–262 (1976).
- 6 Walls L. L.: Trichobezoar. *Ohio St. med. J.* 72, 287–289 (1976).
- 7 Lal M. M., Dhall J. C. L.: Trichobezoar: a collective analysis of 39 cases from India with a case report. *Indian J. Pediat.* 12, 351–353 (1975).
- 8 Perttala Y., Peltokallio P., Leivika T., Sipponen J.: Yeast bezoar formation following gastric surgery. *Amer. J. Roentgenol.* 125, 365–373 (1975).
- 9 Poulet J., Cochetron J. J.: Une affection gastro-entérologique méconnu. *Sem. Hôp. Paris* 50, 2935–2943 (1974).
- 10 Eurine M.: *Les bézoards de laque chez les buveurs de vernis*. Thèse, Paris 1935.
- 11 Schreiber H., Filston H. C.: Obstructive jaundice due to gastric trichobezoar. *J. pediat. Surg.* 11, 103–104 (1976).
- 12 Klein M., Baek S. M., Kim U.: A phytobezoar in an adult. *M. Sin. J. Med.* 43, 388–390 (1976).
- 13 Deal D. R., Vital P., Raffin S. B.: Dissolution of a postgastrectomy bezoar by cellulase. *Gastroenterology* 64, 467–470 (1973).
- 14 Stanten A., Peters H. H.: Enzymatic dissolution of phytobezoars. *Amer. J. Surg.* 130, 259–261 (1975).
- 15 Brette R., Jeanblanc F.: Traitement d'un phytobézoar postopératoire par la cellulase. *Nouv. Presse méd.* 42, 3011 (1975).
- 16 Feffer J., Norton R. A.: Dissolution of phytobezoar using pineapple juice. *J. Amer. med. Ass.* 236, 1578 (1976).
- 17 Gold M. H., Patteson T. E., Green G. L.: Cellulase bezoar injection: a new endoscopic technique. *Gastrointest. Endoscopy* 22, 200–202 (1976).
- 18 Harris V. J., Hanley G.: Unusual features and complications of bezoars in children. *Amer. J. Roentgenol.* 123, 742–745 (1975).
- 19 Valberg L. S., McCorrison J. R., Partington M. W.: Bezoar: unusual cause of protein-losing gastroenteropathy. *Canad. med. Ass. J.* 942, 338–392 (1968).