

Zeitschrift: Acta Tropica
Herausgeber: Schweizerisches Tropeninstitut (Basel)
Band: 40 (1983)
Heft: 2

Artikel: Oriental hornet venom enhances wound healing and repair in rat skin, possibly through its collagenolytic activity
Autor: Dayan, D. / Barr-Nea, L. / Sandbank, M.
DOI: <https://doi.org/10.5169/seals-313126>

Nutzungsbedingungen

Die ETH-Bibliothek ist die Anbieterin der digitalisierten Zeitschriften. Sie besitzt keine Urheberrechte an den Zeitschriften und ist nicht verantwortlich für deren Inhalte. Die Rechte liegen in der Regel bei den Herausgebern beziehungsweise den externen Rechteinhabern. [Siehe Rechtliche Hinweise.](#)

Conditions d'utilisation

L'ETH Library est le fournisseur des revues numérisées. Elle ne détient aucun droit d'auteur sur les revues et n'est pas responsable de leur contenu. En règle générale, les droits sont détenus par les éditeurs ou les détenteurs de droits externes. [Voir Informations légales.](#)

Terms of use

The ETH Library is the provider of the digitised journals. It does not own any copyrights to the journals and is not responsible for their content. The rights usually lie with the publishers or the external rights holders. [See Legal notice.](#)

Download PDF: 09.01.2025

ETH-Bibliothek Zürich, E-Periodica, <https://www.e-periodica.ch>

¹ Department of Pathology and Section of Oral Pathology and Oral Medicine, School of Dental Medicine, Tel Aviv University, Tel Aviv, Israel

² Department of Histology and Cell Biology, Sackler School of Medicine, Tel Aviv University, Tel Aviv, Israel

³ Department of Dermatology, Sackler School of Medicine, Tel Aviv University, Tel Aviv, Israel

⁴ Hard Tissues Unit, Ichilov Hospital, Tel Aviv, Israel

⁵ Dental Research Center, University of North Carolina, Chapel Hill, North Carolina, USA

⁶ Department of Physiology and Pharmacology, Sackler School of Medicine, Tel Aviv University, Ramat Aviv, Israel

Oriental hornet venom enhances wound healing and repair in rat skin, possibly through its collagenolytic activity*

D. DAYAN¹, L. BARR-NEA², M. SANDBANK³, I. BINDERMAN⁴,
G. L. MECHANIC⁵, J. S. ISHAY⁶

Summary

Oriental hornet (*Vespa orientalis*) venom sac extract (VSE) was topically applied to experimental wounds produced on the back skin of rats in order to observe histologically its effect on the healing process. In other studies the collagenolytic effect of VSE was investigated. The results clearly indicated that application of VSE enhanced the process of wound healing. Two weeks after wound induction a thick epidermis and maturation of the dermal connective tissue were seen in the experimental animals, whereas in the controls the dermis was thin and still showed granulation tissue, and the epidermis was thin. Incubation of VSE with purified neutral salt-soluble collagen (NSSC) labeled by reduction with [³H]NaBH₄ brought about degradation of the substrate. It is assumed that VSE enhances the process of wound healing in the skin, probably due to its collagenolytic effect.

Key words: *Vespa orientalis* venom; wound healing; collagenase.

* This research was partially supported by the I. Katzenelbogen Research Fund.

Correspondence: D. Dayan, D.M.D., M.Sc., Section of Oral Pathology and Oral Medicine, School of Dental Medicine, Tel Aviv University, Ramat Aviv 69978, Israel

Introduction

The histologic lesions induced by arthropod stings have two distinct components: an epidermal transformation characterized by pseudoepitheliomatous hyperplasia, and a dermal inflammatory infiltration consisting either of necrotizing lesions with abundant eosinophils or of dense lymphocytic infiltration (Allen, 1948, 1967; Horen, 1972).

The local reaction to Oriental hornet (*Vespa orientalis*) sting comprises either an acute necrotizing inflammation or a pseudolymphomatous dermal infiltration (Barr-Nea et al., 1976; Barr-Nea and Ishay, 1977). Ederly et al. (1972) studied the pharmacologic activity of this venom and detected the presence of protease, hyaluronidase and histamine. The present study examined the contribution of hornet venom to wound healing, possibly brought about by its collagenase content.

Materials and Methods

Histologic studies

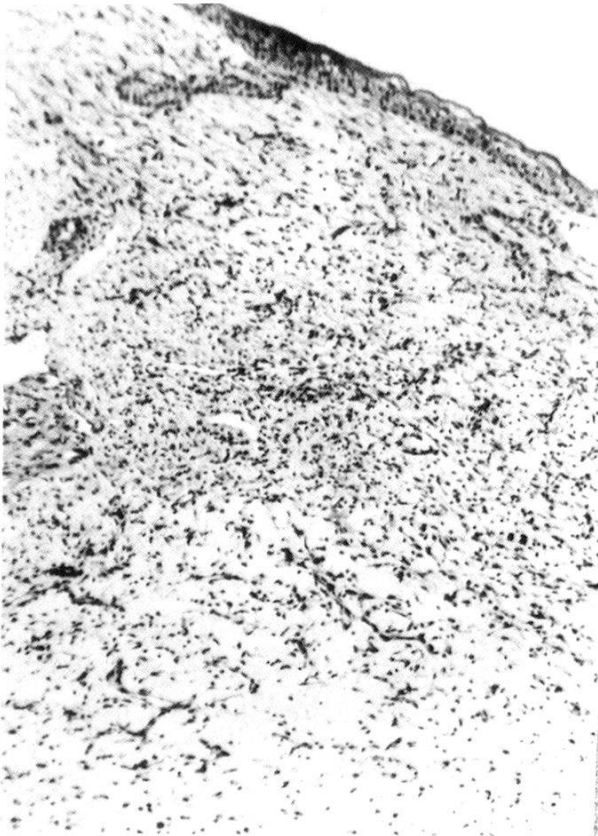Venom sac extract (VSE) was prepared as previously described (Ishay, 1975). Thirty-two male Charles-Rivers rats, aged four months, were used in the study, each receiving a skin wound by a 3-mm punch. In 16 of the animals (group I – controls) 0.25 ml saline was dropped daily onto the wound and then a biopsy specimen was taken from a different pair of rats on days 2, 3, 7 and 14 after the wounding. In the remaining 16 animals (group II) 0.25 ml VSE was dropped daily on the wounds and biopsy specimens were again taken at exactly the same days as before. The biopsy material was fixed in 10% neutral buffered formalin, embedded in paraffin, and sections 6 μ thick were then stained with hematoxylin-eosin, van Gieson's stain and Masson trichrome stain and Alcian blue for mucopolysaccharides (MPS) (Lillie, 1954).

Biochemical procedures

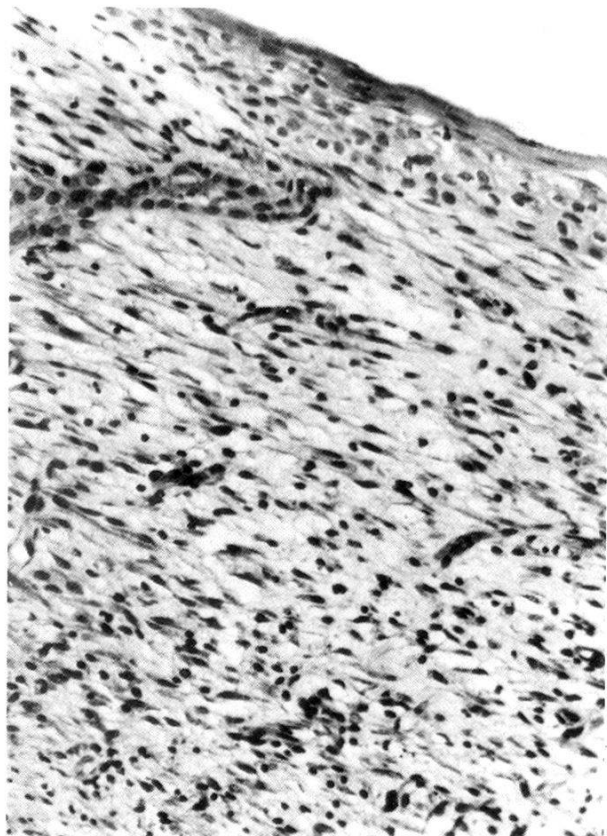
Purified salt-extracted [³H] collagen was prepared by the reduction of purified collagen with [³] NaBH₄ according to the method described by Fukae and Mechanic (1980). The specific activity of the radiolabeled collagen was 1.5×10^6 CPM/mmol. The VSE was added to 0.05 ml [³H] collagen in Eppendorf tubes to a final volume of 0.5 ml (0.02 M Tris-HCl buffer, pH 7.4, 0.001 M CaCl₂). Samples were incubated for 24 h and for 21 days, and experiments were repeated three times. After incubation the samples were centrifuged in the warm and counted with a Liquid Scintillation Spectrometer (Packard, Tri-Carb 3255). Scintillation counts per minute (CPM) in the supernatant represented collagen breakdown. Examination of the samples indicated no collagenolytic bacterial contamination. Positive controls for digestion were prepared using bacterial *Clostridium* collagenase (type III, Advanced Biofactures, Inc., Lynwood, N.Y.).

Results

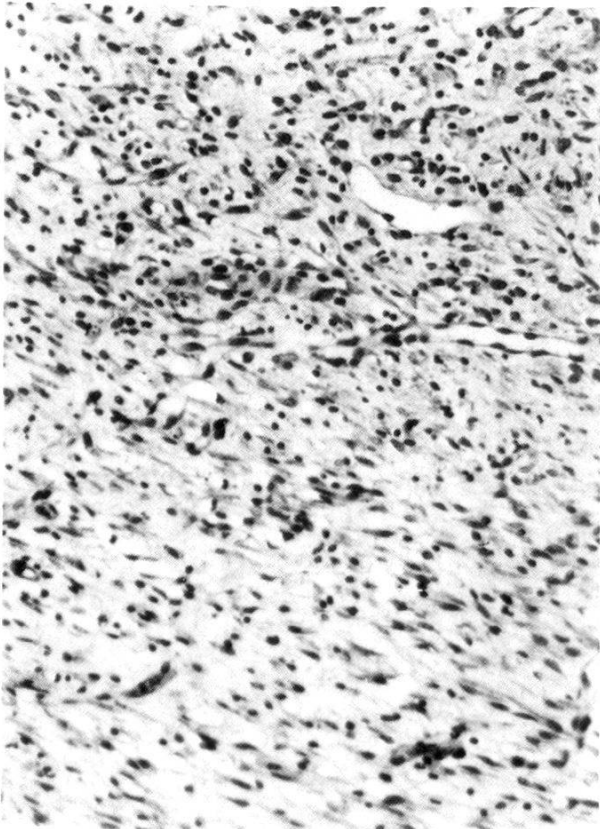
Histologic follow-up of the lesions indicated that the hornet VSE induced more rapid wound healing in the skin. Thus, one week after induction of the wound the dermis in the control animals was rather irregular and thin (Figs. 1, 2), whereas in the experimental animals it was thick and hyperkeratotic, with



1



2



3

Fig. 1. Control rat skin, one week after wound induction. The skin has a thin, irregular epidermis, and in the dermis there are granulation tissue and numerous chronic inflammatory cells. H&E; $\times 70$.

Fig. 2. Control skin, after one week (higher magnification of Fig. 1). The skin has a thin epidermis, irregular epithelial cells without polarity, young granulation tissue, fibroblasts irregularly dispersed and chronic inflammatory cells. H&E; $\times 140$.

Fig. 3. Control skin, after one week. The skin has young granulation tissue and loose connective tissue with thin-walled blood vessels and chronic inflammatory cells. H&E; $\times 140$.

Table 1. Degradation of [³H]-labeled collagen by whole venom sac extract (VSE)

	Relative collagenolytic activity*	
	After 1 day incubation	After 21 days incubation
Buffered substrate	1	1
<i>Clostridium</i> collagenase 0.99%	6.06	8.42
Venom sac extract (VSE)	3.37	3.68

* Relative collagenolytic activity = $\frac{\text{CPM of enzymatic activity in sample}}{\text{CPM of buffered substrate}}$

hair follicles also present (Figs. 4, 5). The connective tissue of the rats treated with venom was well developed, with abundant Alcian blue-positive material, showing bundles of collagen fibers, mature fibroblasts and minimal inflammation and granulation tissue (Fig. 5). On the other hand, in the controls there was an abundance of chronic inflammatory cells, only a small amount of Alcian blue-positive material, young granulation tissue, loose connective tissue, thin-walled blood vessels and irregularly dispersed fibroblasts (Figs. 2, 3). Only two weeks after wound induction could the onset of connective tissue maturation be seen in the controls, the dermis showing granulation tissue and new, more mature collagen fiber formation and abundant Alcian blue MPS (Fig. 6), while the dermis was still thin. In the venom-treated rats, in contrast, normal dermis could be discerned within two weeks of wound induction, and hair follicle formation was evident. Also observed was scar formation with abundant, thick collagen fibers, but no inflammatory or granulation tissue (Fig. 7).

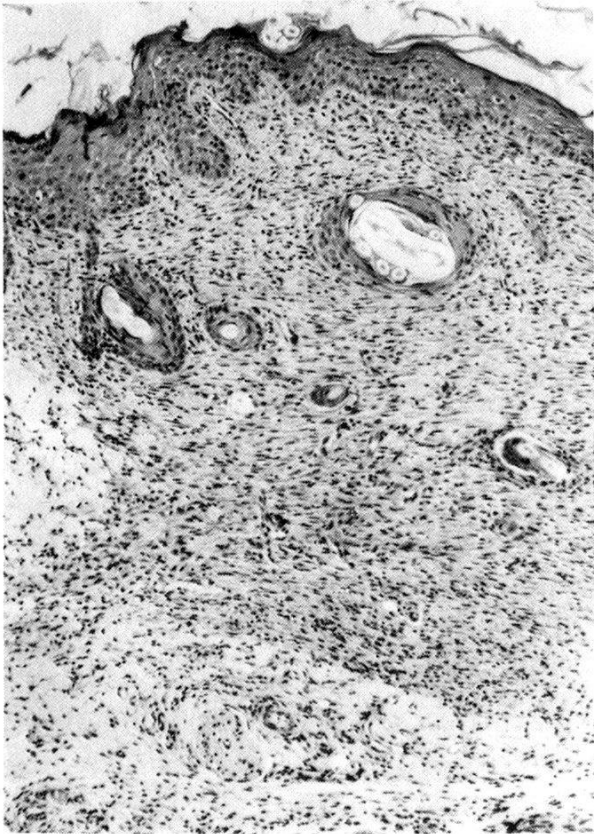
Biochemical studies on [³H]-labeled collagen that was incubated with VSE demonstrated the degradation of the collagen substrate (Table 1). This indicates that VSE has collagenolytic activity. After incubation for 24 h the collagenolytic activity of the VSE reached almost maximum, or 55% of bacterial (*Clostridium*)

Fig. 4. VSE-treated rat skin, one week after wound induction. The skin has a thick epidermis and hyperkeratosis around hair follicles. Connective tissue developed with fibrosis. Note minimal inflammation, granulation and vascularization. H&E; × 170.

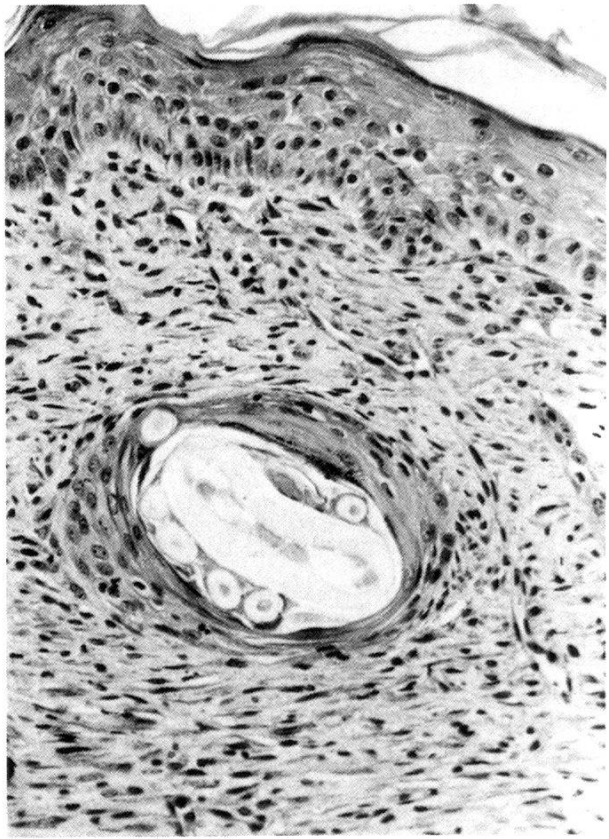
Fig. 5. VSE-treated skin, after one week (higher magnification of Fig. 4). There is a well developed epidermis and well developed connective tissue showing fibroblasts and collagen fibers. H&E; × 175.

Fig. 6. Control skin, after two weeks. There is a thin epidermis. The dermis shows few collagen fibers and granulation tissue with vascularization and remnants of inflammatory cells. H&E; × 140.

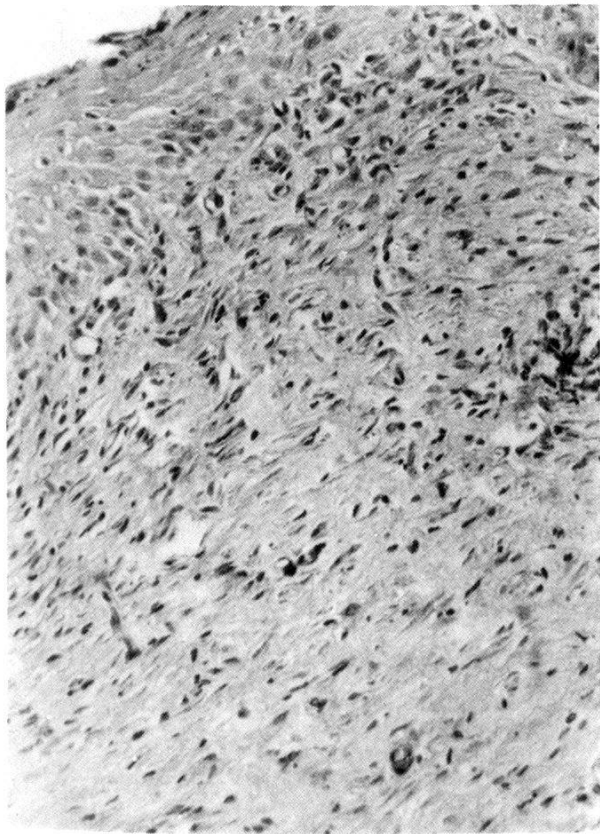
Fig. 7. VSE-treated skin, after two weeks. The epidermis and hair follicles are well developed. The dermis shows scar formation, abundant thick collagen fibers, no inflammation and no granulation tissue. H&E; × 175.



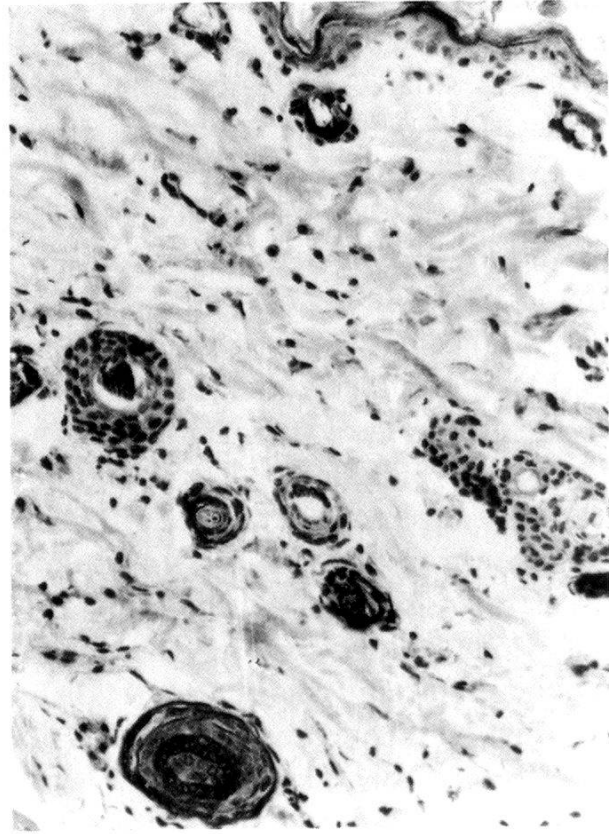
4



5



6



7

collagenase activity. After incubation for 21 days, there was no significant change in the collagenolytic activity of the venom, which now comprised 43% of the corresponding bacterial collagenase activity.

Discussion

We have previously shown (Barr-Nea et al., 1976; Sandbank et al., 1978) that injection of Oriental hornet venom into the dermis of the back of mice induced pseudolymphoma which persisted unchanged for a period of one year or produced acute necrotizing inflammation.

In the present study, Oriental hornet venom sac extract (VSE) was topically applied to the skin of rats after wound induction with a punch. Histologic examination clearly revealed that such application of VSE to wounds enhanced their healing, in comparison with control wounds treated with saline. Untreated control wounds, without either VSE or saline, remain to be studied, however.

It is now known (Pollack, 1979) that following wounding and consequent blood clot formation the adjacent blood vessels become leaky, probably owing to release of vasoactive substances from injured tissue. This causes increased blood flow to the wound, leading to the availability of substances and nutrients that will later be required in the healing process.

In a previous study (Edery et al., 1972) we have demonstrated the presence of vasoreactive substances in whole hornet venom, so these could presumably contribute to enhanced tissue repair following wounding. Furthermore, in the same study, we showed the presence in hornet venom of different proteolytic enzymes, such as protease and hyaluronidase. As already known (Shoshan and Gross, 1974), different enzymes are required in tissue necrolysis, which is an important obligatory antecedent to repair. Ishay (1975) and other authors (Ishay et al., 1972; Fischl et al., 1972) described the preparation of venom sac extract (VSE), which may have different relative enzymatic activities than those found in whole venom. In the present study, the topical application of VSE could conceivably have raised the concentration of such enzymes (e.g. protease and hyaluronidase), thereby contributing to repair. Collagenase is believed to participate in the general enzymatic activities known to occur early in the healing process (Raekallio, 1970), and indeed bacterial collagenase has been successfully applied to experimentally induced second and third degree burns and to excision wounds, causing complete necrolysis after 24 h and consequently accelerated healing (Zimmerman et al., 1972; Shoshan and Gross, 1974).

Collagenolytic activity has been demonstrated also during mammalian wound repair and this in association with epithelial cell movements and wound contraction (Grillo and Gross, 1967; Grillo et al., 1969).

Presumably the collagenase activity either frees epithelial cells for migration or facilitates cellular movement in the connective tissue that has been newly formed during wound healing and repair. Our biochemical studies indi-

cate the presence of collagenolytic activity in VSE, and therefore it is possible that collagenase together with other factors in the hornet VSE promotes wound healing and repair.

- Allen A. C.: Persistent "insect bites" (dermal eosinophilic granulomas) simulating lymphoblastomas, histiocytoses and squamous cell carcinomas. *Amer. J. Path.* 24, 367–387 (1948).
- Allen A. C.: Reactions to arthropods. In: *The skin*, ed. by A. C. Allen, p. 561–568. Grune & Stratton, New York 1967.
- Barr-Nea L., Ishay J.: Histopathological changes in mouse and rat skin injected with venom sac extracts of the Oriental hornet (*Vespa orientalis*). *Toxicon* 15, 301–306 (1977).
- Barr-Nea L., Sandbank M., Ishay J.: Pseudolymphoma of skin induced by Oriental hornet (*Vespa orientalis*) venom. *Experientia (Basel)* 32, 1564–1565 (1976).
- Edery H., Ishay J., Lass Y., Gitter S.: Pharmacological activity of Oriental hornet (*Vespa orientalis*) venom. *Toxicon* 10, 13–23 (1972).
- Fischl J., Ishay J., Goldberg S., Gitter S.: Investigation of protein fractions and haemolytic properties of wasp venom. *Acta pharmacol. (Kbh.)* 31, 65–70 (1972).
- Fukae M., Mechanic G. L.: Maturation of collagenous tissue. Temporal sequence of formation of peptidyl lysine-derived cross-linking aldehydes and cross-links in collagen. *J. biol. Chem.* 255, 6511–6518 (1980).
- Grillo H. C., Gross J.: Collagenolytic activity during mammalian wound repair. *Develop. Biol.* 15, 300–317 (1967).
- Grillo H. C., McLennan J. E., Wolfort F. G.: Activity and properties of collagenase from healing wound in mammals. In: *Repair and regeneration. The scientific basis for surgical practice*, ed. by J. E. Dunphy and W. Van Winkle jr., p. 185–197. McGraw-Hill, New York 1969.
- Horen W. P.: Insect and scorpion sting. *J. Amer. med. Ass.* 221, 894–898 (1972).
- Ishay J.: Hyperglycemia produced by *Vespa orientalis* venom sac extract. *Toxicon* 13, 221–226 (1975).
- Ishay J., Fischl J., Gitter S.: Investigation of wasp venom: antigenic relationship. *Acta pharmacol. (Kbh.)* 31, 71–74 (1972).
- Lillie R. D.: *Histopathologic technic and practice in histochemistry*. Blackiston, New York 1954.
- Pollack S. V.: Wound healing: a review. *J. derm. Surg. Oncol.* 5, 389–393 (1979).
- Raekallio J.: Enzyme histochemistry of wound healing. *Prog. histochem. Cytochem.* 1, 51–151 (1970).
- Sandbank M., Barr-Nea L., Ishay J.: Pseudolymphoma of skin induced by Oriental hornet (*Vespa orientalis*) venom. Ultrastructural study. *Arch. derm. Res.* 262, 135–141 (1978).
- Shoshan S., Gross J.: Biosynthesis and metabolism of collagen and its role in tissue repair processes. *Israel J. med. Sci.* 10, 537–561 (1974).
- Zimmerman W. E., Oehlert W., Dietrich F. E.: Der Kollagenase-Effekt auf die durch Antibiotica-therapie verzögerte Nekrolyse bei Verbrennungswunden. *Res. exp. Med.* 157, 244–246 (1972).

