

Electron-microscopic localization of "Trypanosoma brucei gambiense" transmitted by "Glossina morsitans centralis" in "Microtus montanus"

Autor(en): **Rudin, W. / Pongponratn, E. / Jenni, L.**

Objektyp: **Article**

Zeitschrift: **Acta Tropica**

Band (Jahr): **41 (1984)**

Heft 4

PDF erstellt am: **12.07.2024**

Persistenter Link: <https://doi.org/10.5169/seals-313309>

Nutzungsbedingungen

Die ETH-Bibliothek ist Anbieterin der digitalisierten Zeitschriften. Sie besitzt keine Urheberrechte an den Inhalten der Zeitschriften. Die Rechte liegen in der Regel bei den Herausgebern.

Die auf der Plattform e-periodica veröffentlichten Dokumente stehen für nicht-kommerzielle Zwecke in Lehre und Forschung sowie für die private Nutzung frei zur Verfügung. Einzelne Dateien oder Ausdrucke aus diesem Angebot können zusammen mit diesen Nutzungsbedingungen und den korrekten Herkunftsbezeichnungen weitergegeben werden.

Das Veröffentlichen von Bildern in Print- und Online-Publikationen ist nur mit vorheriger Genehmigung der Rechteinhaber erlaubt. Die systematische Speicherung von Teilen des elektronischen Angebots auf anderen Servern bedarf ebenfalls des schriftlichen Einverständnisses der Rechteinhaber.

Haftungsausschluss

Alle Angaben erfolgen ohne Gewähr für Vollständigkeit oder Richtigkeit. Es wird keine Haftung übernommen für Schäden durch die Verwendung von Informationen aus diesem Online-Angebot oder durch das Fehlen von Informationen. Dies gilt auch für Inhalte Dritter, die über dieses Angebot zugänglich sind.

¹ Swiss Tropical Institute, Basel, Switzerland

² Faculty of Tropical Medicine, Mahidol University, Bangkok, Thailand

Electron-microscopic localization of *Trypanosoma brucei gambiense* transmitted by *Glossina morsitans centralis* in *Microtus montanus*

W. RUDIN¹, E. PONGPONRATN², L. JENNI¹

Summary

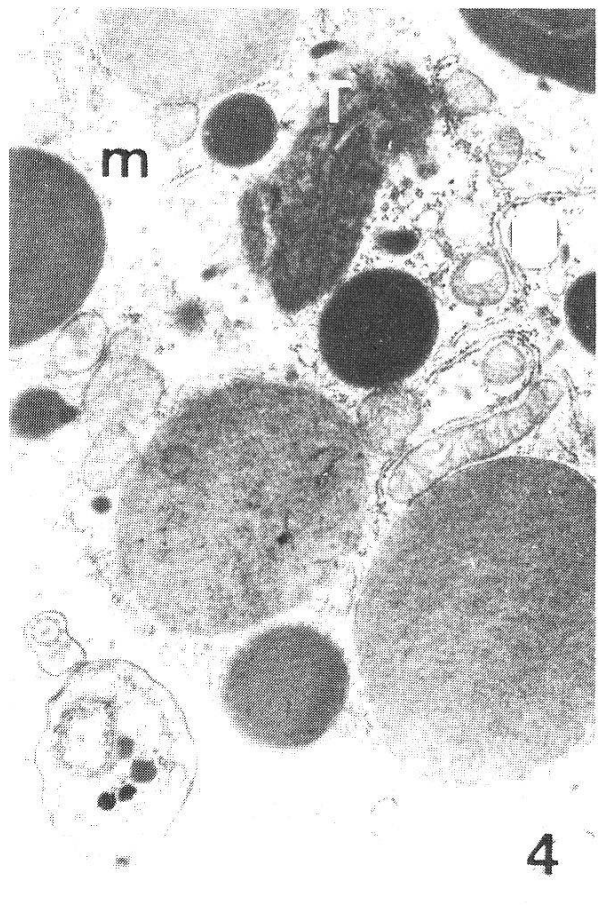
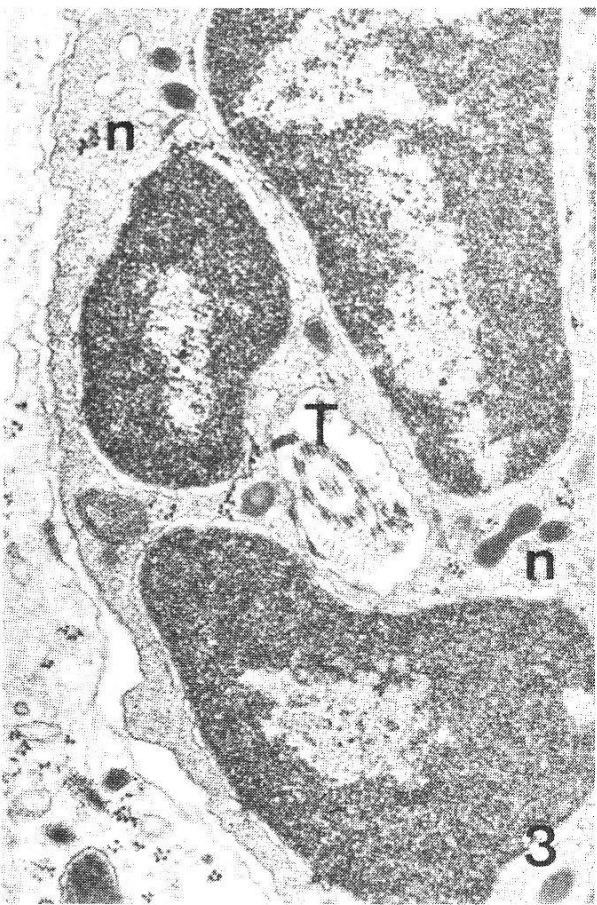
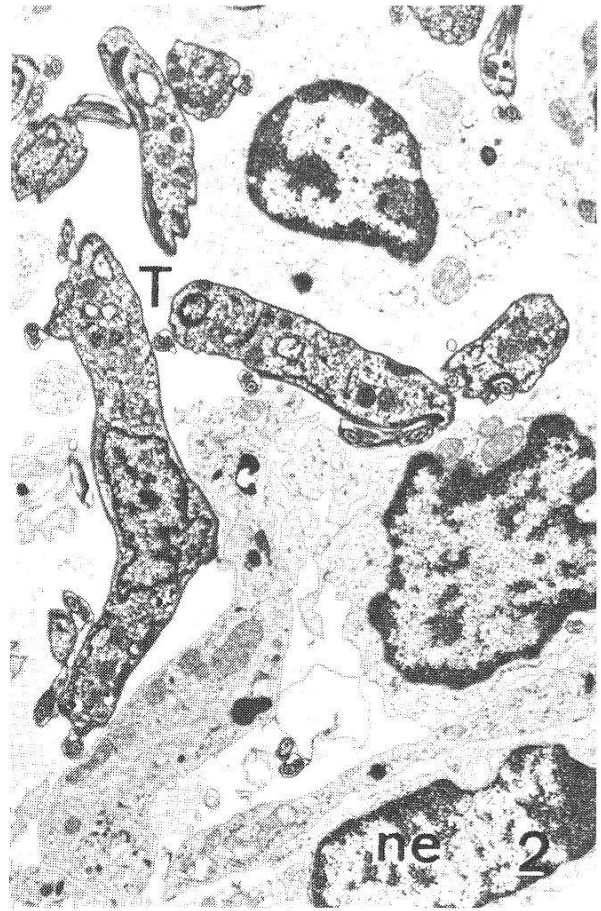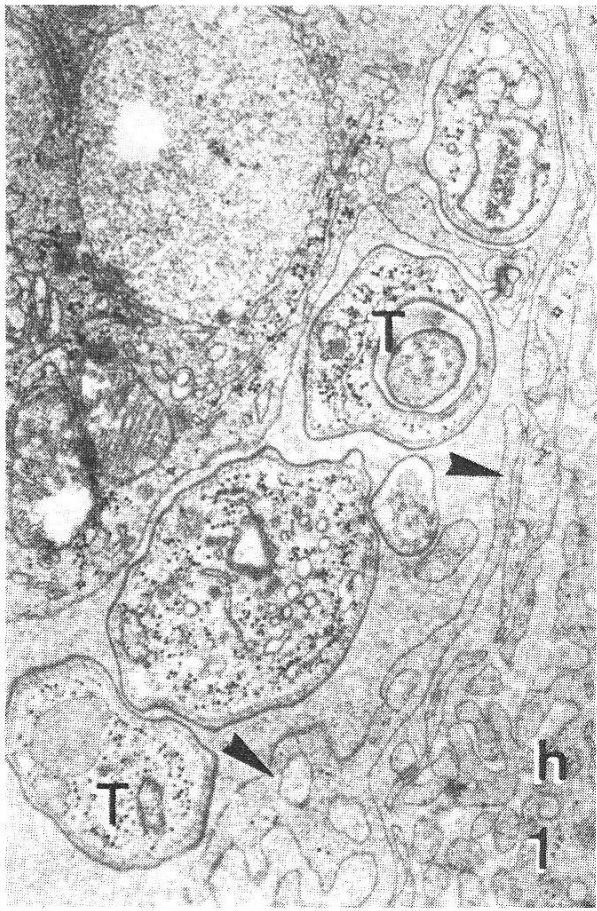
In *Microtus montanus* infected with *T. b. gambiense*, electron microscopic examination of lymph nodes, spleen, liver, heart, choroid plexus and brain demonstrated extravascular populations of trypanosomes distributed throughout interstitial spaces, accompanied by a moderate cellular infiltration of plasma cells. The trypanosomes exhibited numerous profiles; some were dividing, others were in different stages of lysis, or phagocytosed. Penetration of trypanosomes into hepatocytes was observed. The present investigation indicated that trypanosomes migrated to the brain parenchyma from the Virchow-Robin spaces but could not confirm whether the parasites reached the Virchow-Robin spaces by traversing the ependymal cells lining the choroid plexus or by migrating through the endothelial cells of the cerebral blood vessels.

Key words: trypanosomiasis; *Trypanosoma b. gambiense*; *Microtus montanus*; extravascular population; brain; fine structure.

Introduction

When considering the efficacy of chemotherapy and the question of drug resistance, the presence of trypanosomes in extravascular niches in mammalian hosts is of great importance. In addition to a number of light microscopical investigations, several authors (Stevens and Moulton, 1977; Poltera et al., 1980; Tanner et al., 1980; van Marck et al., 1981; Abolarin et al., 1982; Jenni et al., 1983; Rudin et al., 1983) have described the ultrastructure of extravascular

Correspondence: Dr. W. Rudin, Swiss Tropical Institute, Socinstrasse 57, CH-4051 Basel, Switzerland



trypanosomes (*Trypanozoon*) and their distribution in different animal models and organs. From their results it is evident that the number of trypanosomes in the tissues is fairly constant during the course of infection, in contrast to the number in the blood which fluctuates widely. Where and how the parasites enter and leave the circulatory system is unknown. In addition, ultrastructural studies have revealed the presence of structurally intact trypanosomes within host cells, e.g. hepatocytes (Jenni et al., 1983), plasma cells (Rudin et al., 1983; van Marck, pers. comm.), and ependymal cells (Abolarin et al., 1982).

The aim of this investigation was to extend preliminary investigations (Jenni et al., 1983; Rudin et al., 1983) about extravascular distribution of *Trypanosoma b. gambiense* in *Microtus montanus* infected by tsetse transmission. Two main questions concerning the distribution of trypanosomes were addressed: which trypanosomes are likely to be responsible for relapses after chemotherapy and how do trypanosomes pass the blood-brain-barrier.

Material and Methods

Trypanosoma b. gambiense TH DAL 069/78E was isolated by Dr. D. Mehlitz, Hamburg, from a patient in the Ivory Coast in 1978. Pupae of *Glossina morsitans centralis* were received from Dr. S. K. Molloo, ILRAD, Nairobi, Kenya. They were kept at 28° C and 80% r.h. until eclosion.

Inbred *Microtus montanus*, originating from the outbred colony of Prof. J. R. Seed, Texas A. & M. University, USA, and weighing 30 g were used. At the age of about six weeks, four animals were cyclically infected by a single infective tsetse bite. Two animals were used for the EM study and dissected 30 days after infection when parasitaemia was low. The other two were used for the isolation of trypanosomes in a late stage. The gross pathology was evaluated and samples of lymph nodes, spleen, heart, liver, brain stem, and the choroid plexus of the fourth ventricle were prepared for electron microscopy (Rudin et al., 1983).

Results

T. gambiense DAL 069 caused a chronic infection in *M. montanus* similar to that already observed for the strain TH 3/78 (031) (Jenni et al., 1983; Rudin et al., 1983). The parasitaemia remained low for the duration of the infection with a heavy increase before death. *M. montanus* infected with DAL 069 showed abnormal contraction of the hind legs to the body when lifted by the tail (Poltera et al., 1982) already within two to three weeks.

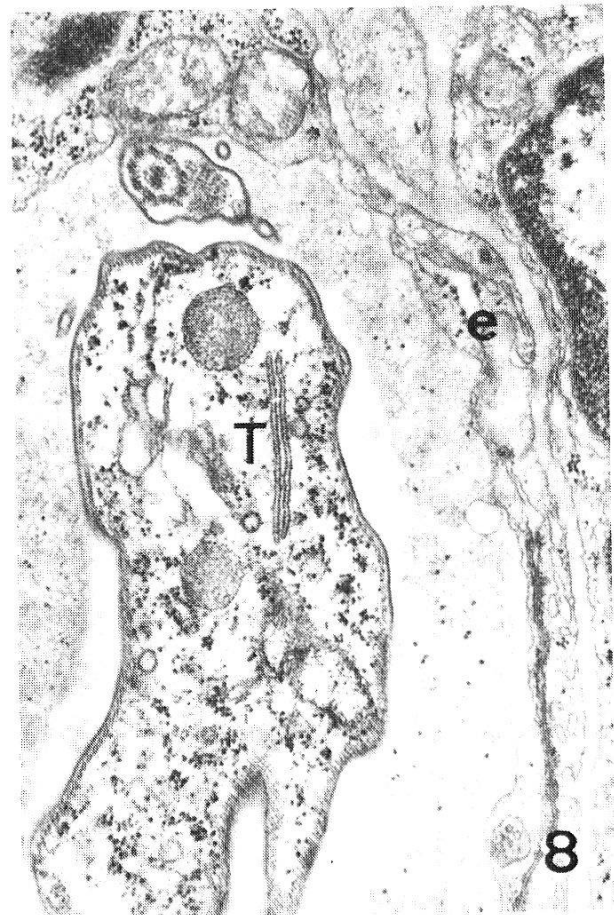
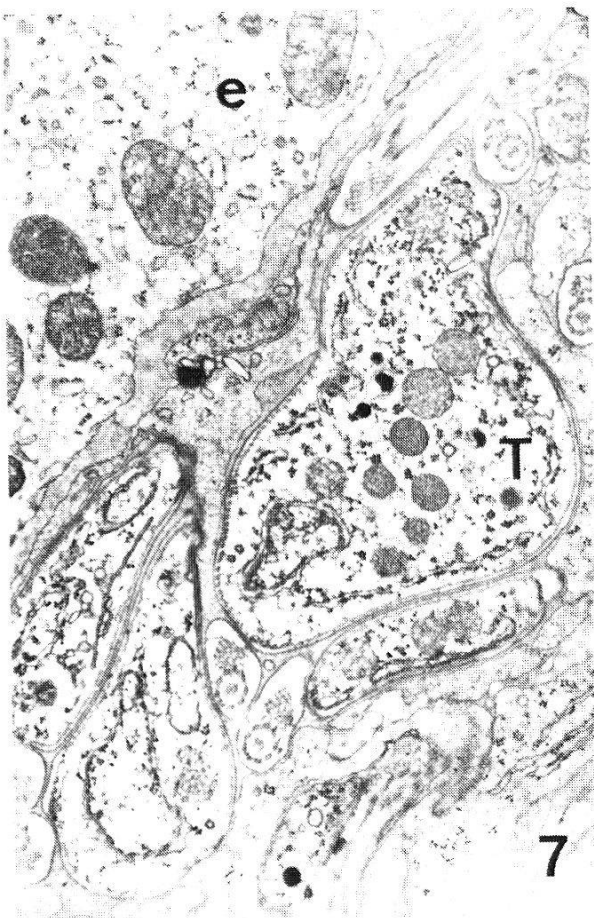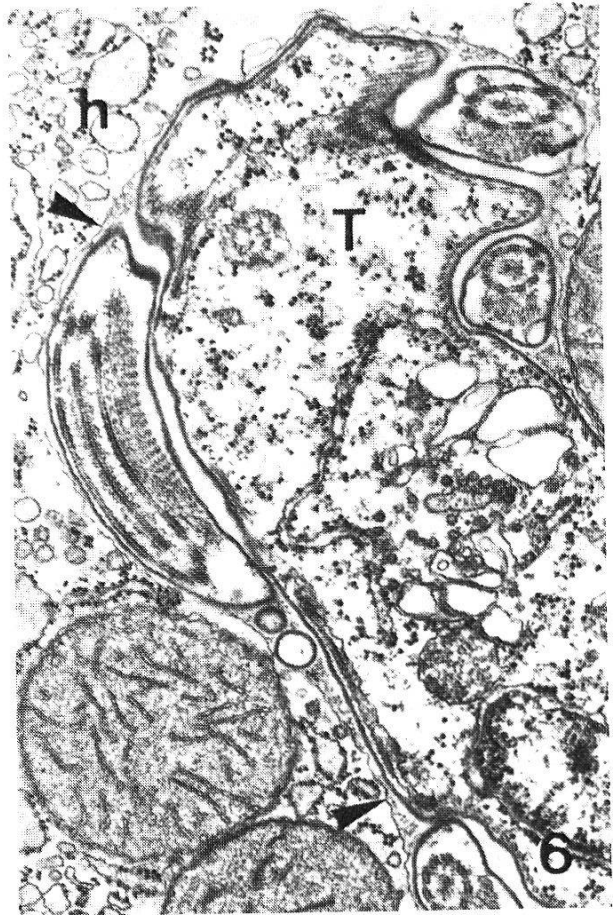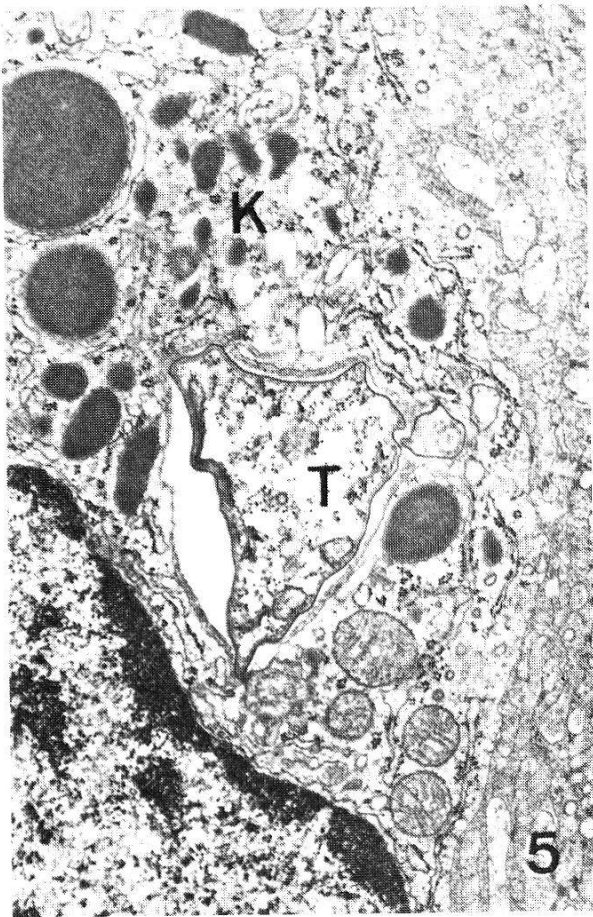
Gross pathological findings: the most conspicuous finding was pronounced enlargement of the spleen in combination with a marked congestion. Similar changes were found in the lymph nodes, but to a lesser degree. Also the liver

Fig. 1. *T. b. gambiense* in liver sinusoid of *M. montanus* (h = hepatocyte, T = trypanosome, ► = endothelium). ×19000.

Fig. 2. Extravascular parasites (T) in the lymph node (ne = nucleus of endothelial cell). ×5400.

Fig. 3. Trypanosome (T) in the spleen phagocytosed by a neutrophile granulocyte (n). ×23000.

Fig. 4. Trypanosome (T) in the spleen phagocytosed by a macrophage (m). ×14000.



appeared slightly congested. In the heart and the brain no macroscopically detectable lesions were found.

Electron microscopy: the frequency of trypanosome profiles in capillaries was similar in all organs investigated. In accordance with the relatively low parasitaemia, parasites were found only occasionally. A slightly higher density was observed in the sinusoids of the liver (Fig. 1), spleen, and lymph nodes. A structural interaction between trypanosomes and endothelial cells was not detected.

It was much easier to find trypanosomes within the interstitial spaces around capillaries, especially near the sinusoids of liver, spleen, and lymph nodes (Fig. 2). In all extravascular sites, parasites were found in division or undergoing degeneration and destruction. Phagocytosis of trypanosomes (Figs. 3–5) was observed in all extravascular locations; the cell types responsible included neutrophile granulocytes (Fig. 3), macrophages (Fig. 4), and in the liver sinusoids, Kupffer cells (Fig. 5). Extracellular fragments of trypanosomes were frequently found in the spleen. In one animal, trypanosomes were observed within hepatocytes (Fig. 6). Occasionally, the structure of the liver cells and the parasites appeared to be altered. The rough endoplasmic reticulum of the infected hepatocytes appeared vesiculated in a cytoplasm only loosely packed with organelles. In some cases, the trypanosomes were surrounded by a membrane and contained numerous, polymorphic, light vacuoles. In others they lay free in the cytoplasm.

The distribution of the parasites in the choroid plexus corresponded to that in other organs. A larger number of trypanosome profiles was found within the interstitial spaces between the capillaries and the ependyma (Fig. 7) than within the blood vessels. Extravascularly, they were concentrated in irregularly distributed foci.

The only part of the brain screened for the presence of trypanosomes was the brain stem. Parasites were found in the following locations: i) capillaries and interstitial spaces of the meninges, ii) capillaries entering the brain tissue and the Virchow-Robin spaces, and iii) brain tissue, between cells and axons (Figs. 8–10).

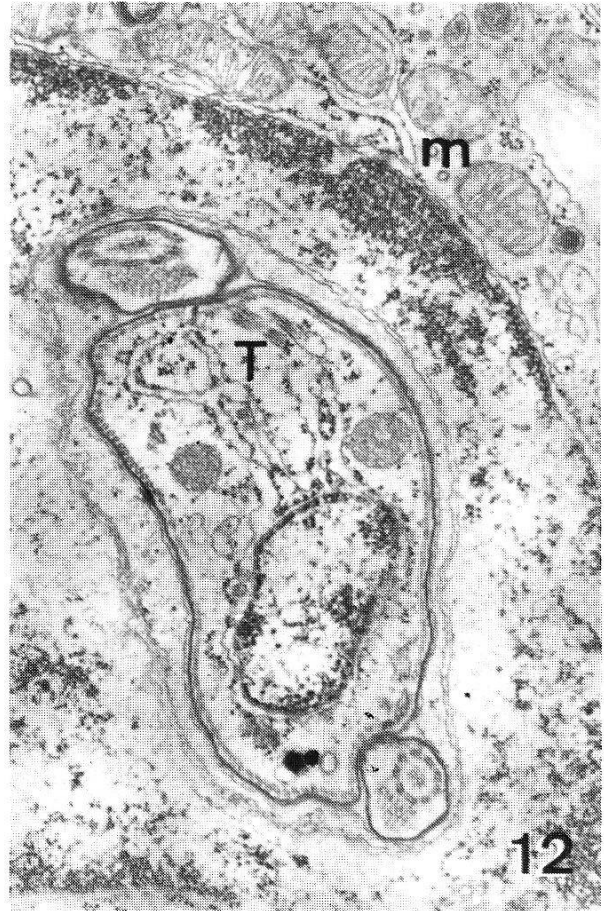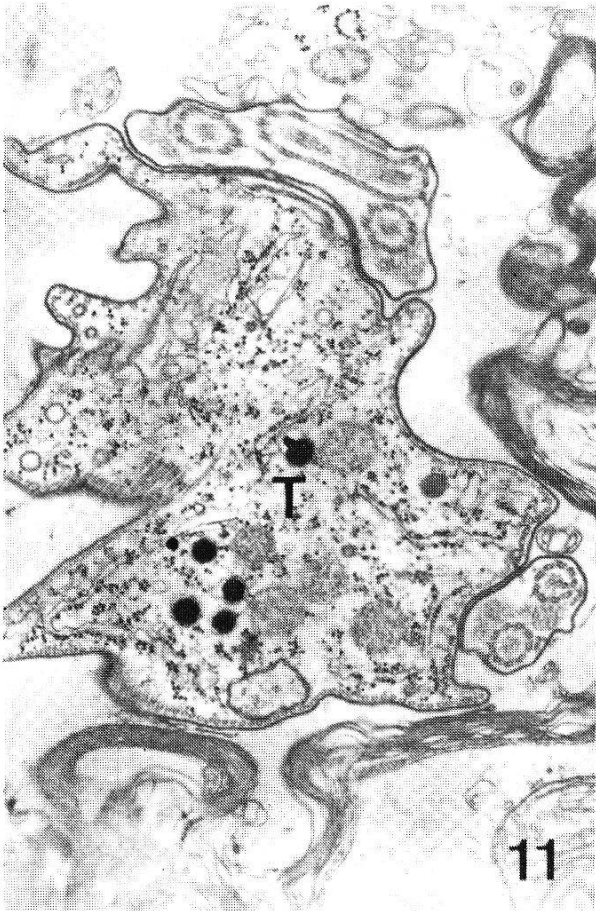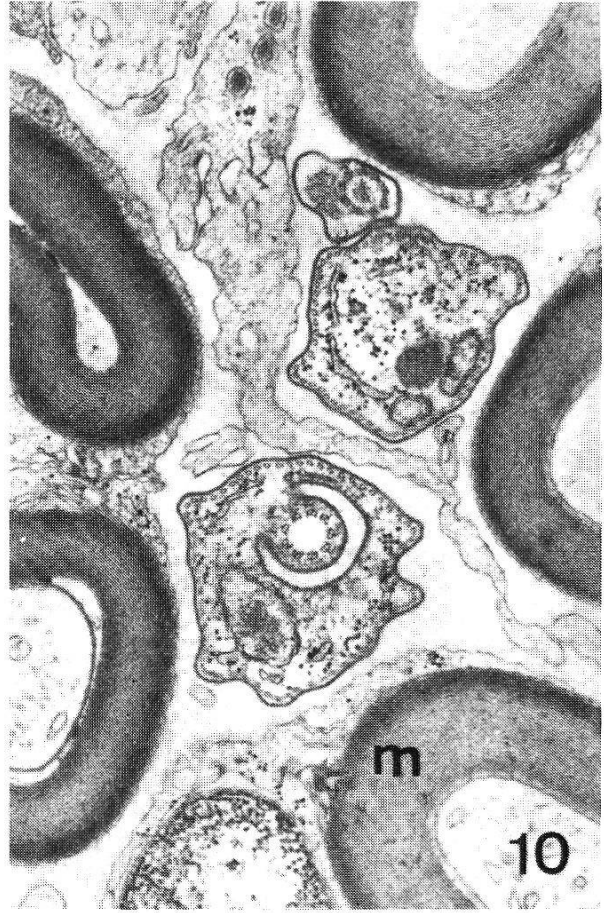
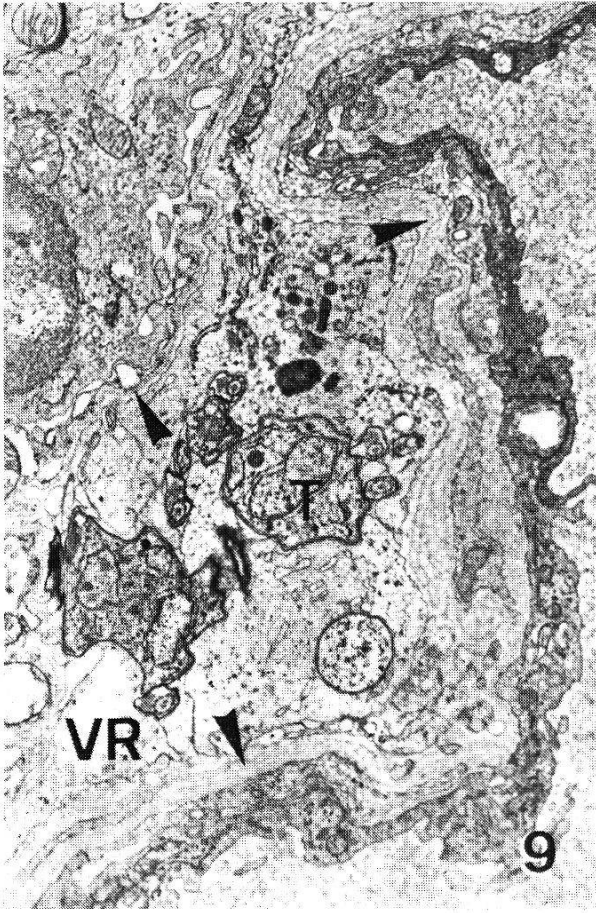
In the CNS-parts and all other tissues examined, lysed as well as phagocytosed trypanosomes were found. Parasites ingested by macrophages tended to indent the nuclear envelope of the macrophages (Fig. 12). In addition, several flagellar profiles containing more than one axoneme, representing either dividing or degenerating trypanosomes, could be observed (Fig. 11).

Fig. 5. *T. b. gambiense* (T) in liver sinusoid phagocytosed by a Kupffer cell (K). $\times 14000$.

Fig. 6. Trypanosomal profile (T) in a hepatocyte (h) surrounded by a host cell membrane (►). $\times 22000$.

Fig. 7. Trypanosomes (T) in the interstitial space of the choroid plexus (e = ependyma). $\times 14000$.

Fig. 8. Trypanosome (T) in a capillary in the brain stem tissue (e = endothelium). $\times 20000$.



The host reaction was expressed by an increased number of detected plasma cells in all organs. In addition, in the brain and choroid plexus lymphocytes and macrophages were also present. In the lymphoid organs the frequency of granulocytes was also enhanced as compared to these organs of uninfected animals. Many areas of the tissues studied showed mild haemorrhages.

Discussion

With respect to the main question, which trypanosomes are likely to be responsible for relapses after chemotherapy, the choroid plexus and the brain tissue were of special interest. In the present investigation cell division of trypanosomes within the interstitial spaces of the choroid plexus was observed. Ultrastructurally no trypanosome profiles different from trypomastigote forms could be distinguished. This does not correspond to the assumption of Ormerod and Venkatesan (1971) that the choroid plexus is the most important organ for multiplication of amastigote forms.

In the present as well as in earlier studies (Poltera et al., 1980; Jenni et al., 1983; Rudin et al., 1983), trypanosomes were never found within the ependyma. Therefore neither the penetration of the ependyma as a possible route for passing the blood-CSF-barrier proposed by Stevens and Moulton (1977) nor the multiplication of trypanosomes in the ependymal cells as a site for cryptic stages, demonstrated by Abolarin et al. (1982), could be confirmed.

Earlier investigations by Poltera et al. (1983) and Rudin et al. (1983) showed that the choroid plexus was cleared of parasites by chemotherapy. This is in accordance with the postulate of Jennings et al. (1979) that the trypomastigote forms in the choroid plexus are susceptible to chemotherapy. All together makes the role of the choroid plexus as a possible source for relapses questionable.

Meningoencephalitis was found in *M. montanus* cyclically infected with *T. gambiense*. Similar findings were described by several authors (e.g. Peruzzi, 1927; Stevens and Moulton, 1977; Schmidt, 1983). In contrast to the experiments with *T. gambiense* TH 3/78 (031) which could not be found in the brain tissue up to 56 days after infection, trypanosomes of the stock DAL 069 were already detected in the brain parenchyma 30 days after infection. The choroid plexus, the interstitial spaces of the meninges and the Virchow-Robin

Fig. 9. *T. b. gambiense* (T) in the Virchow-Robin space (VR) around a capillary in the brain stem (▶ = basal laminae). ×7200.

Fig. 10. Trypanosomes between cells of the brain stem tissue (m = myelin sheet). ×21000.

Fig. 11. Dividing or degenerating trypanosome (T) in the brain stem tissue. ×19000.

Fig. 12. Phagocytosed trypanosome (T) in a macrophage (m) enclosed by the host cell nucleus (nu). ×20000.

spaces were parasitized. While trypanosomes were also found in small brain capillaries, penetration of the endothelium by a parasite was not observed.

In the present investigation, most of the trypanosomes were located near brain capillaries as reported by Fink and Schmidt (1979) and Schmidt (1983). The parasitization of the brain parenchyma was demonstrated in different animal models for sleeping sickness (Poltera et al., 1981, 1982; Wéry and Kayembe, 1971; van Marck et al., 1981a, b; Schmidt, 1983; Rudin et al., 1983). These authors demonstrated that the time of penetration of the blood-brain-barrier after infection seems to depend on the stock and subspecies of the parasite. For penetration of trypanosomes into the brain parenchyma there are several possible routes. The findings of the present work support the hypothesis that brain invasion occurs via the Virchow-Robin spaces after penetration of the capillaries. Stevens and Moulton (1977) and Poltera et al. (1980) proposed that trypanosomes may enter from the choroid plexus via the CSF passing across the ependyma. Schmidt (1983) suggested that invasion occurs from capillaries into the CSF of the subarachnoidal space and from there via the Virchow-Robin space into the brain tissue. From a histological point of view, the easiest way of passing the blood-brain-barrier by the trypanosomes would be the penetration of the leaky blood vessels near the subarachnoidal space and to follow then the route proposed by Schmidt (1983). However, the passage of the densely fitted endothelium of the non-fenestrated brain capillaries or the penetration of the ependyma may still not be excluded as a possible way from the circulatory system into the brain parenchyma.

Distribution and location of trypanosomes in the other organs examined: after a phase of establishment in the skin at the site of infection, the lymph nodes are parasitized via the draining lymph vessels (Barry and Emery, 1984). They remain infected throughout the infection (Jenni et al., 1983). The stage investigated showed slightly increased, focally haemorrhagic lymph nodes containing trypanosomes mainly outside the sinusoids between lymphocytes, monocytes, macrophages, a few granulocytes, plasma cells, and red blood cells. Similar findings were described for *T. brucei* in dogs (Morrison et al., 1981). By means of qualitative electron microscopy it was not possible to decide whether the trypanosomes were mainly slender forms as was described by Tanner et al. (1980) using stereological methods, for *T. brucei* in rats, or if there was a pleomorphic population. Forms obviously different from those of a normal blood population were not detected.

The markedly enlarged spleen, engorged with red blood cells, was, as in earlier investigations (Jenni et al., 1983), the only organ showing many lysed parasites in extravascular spaces. On the other hand structurally intact trypanosomes were also present. A remarkably high density of parasites was found within and outside the liver sinusoids. Extravascularly, many red blood cells, residual bodies, Kupffer cells (frequently containing remains of trypanosomes), and plasma cells were present. These observations corresponded to those of van

Marck et al. (1981) for rats and mice and also to those of Lumsden et al. (1972) who also found parasites in Kupffer cells. Pathologic alterations of the hepatocytes could not be distinguished by Beckers et al. (1981) and van Marck et al. (1981). Lumsden et al. (1972), however, described cytopathological effects in hepatocytes of *T. gambiense* infected guinea pigs. In the present investigation, similar structural changes such as vacuolisation, swelling of the mitochondria, vesiculation of the rough endoplasmic reticulum were observed but not to the same extent as in Lumsden's (1972) study. In addition, hepatocytes contained trypanosome profiles, as already described by Jenni et al. (1983). Some of them were surrounded by a host cell membrane which was lacking in others. This membrane probably becomes invaginated when the parasite penetrates into the cell and disintegrates later.

Trypanosomes were localized in the connective tissue of epicardium, myocardium, and endocardium of the heart. This confirmed the electron microscopic findings of several authors (van Marck et al., 1981; Jenni et al., 1983). Despite the presence of lysed and proliferating trypanosomes in the heart as well as in all other organs examined, the inflammatory reaction was not pronounced.

Acknowledgments

We would like to thank Mrs. M. Kaufmann and E. Fluri for skilful technical assistance and Dr. K.-F. Schell for breeding of *M. montanus*. We are indebted to Drs. D. Mehlitz and S. K. Moloo for providing us with the stock of *T. b. gambiense* and pupae of *G. m. centralis*, respectively. Prof. H. Hecker and Dr. D. Jefferies we thank for critical discussion of the manuscript. This work was partially supported by the Swiss National Science Foundation Grant no. 3.376-0.82.

- Abolarin M. O., Evans D. A., Tovey D. G., Ormerod W. E.: Cryptic stage of sleeping-sickness trypanosome developing in choroid plexus epithelial cells. *Brit. med. J.* 285, 1380-1382 (1982).
- Barry J. D., Emery D. L.: Parasite development and host responses during the establishment of *Trypanosoma brucei* infection transmitted by tsetse fly. *Parasitology* 88, 67-84 (1984).
- Beckers A., Wéry M., van Marck E., Gigase P.: Experimental infections of laboratory rodents with recently isolated stocks of *Trypanosoma brucei gambiense*. 1. Parasitological investigations. *Z. Parasitenk.* 64, 285-296 (1981).
- Fink E., Schmidt H.: Meningoencephalitis in chronic *Trypanosoma brucei rhodesiense* infection of the white mouse. *Tropenmed. Parasit.* 30, 206-211 (1979).
- Jenni L., Rudin W., Schell K. F.: Extravascular and vascular distribution of *Trypanosoma b. gambiense* in *Microtus montanus* after cyclical transmission. *Contr. Microbiol. Immunol.* 7, 95-102 (1983).
- Jennings F. W., Whitelaw D. D., Holmes P. H., Chizyuka H. G. B., Urquhart G. M.: The brain as a source of relapsing *Trypanosoma brucei* infection in mice after chemotherapy. *Int. J. Parasit.* 9, 381-384 (1979).
- Lumsden R. D., Marciacq Y., Seed J. R.: *Trypanosoma gambiense*: cytopathologic changes in Guinea pig hepatocytes. *Exp. Parasit.* 32, 369-389 (1972).
- Morrison W. I., Murray Max, Sayer P. D., Preston J. M.: The pathogenesis of experimentally induced *Trypanosoma brucei* infection in the dog. II. Changes in the lymphoid organs. *Amer. J. Parasit.* 102, 182-194 (1981).

- Ormerod W. E., Venkatesan S.: An amastigote phase of the sleeping sickness trypanosome. *Trans. roy. Soc. trop. Med. Hyg.* 65, 736–741 (1971).
- Peruzzi M.: Pathological-anatomical and serological observations on the trypanosomiasis. Final Report of the League of Nations Int. Commission on Human Trypanosomiasis, p. 245–336. League of Nations, Genève 1927.
- Poltera A. A.: Chemotherapy, relapses and CNS in experimental African trypanosomiasis. *Contr. Microbiol. Immunol.* 7, 155–164 (1983).
- Poltera A. A., Hochmann A., Rudin W., Lambert P. H.: *Trypanosoma brucei brucei*: a model for cerebral trypanosomiasis in mice – an immunological, histological and electronmicroscopic study. *Clin. exp. Immunol.* 40, 496–507 (1980).
- Poltera A. A., Hochmann A., Lambert P. H.: *Trypanosoma brucei brucei*: the response to Melarso-*prol* in mice with cerebral trypanosomiasis. An immunopathological study. *Clin. exp. Immunol.* 46, 363–374 (1981).
- Poltera A. A., Hochmann A., Lambert P. H.: *Trypanosoma brucei gambiense*: cerebral immunopathology in mice. *Acta trop. (Basel)* 39, 205–218 (1982).
- Rudin W., Poltera A. A., Jenni L.: An EM study on cerebral trypanosomiasis in rodents and primates. *Contr. Microbiol. Immunol.* 7, 165–172 (1983).
- Schmidt H.: The pathogenesis of trypanosomiasis of the CNS. Studies on parasitological and neurohistological findings in *Trypanosoma rhodesiense* infected vervet monkeys. *Virchows Arch. (Path. Anat.)* 399, 333–343 (1983).
- Stevens D. R., Moulton J. E.: Experimental meningoencephalitis in *Trypanosoma brucei* infection of deer mice (*Peromyscus maniculatus*). A light, immunofluorescent, and electron microscopic study. *Acta neuropath. (Berl.)* 38, 173–180 (1977).
- Tanner M., Jenni L., Hecker H., Brun R.: Characterization of *Trypanosoma brucei* isolated from lymph nodes of rats. *Parasitology* 80, 383–391 (1980).
- Van Marck E. A. E., Gigase P. L. J., Beckers A., Wéry M.: Experimental infections of laboratory rodents with recently isolated stocks of *Trypanosoma brucei gambiense*. 2. Histopathological investigations. *Z. Parasitenk.* 64, 187–193 (1981a).
- Van Marck E. A. E., Le Ray D., Beckers A., Jakob W., Wéry M., Gigase P. L. J.: Light and electron microscope studies on extravascular *Trypanosoma brucei gambiense* in the brain of chronically infected rodents. *Ann. Soc. belge Méd. trop.* 61, 57–78 (1981b).
- Wéry M., Kayembe D.: Morphology of the parasites and pathological changes in the brain of albino rats infected with *Trypanosoma gambiense*. *Trans. roy. Soc. trop. Med. Hyg.* 65, 409–411 (1971).