

The lumbar disc-degeneration and sciatica

Autor(en): **Friberg, Sten**

Objektyp: **Article**

Zeitschrift: **Bulletin der Schweizerischen Akademie der Medizinischen Wissenschaften = Bulletin de l'Académie suisse des sciences médicales = Bollettino dell' Accademia svizzera delle scienze mediche**

Band (Jahr): **3 (1947-1948)**

Heft 4-5

PDF erstellt am: **26.09.2024**

Persistenter Link: <https://doi.org/10.5169/seals-306898>

Nutzungsbedingungen

Die ETH-Bibliothek ist Anbieterin der digitalisierten Zeitschriften. Sie besitzt keine Urheberrechte an den Inhalten der Zeitschriften. Die Rechte liegen in der Regel bei den Herausgebern.

Die auf der Plattform e-periodica veröffentlichten Dokumente stehen für nicht-kommerzielle Zwecke in Lehre und Forschung sowie für die private Nutzung frei zur Verfügung. Einzelne Dateien oder Ausdrucke aus diesem Angebot können zusammen mit diesen Nutzungsbedingungen und den korrekten Herkunftsbezeichnungen weitergegeben werden.

Das Veröffentlichen von Bildern in Print- und Online-Publikationen ist nur mit vorheriger Genehmigung der Rechteinhaber erlaubt. Die systematische Speicherung von Teilen des elektronischen Angebots auf anderen Servern bedarf ebenfalls des schriftlichen Einverständnisses der Rechteinhaber.

Haftungsausschluss

Alle Angaben erfolgen ohne Gewähr für Vollständigkeit oder Richtigkeit. Es wird keine Haftung übernommen für Schäden durch die Verwendung von Informationen aus diesem Online-Angebot oder durch das Fehlen von Informationen. Dies gilt auch für Inhalte Dritter, die über dieses Angebot zugänglich sind.

From the orthopædic clinic of "Karolinska Institutet" Stockholm

The lumbar disc-degeneration and sciatica

By Sten Friberg

It is only a little more than 10 years since a prominent colleague of ours stated, that sciatic pain is by a good half a disease of the mind (Ischias ist zu 50% eine Geisteskrankheit). He did not mention the nature of the other half. As late as 1935 in a textbook of neurology the statement was made, that the commonest causes of sciatica are: polyarthritis, tonsillitis, sepsis, syphilis, typhoid fever, the puerperium, influenza, gonorrhœa, pneumonia, scarlatina, alcoholism, carbonmonoxide-, lead-, arsenic- and bismuth poisoning, uratic arthritis and obesity. However, this long list must be considered to be a collection of suppositions in the absence of positive observations. One is bound to ask oneself, why all these complaints should create a selective irritation in the sciatic nerve, why the disease should occur to about 80% in men? It is not surprising, therefore, that the findings of *Mixter* and *Barr*, published in 1934, stating that in 30 cases operated upon the cause of the pain had been pressure on the nerve root due to prolapse of a disc, aroused great enthusiasm. One might almost say, too great an enthusiasm, because ever since, sciatic pains and disc prolapses have been regarded as the same thing by far too many surgeons.

At the Orthopædic University Clinic in Stockholm we began to use surgical treatment in intervertebral disc prolapses in the lumbar region in 1939. At that time, many believed that disc prolapses were to great extent due to turgescence and elasticity of the nucleus pulposus, that a part of the nucleus bulged out and in some cases was sucked in through the crack in the annulus fibrosus. I could not accept this explanation because in all operations up to that time I had found the prolapse to be quite loose and only very slightly elastic. In addition, in many cases, under the prolapse there was a cavity much bigger than the prolapse itself. In 1940 I started an investigation in which, among other things, I tried to produce disc herniation in an experimental way. My first attempts were entirely unsuccessful. It was impossible to produce a prolapse through a made hole even when the spine was subjected to con-

siderable force. It was only possible to create a prolapse after the spine had first been operated in order to be laid entirely free. These researches were performed on, in all, 40 specimens of varying ages, and with the same results. I thus came to the conclusion that the prolapse is not a sign of turgescence in the nucleus but rather the result of a preexisting degenerative condition of the disc.

When making these investigations I examined the question of the spaces for the nerve roots in the lower lumbar region and I shall now show a few pictures, which may be of some guidance in the treatment of low back and sciatic pain.

Fig. 1 is a routine X-ray picture of the lumbar region. In the upper region, the intervertebral foramina are wide both in the cranio-caudal and the ventro-dorsal direction. A decrease in their cranio-caudal length even with the total height of the disc cannot reasonably lead to a pressure on the nerve-root. In the lower region the intervertebral foramina are smaller not only in the cranio-caudal but more especially in the ventro-dorsal direction. Inversely the nerve-roots are thicker and the risk of pressure arising is greater.

Fig. 2 is a lateral view of a specimen of the lumbo-sacral region. A wedge of the 5th lumbar vertebra has been removed and the narrowest part of the intervertebral foramen is well seen. The 5th lumbar vertebral body, the normal lumbo-sacral disc, the sacral bone, the nerve-root, in this case running along the disc for a distance of 3 cm. The nerve-root is running through an extremely small space and there are small changes necessary to get a pressure on it.

Fig. 3 shows a disintegration in the 4th lumbar disc. It is seen from the medial side. The vertebral body is cut in the medial line, the 4th, the 5th vertebral body, the intervertebral disc, here rough and bulky on the posterior surface, the yellow ligament, the base of the arch and here the nerve-root, in this case running over the uneven disc protrusion.

Fig. 4 is a plain view of the whole region. The spinal processes, the arches and the intervertebral joints are removed. From behind is seen the dural sac, nerve-roots, the intervertebral ganglia, the bases of the arches, the vertebral bodies and the normal discs. Note the close connection between the disc and the nerve-roots. Nerve-roots I-IV leave the dural sac just above the disc, where they leave the spine, in other words, they have an almost horizontal course. The 5th nerve-root leaves the dural sac at the level of the 4th disc but leaves the spine at the 5th. Intradurally the nerve-roots are very mobile, extradurally they are relatively fixed, i.e. by degenerative processes in or around the discs, the

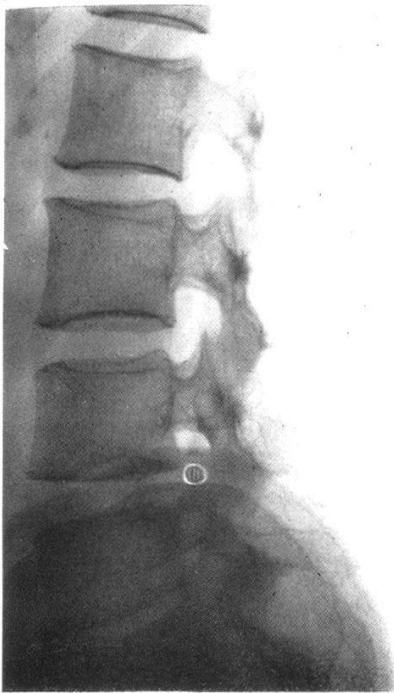


Fig. 1.

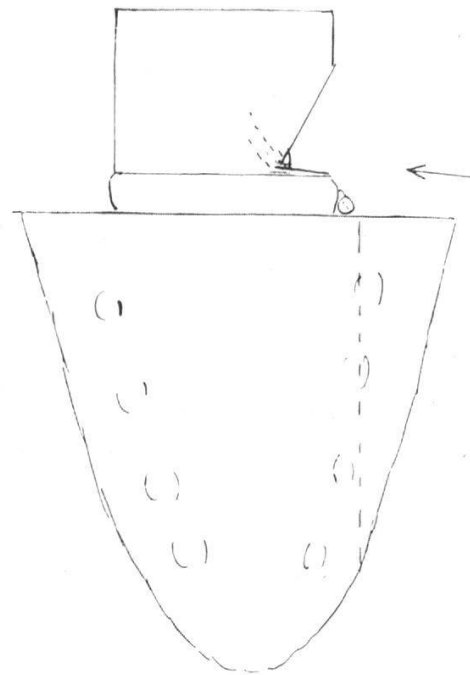


Fig. 2a.

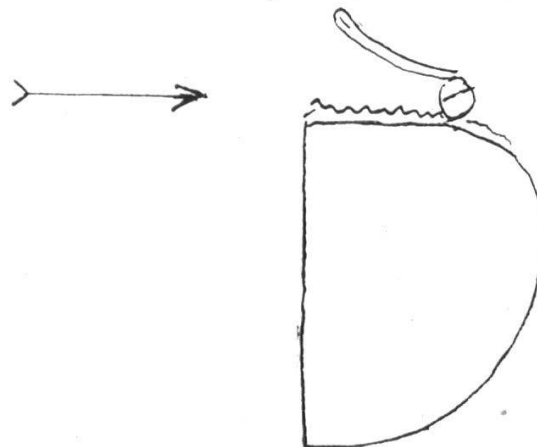


Fig. 3a.




Fig. 2b.

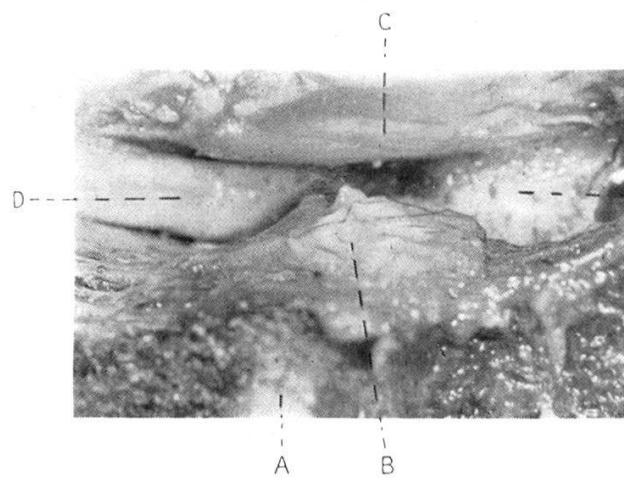


Fig. 3b.

upper 4 roots might be affected only in one interspace but the 5th one in 2, both the 4th and the 5th. This detail is of importance for the diagnosing of levels in disc surgery.

Before passing on to the clinical aspects I should like to mention some features of an investigation by my assistant, *Carl Hirsch*, and myself. All those of you who are engaged in spinal surgery know that sometimes it is possible to observe at operation an abnormal mobility in the lumbar disc. Some years ago, the radiologist of the clinic, *Folke Knutsson*, showed that with different positions of the trunk in some patients with lumbar and sciatic pain it was possible to detect an anterior or a posterior displacement of a vertebra towards the adjoining one (fig. 5, 6 and 7). When once we had had our eyes opened to this what we call instability, it could be observed in quite a number of patients without the disc showing any other radiologic symptoms of disintegration. We consider instability to be a fairly early clinical sign. In a series of 100 post mortem cases *Hirsch* and I have tried to find out the pathologic changes, causing this instability.

I shall not go into details, but only show you some pictures. This is a lumber spine from a man of 30 (fig. 8). At the post mortem examination an instability in the 4th lumbar disc was found. A cross cut through the disc: The nucleus pulposus is substituted by a fibrous scar tissue, as are also the central parts of the annulus. In the annulus there are extensive ruptures showing a special arrangement typical for disintegration in the 2 lower discs, radiating from the posterior surface. The rupture always cuts the annulus. In instability this feature is always found and there seems good reason for saying that although instability is an early clinical sign it implies advanced pathologic changes. It is due to continual interruption in the fibrous ring. Usually the rupture is in the form of a "T", with the branches going out laterally to the intervertebral foramina. This type of disintegration most often characterizes the 2 lowest discs. In the upper region it is more concentric and diffuse.

The clinical symptoms I presume to be well known. By clinical experience we know that the prolapses causing symptoms serious enough to indicate surgical intervention are situated in the 4th or 5th lumbar interspaces in about 90–95 per cent of all cases. In the past year there has been a tendency in some quarters to operate only on the strength of the clinical neurological finding. The argument is, that, according to the symptoms "this is a first sacral syndrome, this is the 5th lumbar syndrome, myelography is unnecessary, irritating and a waste of time. If on operating I do not find a prolapse in the interspace expected, most probably it is in the other of the 2 lower spaces". This line of reasoning

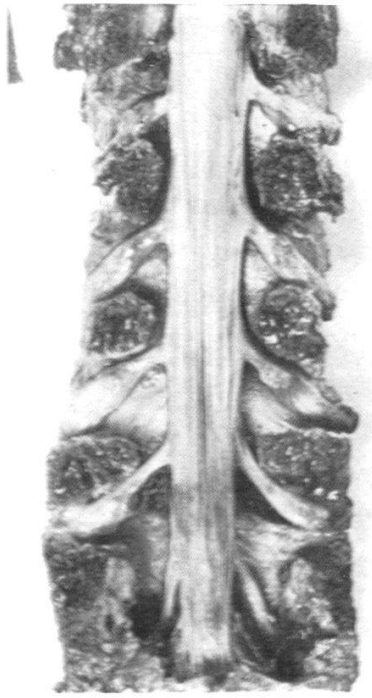


Fig. 4.

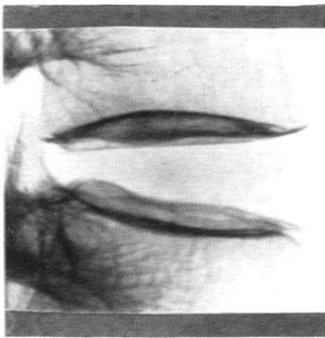


Fig. 5.

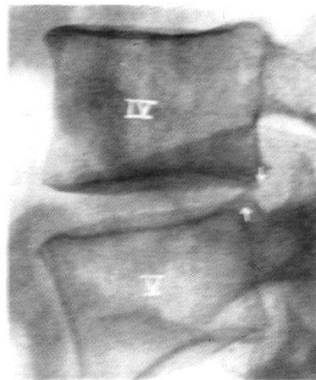


Fig. 6.

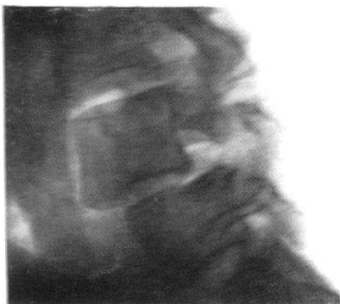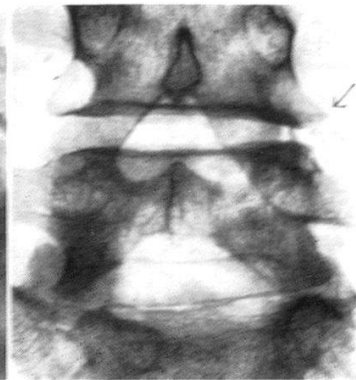


Fig. 7.

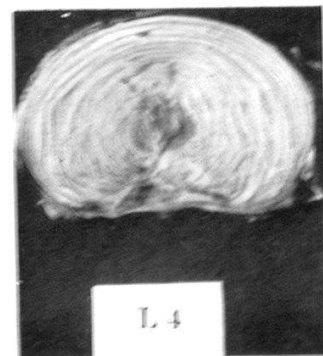


Fig. 8.

is not quite tenable. Firstly, when referring to the 5th lumbar disc the surgeon means the presacral stage. The presacral stage is not always the 5th lumbar one. In order to decide that, a thorough investigation is necessary, with an X-ray examination from the skull down. Secondly, the ankle jerk is not entirely supplied by nerve fibers from the first sacral root; the lumbo-sacral plexus is more complicated. Some years ago when there was a lack of contrast medium we operated on the indication of the clinical findings only, but we must admit that the method is not exact enough. And finally, if we remember the picture of the dural sac and the nerve roots, a pressure on the 5th nerve root might be exerted in 2 interspaces, in the 4th medially, in the 5th laterally, that is in the intervertebral foramen. Even if, by the clinical examination, we could say, this is certainly a pressure on the 5th lumbar root, we could not say whether the pressure was exerted in the 4th or the 5th interspace. It might possibly be said, that the clinical findings argue in favour of a pressure on that nerve-root, but no more, and in a good orthopædic service myelography is inevitable. One might say, when I am working without myelography, if the operative findings are negative at one level I shall find a prolapse at the other, but this is not always quite true, and too often damage is done and perhaps an extradural scar is made at 2 interspaces, sometimes, if the surgeon is too vigorous even on more.

I mentioned earlier, that too many surgeons have considered sciatic pains and disc prolapses to be the same, and I remember that some years ago one observer stated, that sciatica is disc prolapse. Our clinical experience and the researches mentioned have given us the opinion that disintegration without prolapse is much more common, that the disintegration is the fundamental process, which sometimes can lead to a prolapse, but more often not. Starting from the investigations I have described, we have begun a more comprehensive clinical investigation on our entire spine material, which comprises 15.000 patients and applies to the years 1936–1946. In the past few years when it has been possible to detect a disc disintegration at an earlier stage by the instability test, we have found disc integration in up to 50 per cent of all cases of low back pains. In many cases, the X-ray examination had been negative at the first visit to the clinic, but at later controls we were able to diagnose disintegration. This later part of the material is limited, but the average length of time from the first subjective symptoms until the disc disintegration was verified is 8 years. The figures are of course very approximative, but they nevertheless point to the fact that a negative radiogramme says very little about early and even rather advanced pathologic changes of the disc, and taken together with the great

frequency in our clinical material they show that disc disintegration is to be considered as the main cause of what is generally called low back pain, *insufficiencia dorsi*.

A disc disintegration without prolapse very often gives exactly the same symptoms as a prolapse. On the other hand a prolapse can be the root of simple lumbago troubles. In the light of the findings from the anatomical investigation it is evident that pressure on a nerve-root in the intervertebral foramen often occurs without prolapse, and that in a case such as the one I have shown a laminectomy is contraindicated. Nowadays, when we have a resorbable contrast medium causing very little irritation, we consider myelography necessary and use it as a rule, not only in sciatic pains but also in long-standing cases of lumbago. After a myelographic examination the surgeon works with greater precision and the operative trauma can be reduced to a minimum. Up to the present we have myelographic experience from more than 500 cases and are very satisfied with the method. We use abrodil in a 20 per cent solution, injected after spinal anæsthesia.

For 6 years the operations have been performed under local anæsthesia, supplemented by spinal anæsthesia during the work with the dural sack and the root. If there is a positive myelogram in accordance with the clinical findings, only one interspace is opened. The spinal processes are never removed, the musculature on the other side of the middle line not touched. As little of the arches as possible, at best nothing, is removed. This is done firstly, in order to lessen the damage to the epidural spaces, secondly, to decrease the postconvalescent time and finally, as an insurance for the future, in case a fusion, an osteosynthesis, should be necessary.

When the bulging part of the disc pressing on the nerve-root is removed by conchotome we try to lift out loose parts from the disc cavity. Scratching or thermocauterization is never done; we consider these methods to be injurious and risky; I have even heard about aorta lesions through too vigorous manipulation. And I find it extremely difficult to understand what some authors are driving at when they say they perform "removal of the entire disc". This is unnecessary; the weight-bearing structure is the fibrous ring not the nucleus.

We do not do a fusion at the same time. American surgeons are performing these combined operations to an ever-increasing extent and there are theoretical reasons for this, considering that the prolapse is the result of a preexisting disintegration of the disc. It is still generally believed, that the nucleus is the supporting structure and that the disc, after its removal, will rapidly collapse.

However, this is not quite right. The strong supporting structure is the fibrous ring, and even if this to some degree is disintegrated before the operation and the disintegration continues afterwards, this process is extremely slow. Added to that, the disc is not entirely without healing tendency. In 1941 we made a follow-up examination of our first 60 cases. At the time of operation the disc had been normal at the X-ray examination in 30 per cent, but microscopically it was disintegrated. At the follow-up examination up to 2 years after operation the disc was still normal at the X-ray examination. – It had kept its height.

In 1945 we started a new follow-up examination, in which the post-operative time of observation was set at a minimum of 5 years. Even after this long time, it was possible in many cases to observe a normal disc in the X-ray picture.

The functional result, in 800 cases operated upon, has been excellent in 60 per cent, good in 24 per cent, in other words entirely satisfactory in 84 per cent. Considering these two observations we do not usually perform a combined operation in spite of the fact that there are certain theoretical indications. We spare the fusion, the lumbo-sacral osteosynthesis, for the relatively few cases in which the low back pains persist. After the information, obtained at our last follow-up examination, the one still going on, we wait a fair while before doing a fusion. Many patients have told us they have still had low back pains up to one, or even 2 years postoperatively, but then the pain gradually abated. One reason why we have not done so many fusions is the magnitude of the operation. It takes a long time to perform, and is a rather serious intervention not only from a medical point of view but also from the social and financial aspects. It is possible that the indications might in the future be changed by the new method of locking graft, the interspinal graft, by which the convalescent time is reduced. The locking graft is an elegant method of which we have less than 2 years' experience. Up to now, the results are promising, but the contact surfaces, with this method, are sometimes rather small and there is a risk that bony ankylosis will not occur.

There is one distinct indication for immediate fusion, the lateral prolapses, where a resection of the intervertebral joint, a facetectomy, has been necessary. The lateral prolapses present a difficult problem. Usually they cannot be detected by myelography, and when exploration of the medial, the epidural part of the interspace is negative the decision as to whether one should explore the intervertebral foramen by a joint resection or not may be rather difficult. On the whole I must warn against

too extensive joint resections if the surgeon is not very experienced in spinal surgery.

At the clinic just now, we are making a follow-up examination of our lumbo-sacral osteosyntheses, performed for intervertebral disc disintegration, of which we have 13 years' experience. Considering the material the results on the whole are good. The bad results are mainly to be found among the patients, on whom earlier, very extensive explorations have been performed.

Summing up the informations from the anatomical investigations and clinical experience I should like to express them as follows: Disc disintegration is the fundamental process, from which sometimes a prolapse might—but most often does not—develop. Do not be too quick with surgical intervention, there is a wide field for conservative therapy. The operation, when necessary, must be based on a diagnose, as accurate as possible. In this way the operative lesions will be minimized. Wide explorations give no good results even after reconstructive surgery.

When beginning this lecture I spoke about the many previous attempts to explain the sciatic pain. Nowadays it is possible to refer this pain to pathological changes in or around the intervertebral lumbar disc. When these pathologic alterations are more pronounced in the lower lumbar region this might be explained by the great mechanical strain upon the region. However, this is an external factor; everybody walks on two legs stretching the lumbar spine more or less, but not all have clinical signs of disc disintegration. We must ask what is the cause of the advanced disc disintegration, what is the cause of the decrease of the turgor, in the content of water, chondroitin-sulphuric acid a.s.o. Certainly some constitutional factors are of importance, but we still do not know which.

Zusammenfassung

Der Verfasser hat pathologisch-anatomische Untersuchungen von 100 Lendenwirbelsäulen und 500 Intervertebralscheiben vorgenommen. Auf der Basis dieser Untersuchungen und der klinischen Erfahrung an 800 operierten Intervertebralscheibenprolapsen werden die Diagnostik des Diskusprolapses, die operative Behandlung, deren Möglichkeiten und Begrenzungen sowie deren Resultate diskutiert.

Résumé

L'auteur a fait des recherches anatomo-pathologiques sur 100 colonnes vertébrales (région lombaire) et 500 disques intervertébraux. En se basant sur ces recherches et sur des expériences cliniques portant sur 800 cas d'opérations de prolapsus de disques intervertébraux, il discute

le diagnostic du prolapsus discal, les indications, les limites et les résultats du traitement opératoire.

Riassunto

Il relatore ha intrapreso ricerche anatomico-patologiche su 100 segmenti lombari della colonna vertebrale e su 500 dischi intervertebrali. Basandosi su queste ricerche e sulla esperienza clinica di 800 interventi chirurgici per prolapsus dei dischi intervertebrali, si discutono la diagnosi del prolapsus dei dischi, la terapia chirurgica e le loro possibilità, limiti, risultati.

Summary

The author has carried out pathological and anatomical investigations on the lumbar portions of the spine in 100 cases and on the intervertebral discs in 500 cases. On the basis of these investigations and clinical experience on 800 operated cases of intervertebral disc prolapse, he discusses the diagnosis of disc prolapse, the operative treatment and its possibilities and limitations, as well as the results obtained.