

The influence of the adrenal cortex on tissue reactions to simple injuries

Autor(en): **Baker, B.L.**

Objektyp: **Article**

Zeitschrift: **Bulletin der Schweizerischen Akademie der Medizinischen Wissenschaften = Bulletin de l'Académie suisse des sciences médicales = Bollettino dell' Accademia svizzera delle scienze mediche**

Band (Jahr): **8 (1952)**

Heft 1-2: **Symposium über die Beeinflussung des reaktiven Geschehens durch Hypophyse und Nebennierenrinde = Symposium on the influence of the hypophysis and the adrenal cortex on biological reactions = Symposium sur l'influence de l'hypophyse et de la corticossurrénale dans les réactions biologiques**

PDF erstellt am: **15.09.2024**

Persistenter Link: <https://doi.org/10.5169/seals-307052>

Nutzungsbedingungen

Die ETH-Bibliothek ist Anbieterin der digitalisierten Zeitschriften. Sie besitzt keine Urheberrechte an den Inhalten der Zeitschriften. Die Rechte liegen in der Regel bei den Herausgebern. Die auf der Plattform e-periodica veröffentlichten Dokumente stehen für nicht-kommerzielle Zwecke in Lehre und Forschung sowie für die private Nutzung frei zur Verfügung. Einzelne Dateien oder Ausdrucke aus diesem Angebot können zusammen mit diesen Nutzungsbedingungen und den korrekten Herkunftsbezeichnungen weitergegeben werden. Das Veröffentlichen von Bildern in Print- und Online-Publikationen ist nur mit vorheriger Genehmigung der Rechteinhaber erlaubt. Die systematische Speicherung von Teilen des elektronischen Angebots auf anderen Servern bedarf ebenfalls des schriftlichen Einverständnisses der Rechteinhaber.

Haftungsausschluss

Alle Angaben erfolgen ohne Gewähr für Vollständigkeit oder Richtigkeit. Es wird keine Haftung übernommen für Schäden durch die Verwendung von Informationen aus diesem Online-Angebot oder durch das Fehlen von Informationen. Dies gilt auch für Inhalte Dritter, die über dieses Angebot zugänglich sind.

Einfache Gewebeschädigungen
Simple injuries - Lésions banales

D. C. 615.361.45:611.018.2:616.001.091

Department of Anatomy
University of Michigan Medical School Ann Arbor (Michigan)

**The Influence of the Adrenal Cortex on Tissue Reactions
to Simple Injuries¹**

By **B. L. Baker**

Current research on the relationship of the adrenal cortex to connective tissue encompasses at least three phases, namely, an elucidation of the action of adrenocortical steroids on connective tissue which is (a) normal, (b) subjected to mechanical or chemical trauma or (c) is a participant in various reactions involving a state of hypersensitivity. This presentation is concerned with the first two of these aspects. One desirable objective of our discussion might well be to discover why excessive amounts of adrenal hormones are damaging to normal or mechanically traumatized connective tissue while, on the other hand, ACTH and cortisone protect against allergic phenomena and cardiovascular lesions produced by anaphylactic hypersensitivity. This latter property of the adrenal secretions has been demonstrated convincingly by *Rich* (6, 21), *Soffer* (24) and *Germuth* (12) and their colleagues.

The original observations to be presented will deal almost entirely with the local action of adrenocortical hormones on connective tissue. It has been known for some time that certain steroid hormones, when applied to the skin in an appropriate vehicle, are absorbed readily into the circulation. Thus, *Calvery*, *Draize* and *Laug* (7), in a review of the literature published prior to 1946, concluded that when estrogens and androgens are dissolved in volatile organic solvents and placed on the skin, they are systemically as effective as when injected subcutaneously. In contrast, with adrenocortical hormones one can induce *histological effects at the site of percutaneous application without modifying the microscopic structure of other parts of the body* (3). This type of effect is illustrat-

¹ These investigations were supported by research grants from the National Cancer Institute, of the National Institutes of Health, United States Public Health Service, from the Upjohn Company and Merck & Company.

ed by cessation in growth of hair in the area of skin to which adrenocortical extract is applied. In these studies, hair is clipped weekly from the dorsum of the neck. Normally hair grows back in a symmetrical pattern. When the solvent for the hormone, 25% alcohol, is applied daily behind the right ear, the symmetrical pattern of hair growth is not disturbed. This growth inhibition is illustrated by rats which have received hog adrenocortical extract² behind the right ear in a dosage equivalent to 100 μ g of cortisone (as determined by the liver glycogen test) per day for approximately 21 days. No hair grows in the area of treatment while growth of hair on the opposite side of the neck continues undisturbed.

It seems that the localization of the action of the adrenal steroids may be due to a rapid utilization or inactivation of the hormones in the region of application. Thus, a rather large quantity of the hormone may be required to induce generalized structural effects in the body while with low doses, a sufficient concentration can be built up locally to modify microscopic structure. This concept does not exclude the possible absorption of the hormone into the blood stream. Reduction in weight of the thymus has never occurred in our rats which were treated percutaneously with adrenocortical hormones. However, 100 μ g of cortisone is probably too low a daily dose to have this effect even if injected. Recently, Speirs (26) using a more sensitive indicator of adrenal hormone concentration, i.e., the number of blood eosinophiles, reported a fall in their number when cortisone in ointment is applied to the skin of the mouse in very low doses.

The local action of adrenocortical steroids on dermal connective tissue

Although local effects of adrenocortical hormones are evident in other tissues, the primary concern of this discussion is with connective tissue. Each type of connective tissue is composed of 3 essential components, namely, cells, fibers, and ground substance. Attention will be focused on the effects of adrenocortical hormones on each of these elements in fibro-elastic connective tissue, particularly of the skin. Since the modification of tissue response to injury by adrenocortical hormones is, in part, an amplification of the actions of these hormones on normal connective tissue, the latter effects will be summarized first. The significance of these observations may be summarized in the following statement: *When a state of local hyperadrenocorticalism is created by*

² We wish to express our appreciation to the following firms for supplying us with the hormones indicated: cortisone, Merck & Company and adrenal extracts, The Upjohn Company.

direct application of adrenocortical hormones, effects are elicited on the various components of fibro-elastic connective tissue which may be detrimental to the individual.

Structural modification of dermal collagenous fibers can be induced locally by daily application of adrenocortical extract to the skin according to the plan outlined previously in the study of hair growth. However, prolonged periods of treatment are required. Sections of skin from opposite sides of the neck of a rat which had been treated on the right side for 112 days illustrates the character of the change induced. In the treated area, the dermis is thinned and the collagenous fibers appear to be melted down into a more homogeneous mass, although in most specimens the intrinsic fibrous structure of the dermis is discernible readily (8). The extent of the reduction in thickness of the dermis indicates that there is a loss of substance from the fibers themselves. Elastic fibers are not affected by the extract. They are more compactly arranged on the treated side but this may have resulted indirectly from a reduction in size of the collagenous fibers and, possibly, in the amount of ground substance. The basement membranes surrounding sebaceous glands, hair follicles, capillaries and beneath the epidermis are equally or more prominent on the treated side after staining with the Hotchkiss' periodic acid-leucofuchsin procedure.

The histologist is handicapped in the study of ground substance by the lack of staining methods adequate to reveal satisfactorily the small quantities which exist in the skin. However, one may use the indirect approach of observing the effect of adrenal hormones on the spreading action of hyaluronidase. The work of several investigators (19, 23) has shown clearly that the concurrent presence of a high concentration of C-11 oxygenated steroids in the body inhibits the spreading action of this enzyme. Another aspect of the problem is to determine what effect prior treatment of the skin with adrenal hormones has on the action of hyaluronidase. Collaborative studies carried out in this laboratory with Dr. *Mark A. Hayes*, of the University of Michigan Department of Surgery, show that prolonged local treatment of the skin with adrenal extract, cortisone or desoxycorticosterone by the procedure outlined previously, results in a significant *acceleration* in the rate and extent of spreading when hæmoglobin is used as an indicator and the enzyme solution is injected *intradermally* (13). Treatment with the alcohol solvent is without effect. These effects are illustrated for cortisone and desoxycorticosterone in fig. 1. It seems most logical to expect that the ground substance itself is modified and accelerated spreading would be expected if the production of ground substance is reduced. By the use of more

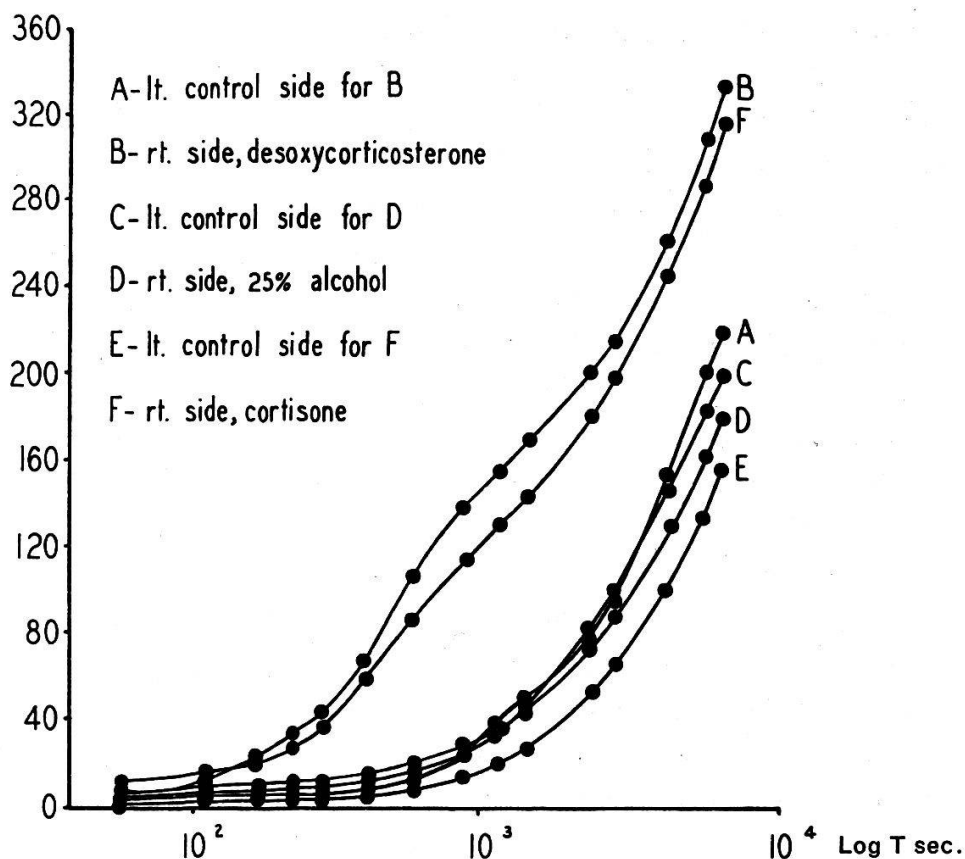


Fig. 1. Effect of cortisone and desoxycorticosterone on rate of spread with hyaluronidase.

direct methods, *Layton* (16) has shown recently that cortisone inhibits the formation of chondroitin sulfate.

Of particular importance are the modifications which occur in the fibroblast, since it plays an essential role in maintaining the normal state of the fibers and ground substance. With the local application of adrenocortical extract to the skin it is possible to demonstrate regressive changes in the fibroblast, albeit exceedingly long periods of treatment are required to do so. The cellularity of the superficial region of the dermis from the rat is reduced on the side treated with the extract as compared with a comparable area on the left non-treated side of the neck. It seems clear that fibroblasts are involved in this reduction.

Many of the structural changes in the skin which follow the local application of adrenocortical steroids are so severe that the permanency of the damage becomes a point of extreme importance. We have observed in a number of rats that local treatment of the skin with extract will maintain a cessation in growth of hair and induce the characteristic gross appearance of the skin which accompanies the dermal changes previously described, for periods of treatment as long as 160 days. However, in spite of continued treatment beyond 160 days at the same dosage,

growth of hair is resumed and the histology of the skin restored to normal. This observation is important because it demonstrates clearly an ultimate loss in the capacity of tissues to respond to the action of adrenocortical hormones. In summary, the local application of adrenal hormones to non-traumatized skin presents evidence of effects on all 3 of the essential components of fibro-elastic connective tissue.

The effect of adrenocortical steroids on wound healing

What local effects of adrenal hormones may be demonstrated in traumatized connective tissue? These will be illustrated in two ways: (a) by the action of hormones on the healing of cutaneous wounds and (b) by the foreign body reaction around implanted pellets of steroid hormones. In order to study wound repair, rats are treated locally with adrenocortical extract on one side of the dorsum of the neck, following the procedures described previously for the study of hair, until connective tissue changes are induced. Then, circular pieces of skin of equal size are excised from the right, treated side of the neck and from the left non-treated side. Treatment with the same dosage of extract is continued twice daily for 7 days. Within the first hours after making the wounds, the extent of exudate formation and contracture of the wound is far less on the treated side than on the non-treated side of the same animal or in the alcohol controls. The treated wound opens wider upon excision of the skin and lags behind in closure (fig. 2) but ultimately catches up with the non-treated wound. Microscopic preparations of

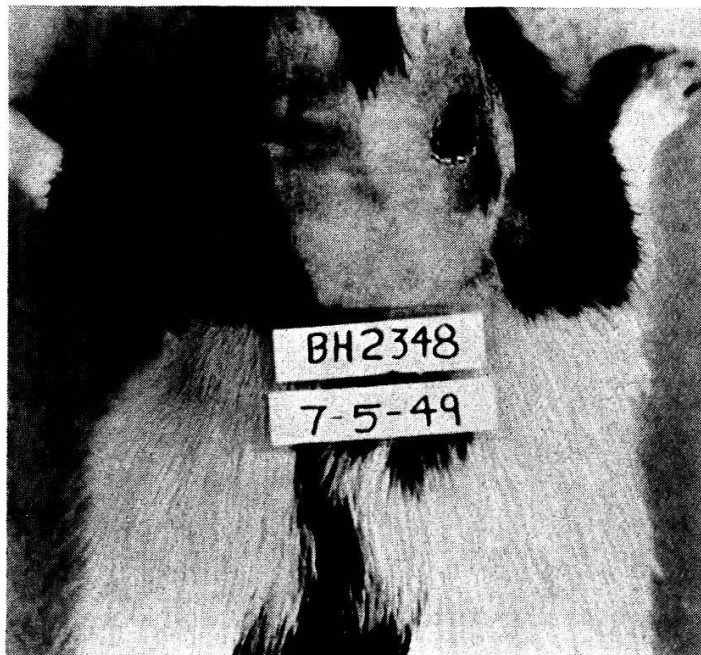

Fig. 2. Delay in closure of the right wound due to local treatment on the right side with adrenal extract.




Fig. 3.

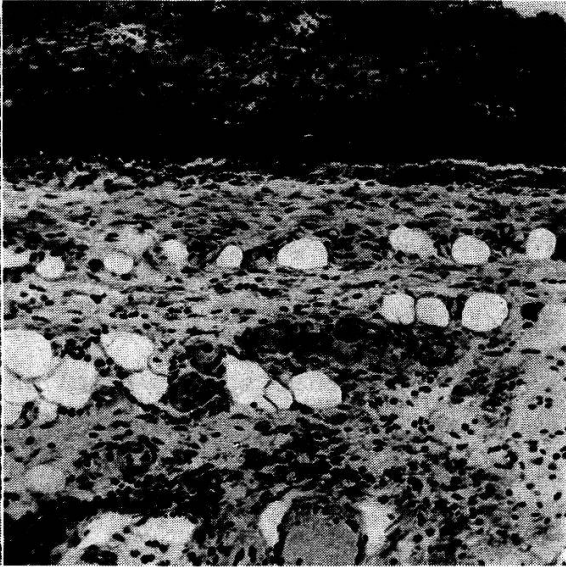


Fig. 4.

Fig. 3. Granulation tissue in left, non-treated wound after seven days.

Fig. 4. Failure of growth of granulation tissue in right wound of the rat illustrated in fig. 3 which was treated daily in this area with adrenal extract.

the wounds taken at 7 days show a retardation in formation of granulation tissue in the center of the wound treated with extract (fig. 3 and 4). Furthermore, failure in formation of new fibroblasts is revealed by microscopic sections taken at the periphery of the wound, these, also, demonstrating a reduction in alkaline phosphatase activity (Gomori method). This is particularly interesting because of the demonstration by *Fell* and *Danielli* (11) that in healing cutaneous wounds of the rat there

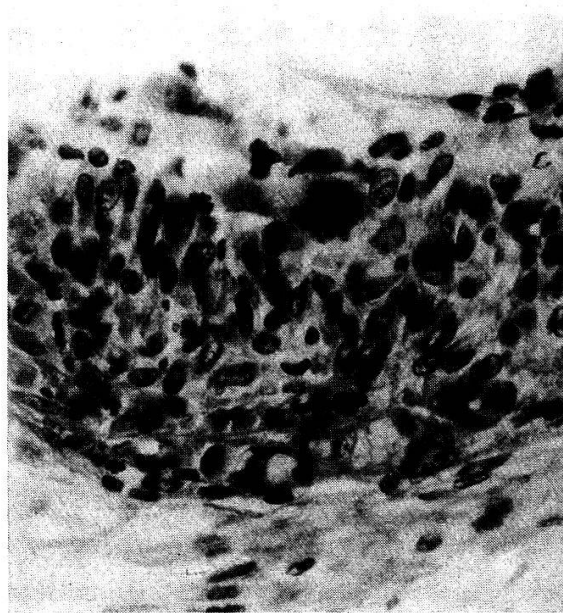


Fig. 5.

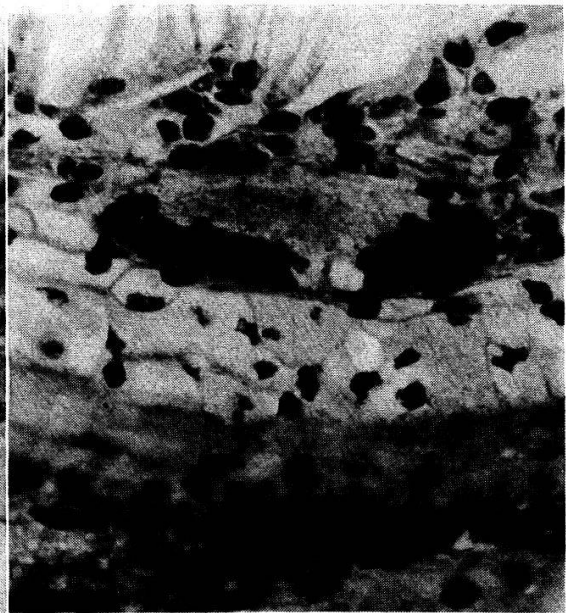


Fig. 6.

Fig. 5. Cellular capsule adjacent to a cholesterol pellet.

Fig. 6. Cellular capsule adjacent to a cortisone pellet.

are two peaks in the activity of alkaline phosphatase, the first occurring at the time of infiltration of leucocytes into the injured area and the second accompanying the formation of new connective tissue fibers. The more compact arrangement of the fibroblasts in the treated area indicates a failure to form ground substance and the absence therein of alkaline phosphatase activity suggests a failure to form fibers.

These observations appear to be impressive but their significance must be evaluated in the light of the lack of permanence of the effect. Adrenocortical extract in the dosages employed will not wholly prevent closure of a wound. In fact, the trauma induced in the skin of a treated region is a potent stimulus to growth which cannot be overcome wholly by adrenal hormones at the dosages employed by us. This fact is illustrated strikingly by the resumption in growth of hair at the border of the wound. Finally, pre-treatment of the skin is an important factor. In skin which has not been so prepared direct application of extract or cortisone to wounds brings about far less distinctive effects.

Connective tissue reactions around implanted pellets

Interference with protective processes in connective tissue by adrenocortical hormones is illustrated by comparison of the character of the foreign body reaction to pellets of cholesterol and cortisone (*Merck*) which are implanted into the retro-bulbar tissues of the orbit and left in place for 12 days. The pellets weigh 0.5 to 1.5 mg at the time of implantation.

At the end of 12 days, the pellets of cholesterol are surrounded by a thick cellular capsule composed chiefly of epithelioid mononuclear macrophages, a few lymphocytes and sparse infiltrating neutrophils (fig. 5). Some increase in the number of fibroblasts is apparent with growth of new blood vessels at the outer border. The inner border of this capsule is composed of many giant cells of variable size which possess a dense cytoplasm.

In contrast, the tissue reaction around pellets of cortisone is quite different (fig. 6). There is far less of a cellular response. The capsule of cells is thin and the vast majority of the mononuclear macrophages show evidence of degeneration, as indicated by fragmentation or pycnosis of the nucleus and extreme vacuolation of the cytoplasm, these changes being most marked in those cells farthest removed from the pellet. No polymorphonuclear neutrophils are observed in the region of the pellet. New blood vessels do not form. The giant cells are exceedingly few in number and those which do form are enlarged and their cytoplasm lightly stained and reticulated.

Discussion

In general, these observations of the local action of adrenocortical hormones on connective tissue are in good agreement with those of other workers who have studied the role of the adrenal cortex in the response of the body to injury by the systemic administration of hormones. Thus cortisone is reported to inhibit the healing of cutaneous wounds in the rabbit (20), mouse (25) and man (9) and the formation of granulation tissue around turpentine abscesses (27). Locally applied it retards vascularization of the injured cornea of the rabbit eye (15). As would be expected, *Blunt et al.*, (5) find that cortisone also impedes the healing of bone fractures in the rabbit. Administration of adrenocorticotropin inhibits the development of adhesions which arise from the intra-peritoneal injection of talcum into the rat (10).

In terms of specific tissue elements, one may summarize as follows those actions of adrenocortical steroids on fibro-elastic connective tissue which will modify its response to simple injury. (a) Proliferation of fibroblasts (1, 20) and growth of blood vessels (1, 15) are inhibited. (b) The formation of ground substance (16) and collagenous fibers (1) is retarded. (c) Exudation from open wounds is suppressed. (d) Leucocytic infiltration into an injured area is reduced (18). (e) Concurrent administration of C-11 oxygenated steroids antagonizes the spreading action of hyaluronidase (19, 23), whereas pretreatment with these hormones accelerates the action of this enzyme. (f) The resistance of capillaries to negative pressure is increased (22) and the increase in permeability induced by leukotaxine is inhibited (17).

Two points merit consideration in order to permit a satisfactory evaluation of the significance of these observations. The first pertains to a comparison of the effects elicited by the local use of the C-11 non-oxygenated (desoxycorticosterone) and C-11 oxygenated (cortisone) steroids. In several respects the responses are similar but the former compound is less potent in the induction of them. Thus, desoxycorticosterone simulates the action of cortisone in its capacity to inhibit the growth of hair and to accelerate the spreading action of hyaluronidase.

Second, one cannot stress too strongly the relationship of the connective tissue effects as described, to the concentration of adrenocortical steroids in the region under study. As has been emphasized so forcibly by *Ingle* (14), growth processes are retarded by both an insufficiency and an over-abundance of the C-11 oxygenated steroids in the body. The histological changes which we have described were obtained in the latter situation. The important field encompassing the physiological and anatomical effects of adrenal secretions on fibro-elastic connective tissue

when they are at a normal concentration in the body fluids remains, to a large extent, unexplored. Therefore, it is important to remember that in order to produce these changes we have upset homeostasis in a localized region of the body. Whatever these findings may contribute to a better understanding of clinical effects, their significance must be evaluated in the light of the abnormal manner in which they are induced.

In *conclusion*, adrenocortical steroids induce changes in fibro-elastic connective tissue by direct action which apparently are associated with a local state of hyperadrenocorticalism. For the most part, in non-traumatized tissues, these modifications are regressive in nature and in traumatized connective tissue they interfere with the development of the expected reparative processes. By way of explanation of the histological reaction revealed by the methods of study used by us, it seems that many of the changes may be caused by a suppression in the metabolism of the fibroblast. The exact nature of the effect remains unknown. Possibly it results from the catabolic action of the C-11 oxygenated steroids on protein, or from interference with certain enzyme systems. It seems clear that, in the long run, tissue modifications of the type described herein might prove detrimental to the welfare of the individual.

1. *Alrich, E. M., Carter, J. P., and Lehman, E. P.*: Ann. Surg. **133**, 783 (1951). –
2. *Baker, B. L.*: Ann. N.Y. Acad. Sci. **53**, 690 (1951). – 3. *Baker, B. L., and Whitaker, W. L.*: Anat. Rec. **102**, 333 (1948). – 4. *Baker, B. L., and Whitaker, W. L.*: Endocrinol. **46**, 544 (1950). – 5. *Blunt, J. W., Plotz, C. M., Lattes, F., Howes, E. L., Meyer, K., and Ragan, C.*: Proc. Soc. exper. Biol. a. Med. (Am.) **73**, 678 (1950). – 6. *Bennett, I. L. Jr., Berthrong, M., and Rich, A. R.*: Bull. Hopkins Hosp., Baltim. **88**, 197 (1951). –
7. *Calvery, H. O., Draize, J. H., and Laug, E. P.*: Physiol. Rev. (Am.) **26**, 495 (1946). –
8. *Castor, C. W., and Baker, B. L.*: Endocrinol. **47**, 234 (1950). – 9. *Creditor, M. C., Bevans, M., Mundy, W. L., and Ragan, C.*: Proc. Soc. exper. Biol. a. Med. (Am.) **74**, 245 (1950). – 10. *Ducommun, P., and Mach, R. S.*: Sem. Hôp. Par. **10**, 2 (1950). –
11. *Fell, H. B., and Danielli, J. F.*: Brit. J. exper. Path. **24**, 196 (1943). – 12. *Germuth, F. G. Jr., Medzel, G. A., Ottinger, B., and Oyama, J.*: Proc. Soc. exper. Biol. a. Med. (Am.) **76**, 177. – 13. *Hayes, M. A., Reed, T. G., and Baker, B. L.*: Proc. Soc. exper. Biol. a. Med. **72**, 136 (1950). – 14. *Ingle, D. J., and Prestrud, M. C.*: Endocrinol. **45**, 143 (1949). – 15. *Jones, I. S., and Meyer, K.*: Proc. Soc. exper. Biol. a. Med. (Am.) **74**, 102 (1950). – 16. *Layton, L. L.*: Proc. Soc. exper. Biol. a. Med. (Am.) **76**, 596 (1951). –
17. *Menkin, V.*: Amer. J. Physiol. **129**, 691 (1940). – 18. *Michael, M. Jr., and Wharton, M.*: Proc. Soc. exper. Biol. a. Med. (Am.) **76**, 754 (1951). – 19. *Opsahl, J. C.*: Yale J. Biol. a. Med. **21**, 487 (1949). – 20. *Ragan, C., Howes, E. L., Plotz, C. M., and Blunt, J. W.*: Proc. Soc. exper. Biol. a. Med. (Am.) **72**, 718 (1949). – 21. *Rich, A. R., Berthrong, M., and Bennett, I. L., Jr.*: Bull. Hopkins Hosp., Baltim. **87**, 549 (1951). – 22. *Robson, H. N., and Duthie, J. J. R.*: Brit. med. J. **2**, 971 (1950). – 23. *Seifter, J., Baeder, D. H., and Dervinis, A.*: Proc. Soc. exper. Biol. a. Med. (Am.) **72**, 136 (1949). – 24. *Soffer, L. J., Schwartzman, G., Schneierson, S. S., and Gabilove, J. L.*: Science **111**, 303 (1950). –
25. *Spain, D. M., Molomut, N., and Haber, A.*: Amer. J. Path.: **26**, 710 (1950). –
26. *Speirs, R. S.*: **113**, 621 (1951). Science – 27. *Taubenhaus, M., and Amromin, G. D.*: J. Labor. a. clin. Med. (Am.) **36**, 7 (1950).