

The significance of loculation of intracranial aneurysms

Autor(en): **Du Boulay, G.H.**

Objektyp: **Article**

Zeitschrift: **Bulletin der Schweizerischen Akademie der Medizinischen Wissenschaften = Bulletin de l'Académie Suisse des Sciences Medicales = Bollettino dell' Accademia Svizzera delle Scienze Mediche**

Band (Jahr): **24 (1968)**

PDF erstellt am: **15.08.2024**

Persistenter Link: <https://doi.org/10.5169/seals-307747>

Nutzungsbedingungen

Die ETH-Bibliothek ist Anbieterin der digitalisierten Zeitschriften. Sie besitzt keine Urheberrechte an den Inhalten der Zeitschriften. Die Rechte liegen in der Regel bei den Herausgebern.

Die auf der Plattform e-periodica veröffentlichten Dokumente stehen für nicht-kommerzielle Zwecke in Lehre und Forschung sowie für die private Nutzung frei zur Verfügung. Einzelne Dateien oder Ausdrucke aus diesem Angebot können zusammen mit diesen Nutzungsbedingungen und den korrekten Herkunftsbezeichnungen weitergegeben werden.

Das Veröffentlichen von Bildern in Print- und Online-Publikationen ist nur mit vorheriger Genehmigung der Rechteinhaber erlaubt. Die systematische Speicherung von Teilen des elektronischen Angebots auf anderen Servern bedarf ebenfalls des schriftlichen Einverständnisses der Rechteinhaber.

Haftungsausschluss

Alle Angaben erfolgen ohne Gewähr für Vollständigkeit oder Richtigkeit. Es wird keine Haftung übernommen für Schäden durch die Verwendung von Informationen aus diesem Online-Angebot oder durch das Fehlen von Informationen. Dies gilt auch für Inhalte Dritter, die über dieses Angebot zugänglich sind.

The National Hospital, Queen Square and St. Bartholomew's Hospital, London

The Significance of Loculation of Intracranial Aneurysms

G. H. DU BOULAY

Radiology by itself can give only limited help in elucidating the aetiology of intracranial aneurysms. Nevertheless, it may supply information about the age distribution, about the prevalence and about associated diseases which is impossible to obtain in any other way on living patients, even by inference. Whatever the antecedents of an aneurysm may be, its very earliest beginnings cannot be directly observed by any but microscopic techniques. About these, HASSLER (1965), SAHS (1966), and STEHBENS (1963) have provided histological studies. After, however, a "sub-radiological period", the length of which is a matter for conjecture, some aneurysms grow to a size where they may be seen at angiography, a process which will in this paper be called "sacculation". Careful observations of their shape, size and behaviour and correlation with clinical examination, EEG changes and appearance at operation and autopsy give indications about how the patient should be managed.

The intention here is to write briefly of the aetiology of aneurysms, but then to pass over that interesting short or long period during which the radiologist cannot see the aneurysm, and elaborate only upon the behaviour of the aneurysm of macroscopic size.

Aetiology

The radiologist may draw attention to the coincidence of atherosclerosis and aneurysm in the same patient (DU BOULAY, 1965). It is clear also that the prevalence of aneurysms in patients with severe atheroma leading to symptoms of cerebral ischaemia, is much greater than in the general population. The age distribution is also relevant to aetiology in that it indicates a disease of mid and early old age similar to the age distribution of, for instance, coronary thrombosis. Atheroma is, however, a common disease. So are aneurysms common (DU BOULAY, 1965).

The difficulty about ascribing these aneurysms in a straightforward way to atheroma is that although atheroma is invariably present somewhere in the cerebral arterial tree in aneurysm cases, it may not, in any well recog-

nised form be found in the vicinity of the aneurysm itself. The answer may turn out to be that the elastic destruction or degeneration which leads to aneurysm is a pre-atheromatous condition. Much may be revealed about athero-sclerosis by a study of aneurysm cases, and of the other diseases associated with cerebral aneurysms.

The subject of aetiology cannot be left without some mention of medial muscular defects. There can scarcely now be any doubt that these are normal structures since they may always be found in mammals including man, even in very young animals. Their function is presumably to prevent serious deformity of the origin of a branch when the parent vessel constricts (DU BOULAY, 1967).

Sacculation

It is very important to remember that sacculation, or more properly, macroscopic sacculation, is not necessarily, and probably not often, a prelude to or an accompaniment of bleeding. If it were, then there would be some correspondence between the frequency of haemorrhage cases and the prevalence of aneurysms – which there is not. One may perhaps obtain some idea of what a silent aneurysm is like when first formed from a naked eye examination of bleeding aneurysms.

Out of a series of patients at the Maida Vale Hospital, there were 83 in whom the aneurysm responsible for haemorrhage was seen and carefully examined at operation or autopsy. Detailed notes of the operative appearance were made for the most part by Professor VALENTINE LOGUE, and in 33 cases we have from the operation (or occasionally the autopsy), an exact description of the wall of the aneurysm.

In 11 of these 33 cases the whole wall of the aneurysm was tissue-paper thin. Most were unilocular. 5 of them were surrounded by granulation tissue or adhesions whose firmness and organisation seemed to be a good reflection of the interval since haemorrhage. From all of them, haemorrhage had been recent.

Since the whole wall is thin in such cases, the assumption is that the aneurysm is of very recent origin. If symptomless aneurysms are like these it must be assumed that the period during which the aneurysm wall remains so frail is limited. If thickening of the aneurysm wall did not take place quickly, haemorrhage would surely be inevitable. Much that is known about the liability to further haemorrhage supports the idea of a period of instability in aneurysms. – Radiology throws further light upon this period of instability.

Referring again to LOGUE's observations: In the other 22 of the 33 cases mentioned already, some part – usually the neck and often also a proximal loculus of the aneurysm – was thicker than the point, blister or loculus which represented the rupture. Not all of them had bled more than once. Many had bled only recently.

Thus, one is faced with a concept which may be useful – that in relation to the first sacculation of an aneurysm, haemorrhage may be *immediate*,

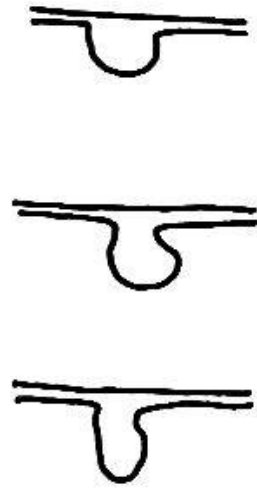

Fig. 1. Round and oval aneurysms.

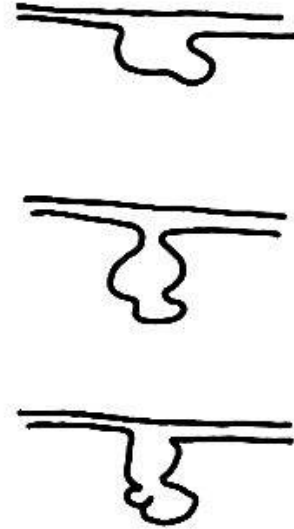


Fig. 2. Loculated aneurysms.

within at the most a few weeks, sometimes, no doubt days or hours; or it may be delayed until months or more later. The first sacculation of the aneurysm in such delayed cases may be silent, and the eventual haemorrhage when it comes may be the result of fresh weakening of some part of the now-thickened original wall of the aneurysm. The idea that loculus formation occurs during a period of instability of an aneurysm may be pressed further. In cases in which multiple aneurysms are demonstrated, if a loculated one is present, this is nearly always the aneurysm responsible for haemorrhage (DU BOULAY, 1965).

Of all recently bleeding aneurysms in the Maida Vale series, $\frac{2}{3}$ appeared loculated at angiography, after a single bleed (32/55) and after two bleeds (20/34) (Figs. 1 and 2). Aneurysms not responsible for recent haemorrhage on the other hand are hardly ever loculated in appearance. Not infrequently loculi may appear, may grow and may disappear at repeat angiography soon after haemorrhage. These changes are not necessarily always accompanied by fresh symptoms (DU BOULAY, 1965).

Can the knowledge about loculus formation be turned to useful account in the management of the patient? One of the more difficult decisions which faces the clinician is whether or not the risks of surgery are out-weighted by the dangers of a further haemorrhage. Anything which might throw light upon the probability of a further haemorrhage in particular cases would be helpful.

In the material reviewed for me by Dr. BRIAN HALE at St. Bartholomew's Hospital in 1953-1957, there is an association between loculation and *multiple* haemorrhages. There were 20 located aneurysms and 41 round or oval ones (there were also 5 irregular aneurysms). Of the 20 cases of loculated aneurysms there were 11 (55%) patients who suffered more than one haemorrhage within two months and known to be from the same aneurysm. Of the 41 cases of round or oval aneurysms there were 12 (29%) who suffered more than one haemorrhage within two months. Unfortunately, in

some cases the source of bleeding has not been established with certainty. Nevertheless, it seems from the figures so far quoted that a) loculation of aneurysms is associated with bleeding, b) loculation is probably associated with multiple bleeds.

What remains to be investigated is whether loculation is a sign suggesting the likelihood of repeated bleeding in the immediate future or whether it is merely evidence of repeated bleeding in the recent past.

Some data exist: In the Maida Vale material, of 12 aneurysms which bled again within 3 weeks after a first bleed and had an angiogram in the interval between haemorrhages, there were 5 round and 2 of other shapes: 5 were loculated. In the St. Bartholomew's Hospital material there are apparently only 2 cases, one of each kind. In material derived from Queen Square, there are 10 cases of which 7 had loculated aneurysms.

At first glance it would appear that there is only a slightly greater probability of loculated aneurysms bleeding again than of single round or oval sacs suffering the same disaster. A closer enquiry is, however, necessary because of uncertainties about the exact "population" of bleeding aneurysms which one is sampling.

There were, among the whole Maida Vale group of patients, 16 cases in which a medium sized or small, round or oval aneurysm was demonstrated and believed on reasonable grounds to be the source of bleeding, yet no immediate operation was performed. Some bled again. Some remained under observation until their final discharge and no record exists of fresh haemorrhage. Of these 16 cases, 5 bled again within 26 days (31%) (and one 5 years later) and 10 recovered without further bleeding.

Of the loculated aneurysms a smaller number could be followed in this way. Evidently the neurosurgeon (V. L.) was already aware of the bad prognosis of loculated aneurysms: a greater proportion were operated upon at once. The patients with loculated aneurysms *not* operated upon within the first four weeks after angiography are of two kinds. They are a very different group from the single round or oval ones. There were only 12 of them. 4 died within the first fortnight having shown a steady deterioration since the haemorrhage prior to angiography (3 of the 4 died within 4 days). 1, who had a very large aneurysm, died 3 years later – the cause of death remains unknown. 1 died after a recurrent haemorrhage on the 9th day. In 6 cases there had been no recent haemorrhage (they had other recent symptoms such as third nerve palsy), nor in them was there any recurrence during the whole period of follow-up. The probability in this series of death within two weeks from a loculated aneurysm which had bled recently was over 80% (compared with 31% for round or oval ones).

Since, however, as is clear, the management of the patients has influenced the proportions of patients with different radiological appearances, one must be very careful in comparison of one group with another. It would appear that loculation has an evil prognostic import if the aneurysm has bled recently. Can this also be established by comparison of other patients

who did have surgery within the first few weeks? By such a comparison, one may exclude all patients where there is uncertainty about the source of the haemorrhage, and at the same time compare those whose clinical signs are more likely to be similar as far as the indications for surgery are concerned.

What of those that came to early operation? There were 25 round or oval, medium or small-sized aneurysms which were eventually proven bleeders at operation. These 25 patients (Group A) had no further clinically diagnosed subarachnoid haemorrhage in the period ranging from 1-27 days prior to surgery. This group is to be compared with 21 patients (Group B) with loculated aneurysms who came to operation without bleeding again between 0 and 17 days later.

Thus the original population of $\frac{2}{3}$ loculated and $\frac{1}{3}$ round or oval aneurysms has changed prior to surgery, there having been a fall-out of the loculated type.

It is instructive to compare groups formed from different shaped aneurysms which suffered disaster and thus contributed to this fall-out. These patients either bled again and survived, Groups C and D (the bleeding aneurysm subsequently being proven by operation), or were allotted to groups E and F, who died usually from further haemorrhage. There were 15 patients with loculated aneurysms of which 4 bled again within 8 days but survived (Group D) and 11 died (73%) (Group F). On the other hand, there were only 9 patients with round or oval medium-sized aneurysms of which 4 bled again and survived (Group C) and 5 died (56%) (Group E).

Adding the figures, it can be seen that there were 34 round or oval aneurysms, Groups A, C and E, destined for death or surgery of which possibly 9 bled again, and of those nine 5 died (14%) before operation; while there were 36 patients with loculated aneurysms, Groups B, D and F, with the same two destinies of which perhaps 15 bled again, 11 dying (31%) before operation.

It would be important to know for certain how many of these deaths might have been preventable by early operation, and how many were the unavoidable outcome of the first bleed. About this the records are not as helpful as they might be, but nevertheless the figures are sufficiently clear about the extremely bad prognosis of loculated aneurysms.

There may therefore be a greater justification for the risks of surgery in cases with loculated aneurysms than in patients with single round or oval ones.

Summary

Figures are presented which show that the probability of recurrent haemorrhage and death within one month from an aneurysm which had bled recently was twice as great (31% as against 14%) if at angiography the aneurysm was shown to be loculated.

Zusammenfassung

Es wird gezeigt, daß die Wahrscheinlichkeit einer rezidivierenden Hämorrhagie und des Todes innerhalb eines Monats nach einem kürzlich blutenden Aneurysma doppelt so groß ist (31% gegen 14%), wenn angiographisch nachgewiesen werden kann, daß dieses Aneurysma fächerförmig ist.

Résumé

L'auteur montre que la probabilité d'hémorragie récidivante et de décès dans le mois qui suit l'hémorragie d'un anévrisme est deux fois plus grande (31% contre 14%) si, dans l'angiographie, l'on voit que l'anévrisme est lobulé.

Riassunto

Vengono presentate delle statistiche, le quali mostrano che la probabilità di emorragie ricorrenti e di morte entro un mese da un'emorragia dovuta ad aneurisma è doppia (31% contro 14%), se all'angiografia l'aneurisma è apparso concamerato.

DU BOULAY G. H.: Some observations on the natural history of intracranial aneurysms. *Brit. J. Radiol.* 38, 721 (1965).

DU BOULAY G. H.: The natural history of intracranial aneurysms. *Amer. Heart J.* 73, 723-729 (1967).

HASSLER O.: On the etiology of intracranial aneurysms, in: FIELDS W. S. and SAHS A. C. (editors): *Intracranial aneurysms and subarachnoid haemorrhage*, p. 25-37. Charles C. Thomas, Springfield Ill. 1965.

SAHS A. L.: Observations on the pathology of saccular aneurysms. *J. Neurosurg.* 24, 792 (1966).

STEBBENS W. E.: Histopathology of cerebral aneurysms. *Arch. Neurol.* 8, 272 (1963).

Address of the author: Prof. G. H. du Boulay, M.D., Diagnostic Radiology Department, St. Bartholomew's Hospital, London E.C. 1.

Discussion

P. HUBER, Bern:

Herr Dr. du Boulay erwähnt die Korrelation zwischen Aneurysmen und Arteriosklerose. Es besteht aber eine gewisse Korrelation zwischen Arteriosklerose und Hypertonie. Wie ist nun die Korrelation zwischen Hypertonie und Aneurysmen?

G. H. DU BOULAY, London:

In my material there is an association between hypertension and subarachnoid haemorrhage, and indeed it is well known that bleeding aneurysms are found in cases of coarctation of the aorta.

If, however, the blood pressure is measured months after a haemorrhage (that is in patients other than those with coarctation), it may frequently be found to have returned to normal. Moreover, if a patient under observation has a subarachnoid haemorrhage, it may be found that the blood pressure has been temporarily elevated.

In short, although an association exists between aneurysms and established hypertension, in my opinion the association has been exaggerated.

M. MUMENTHALER, Bern:

I would like to make a comment and to ask a question. Dr. du Boulay told us, that he found in 7 out of 23 cases a rounded aneurysm, which nevertheless was the cause of the bleeding. Let us think of an aneurysm as a cube instead of a ball just for the sake of easy representation. On a lateral X-ray-view we then would expect to see a daughter-aneurysm only, if this comes out from the top, the bottom, the right or the left side. We would not be able to see it, if it came out from the front or the back. Therefore 2 out of 6 cases would not be visible, that means about 7 out of 23. Of course this is not correct, if your observations are based on more than one view. Then just forget about my comment. My question is about the role of the time-factor in the appearance of a daughter-aneurysm. Does it appear before the bleeding or after the bleeding and how long after it?

G. H. DU BOULAY, London:

1. I believe that we have always had, in this material, sufficient views of the aneurysm to assess its true shape. Where any doubt remains, the case was not considered.

2. The time interval of angiography before or after haemorrhage is of great importance. Usually it seems that loculus formation occurs just before haemorrhage, and the loculus frequently disappears spontaneously if the patient survives.

R. SIEBENMANN, St. Gallen:

I would like to ask two questions: 1. What is the role of elastica-defects in the pathogenesis of the berry aneurysms? 2. Did you observe in your material aneurysms of traumatic origin as described e.g. by KRAULAND?

G. H. DU BOULAY, London:

1. I agree that defects in the elastica are in the main responsible for intracranial aneurysms; but these defects are acquired, not congenital, and may well be the result of a process which often also leads to true, easily recognisable atheroma.

2. I have several cases in which berry aneurysms of the cerebral arteries have followed closed head trauma, two also following operative damage to arteries and one following fontanelle puncture in a baby. They are radiologically indistinguishable from the common berry aneurysm. I also have two cases of such aneurysms on the external carotid branches at sites of skull fracture.