

Zeitschrift: Bulletin der Schweizerischen Akademie der Medizinischen Wissenschaften = Bulletin de l'Académie suisse des sciences médicales = Bollettino dell' Accademia svizzera delle scienze mediche

Band: 28 (1972)

Artikel: The neurological hand

Autor: Wynn-Parry, C.B.

DOI: <https://doi.org/10.5169/seals-307910>

Nutzungsbedingungen

Die ETH-Bibliothek ist die Anbieterin der digitalisierten Zeitschriften. Sie besitzt keine Urheberrechte an den Zeitschriften und ist nicht verantwortlich für deren Inhalte. Die Rechte liegen in der Regel bei den Herausgebern beziehungsweise den externen Rechteinhabern. [Siehe Rechtliche Hinweise.](#)

Conditions d'utilisation

L'ETH Library est le fournisseur des revues numérisées. Elle ne détient aucun droit d'auteur sur les revues et n'est pas responsable de leur contenu. En règle générale, les droits sont détenus par les éditeurs ou les détenteurs de droits externes. [Voir Informations légales.](#)

Terms of use

The ETH Library is the provider of the digitised journals. It does not own any copyrights to the journals and is not responsible for their content. The rights usually lie with the publishers or the external rights holders. [See Legal notice.](#)

Download PDF: 19.10.2024

ETH-Bibliothek Zürich, E-Periodica, <https://www.e-periodica.ch>

The neurological hand

C. B. WYNN-PARRY

Lower motor neurone lesions affecting the hand are common in neurological practice. The *clinical differentiation* depends on a careful history and the decision as to whether the lesion affects the anterior horn cell, the peripheral nerve or the muscle. This in turn will depend on whether the affection is unilateral or bilateral, if sensory loss is present or absent and if the wasting and sensory defect is confined to the territory of one or more peripheral nerves or is global. A complete examination of the central nervous system will reveal if the lesion is systemic or confined to the hand.

Refinements of electrodiagnostic techniques in recent years have enabled us to localise the lesion not only to the site of the lower motor neurone – myelopathy, neuropathy or myopathy – but to determine the exact level at which a peripheral nerve is being compressed.

You will all be familiar with the electromyography (EMG) pattern in myelopathies – a much reduced pattern of giant units scanty fibrillation and normal or only mildly reduced motor conduction velocity (MCV) reflecting the capacity of surviving axons to incorporate denervated fibres into their motor unit territory.

Myopathies are rare in the hand – dystrophia myotonica and the Scandinavian distal myopathy being the only myopathies likely to be seen – but it is just in this situation where the EMG picture of a normal pattern of very low amplitude short duration units will be of great value in diagnosing the distal weakness as myopathic.

It is in the neuropathies that EMG techniques find their greatest role and I should like to spend some time illustrating their value in diagnosis. Conventionally a neuropathic process is associated with profuse fibrillation, polyphasic units in a progressively reduced pattern on volition reflecting the disintegration of the myelin of the preterminal axons and a reduced motor conduction velocity.

Experimental work has shown that there are probably two basic underlying pathologies in neuropathies, segmental demyelination and axis cylinder drop out – according to whether the disorder affects primarily the Schwann cell or the axis cylinder itself. – If axis cylinders are affected, the process is

random and one may find normal conduction velocities if the fastest conducting A fibres are spared, or moderately reduced if the fast fibres are affected. Thus estimation of the MCV in several nerves is necessary. - If the myelin is affected, then the process of saltatory conduct is deranged and the more severe the lesion the nearer the MCV will approach values for cable conduction of 5 m/sec and so segmental demyelination is associated with very low values for MCV - e.g. in the Guillain-Barré syndrome. If there is only a local area of segmental demyelination conduction across this segment is slowed while conduction above and below that segment will be normal, and we now know that localised segmental demyelination is the pathological process underlying pressure lesions of peripheral nerves or entrapment neuropathies.

GAMBAUT in 1880 described myelin disappearing from part or the whole of an inter-nodal segment without distal degeneration in guinea-pigs who had been poisoned with lead. In 1957 WAKSMAN et al. showed that experimental diphtheritic neuropathy in guinea-pigs and rabbits was associated with severe segmental demyelination, starting close to the nodes of Ranvier. KAISER and LAMBERT (1962) then studied conduction velocity in such guinea-pigs and showed marked slowing down to 20 m/sec with temporal dispersion. McDONALD (1962) showed that this was due to segmental demyelination not dropout of fast fibres. On recording in the nerve roots with single fibres he was able to show that conduction in the peripheral nerves was normal and that the velocity only decreased when different impulses reached the roots where segmental demyelination had occurred. It is known that guinea-pigs kept in wire mesh cages develop a neuropathy of the plantar nerves of the hind foot and histological examination shows localised demyelination with slowing of conduction in the leg but very marked slowing in the foot suggesting that the toxin made the nerve abnormally vulnerable to pressure - a true carpal tunnel syndrome.

In poisoning with triorthocresyl phosphate, isoniazid, and nitrofurantoin the neuropathy is due to primary neuronal damage with scanty segmental demyelination. The primary disorder is in the anterior horn cell. The amplitude to supramaximal response falls rapidly indicating loss of fibres but the conduction velocity remains normal. FULLERTON and BARNES (1966) studied acylamide neuropathy in rats (a poison in man) and showed only slight reduction in conduction velocity. This was confirmed in baboons and fibre counts showed that the slight slowing was due to loss of the large diameter fibres, which conduct at the fastest rate.

The technique for estimating MCV is as follows. Recording electrodes are placed over a muscle supplied by the nerve under investigation and the nerve stimulated with supra-maximal shocks at various accessible points.

The median nerve can be stimulated in the axilla, at the elbow, and at the wrist recording over abductor pollicis brevis, as this muscle is the least likely to have an anomalous nerve supply. The ulnar nerve can be stimulated in the axilla, at the elbow, and at the wrist, recording over abductor digiti minimi (Fig. 1), and the radial nerve in the axilla, at the spiral groove and just above the elbow. Photographic records are

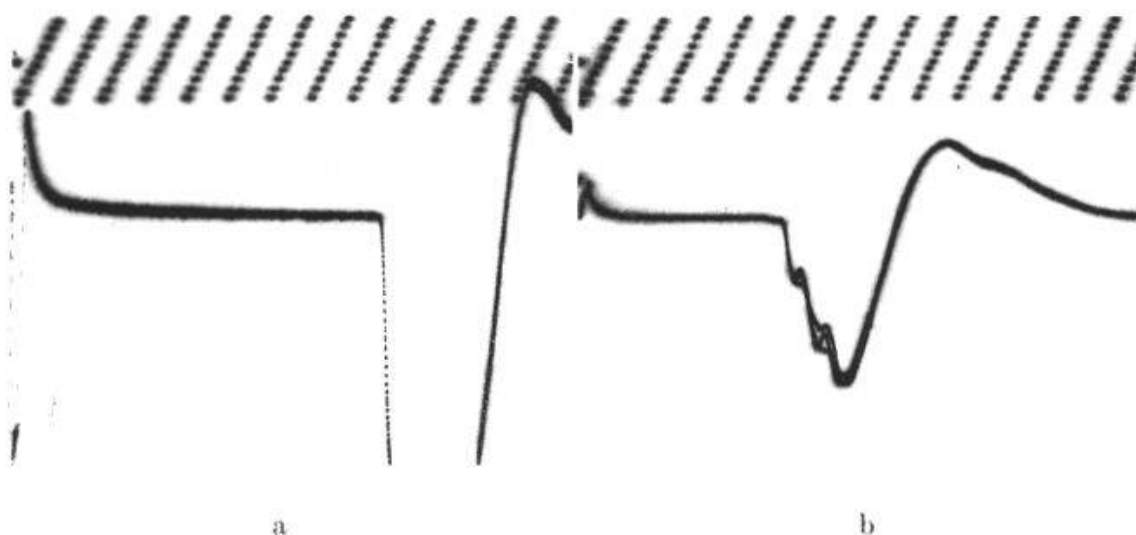


Fig. 1. Normal motor conduction studies. Stimulation of ulnar nerve at elbow (a), at wrist (b), recording in first dorsal interosseus muscle. Latencies 4.5 msec at wrist and 8.5 msec at elbow. Conduction velocity 55 m/sec. Time scale 1 msec.

taken and the latency - the time taken from the triggering stimulus to the onset of the integrated motor action potential measured in milliseconds, and the amplitude of the response are both measured.

Thus the motor conduction velocity can be measured in m/sec which has a normal value of approximately 50 m/sec, and amplitudes to supramaximal stimulation which should be more than 5 mV in the hand muscles and 3 mV in the foot - provide information as to the number of motor units active and any degree of decrement of response to the stimulus at various levels.

In the carpal tunnel syndrome, pressure on the nerve at the wrist under the carpal tunnel produces segmental demyelination and thus slow conduction. Normal latencies from wrist to abductor pollicis brevis are less than 5 msec. If the latency is 5-7 msec moderate damage is present and if more than 7 msec the damage is severe, and it has been shown by GOODMAN and GILLIATT that in such circumstances decompression is essential (Fig. 2). In the carpal tunnel syndrome there may be slight slowing of conduction in the forearm due to back pressure on the axoplasm of the nerve with values of 40 m/sec. One of the earliest signs of median nerve compression may be a slowed response at threshold shocks, the so-called late unit, which is obliterated at supramaximal shocks. Thus the response to threshold shocks must always be studied. Sensory conduction is often the first to be affected and must be measured in every case. Sensory conduction can now be studied easily by stimulating the fingers with ring electrodes and recording over the median and ulnar nerves with surface electrodes. Values of 10 μ V and latencies of 2.4 msec are found for the median nerve and 8 μ V and 2.3 msec for the ulnar nerve. Even very small abnormal responses can be recorded using averaging techniques. Radial sensory conduction can be studied by recording over the superficial radial nerve on the 1st dorsal interosseus space and stimulating the nerve over the radius in the mid forearm.

Conduction studies are a useful differential diagnosis in paraesthesiae due to cervical spondylosis and to carpal tunnel syndrome. In cervical spon-

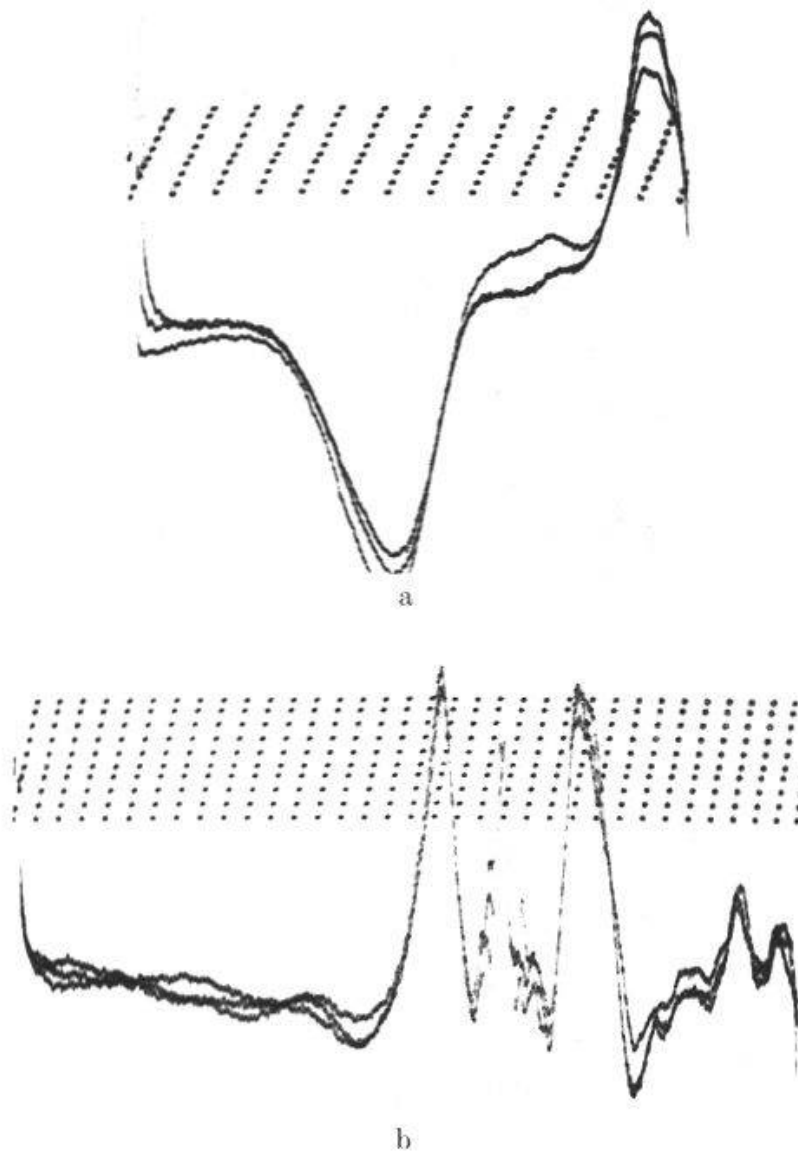


Fig. 2. - a) Recording by needle electrode in abductor pollicis brevis stimulating at wrist in normal subject latency 3 msec. - b) Recording by needle electrode in the abductor pollicis brevis stimulating at the wrist in a patient with the carpal tunnel syndrome, time scale 1 msec. - Note the prolonged latency and dispersed response due to slow conducting fibres.

dylosis normal latencies will be found whereas in the carpal tunnel syndrome, latencies will be prolonged or sensory studies may be abnormal. Pressure on the deep branch of the ulnar nerve shows slowing in the branches to the intrinsic muscles, but a normal latency to the abductor digiti minimi with normal sensory conduction as the superficial branch will be unaffected. It can readily be seen how useful such a test can be in a patient presenting with wasting of the ulnar supplied intrinsic muscles with no sensory symptoms. The demonstration of slowing of conduction localised to the deep branch excludes the diagnosis of early motor neurone disease.

One of the most useful applications of these conduction studies is in the diagnosis of the level of ulnar nerve compression. We have already seen how a lesion of the deep branch of the ulnar nerve can be identified, lesions

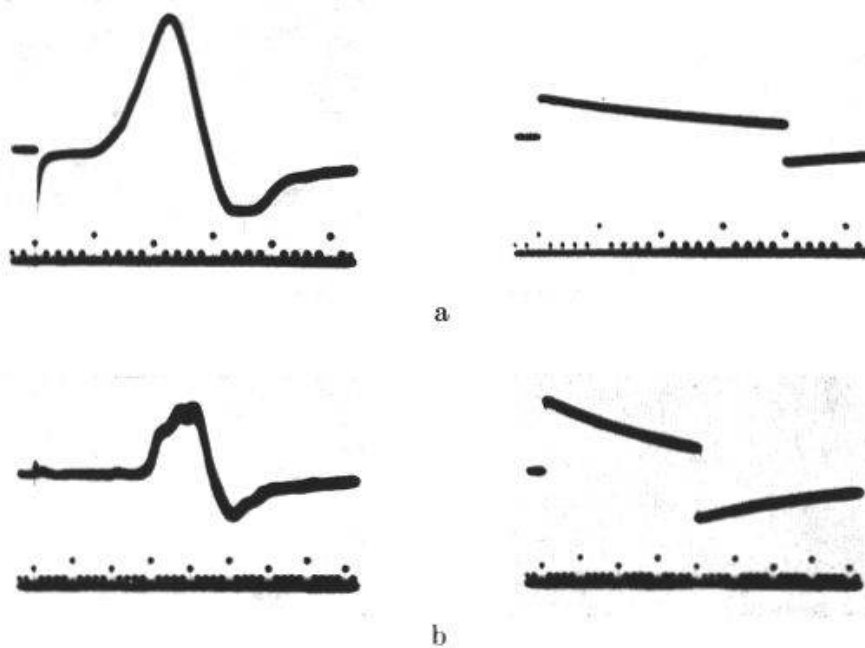


Fig. 3. - a) Ulnar nerve lesion at the elbow. Normal latency and amplitude (calibration 1 mV) with supramaximal stimulation at the wrist and recording with surface electrodes over the abductor digiti minimi. - b) Stimulation above the elbow. - Note prolonged latency and pronounced decrement in amplitude.

at the elbow can also be readily diagnosed. The ulnar nerve is stimulated at the wrist, below the elbow, above the elbow and in the axilla, and conduction latencies, giving the MCV and amplitudes to supramaximal stimulation measured affording an index of the number of motor fibres responding (Fig. 3). Similarly sensory conduction can be measured in the finger, forearm and upper arm, and this is particularly important as sensory fibres are the most vulnerable to pressure and abnormalities of sensory conduction may be the only evidence of damage MCV being normal (Fig. 4).

Unless there has been very extensive demyelination due to pressure such as in long standing cervical rib compression root lesions do not cause distal slowing of conduction and the demonstration of normal sensory conduction in the little finger in the presence of paraesthesiae localises the lesion to the T1 root and not to the nerve while a normal median sensory potential and normal distal motor latency in a patient with paraesthesiae in the thumb, index and middle fingers suggests a root lesion, for example cervical spondylosis, rather than a carpal tunnel syndrome.

Sensory conduction studies are valuable also in brachial plexus lesions. The demonstration of a normal SAP in the presence of an anaesthetic hand indicates a pre-ganglionic lesion and a hopeless prognosis while an absent SAP suggests a post-ganglionic lesion and the possibility of some degree of regeneration. Thus EMG studies are valuable in distinguishing cord, root and nerve lesions and in localising the exact level of pressure in a peripheral nerve disorder. Examination of many nerves will also show the clinician whether an apparently isolated peripheral nerve lesion is not in fact the overt sign of a generalised polyneuropathy.

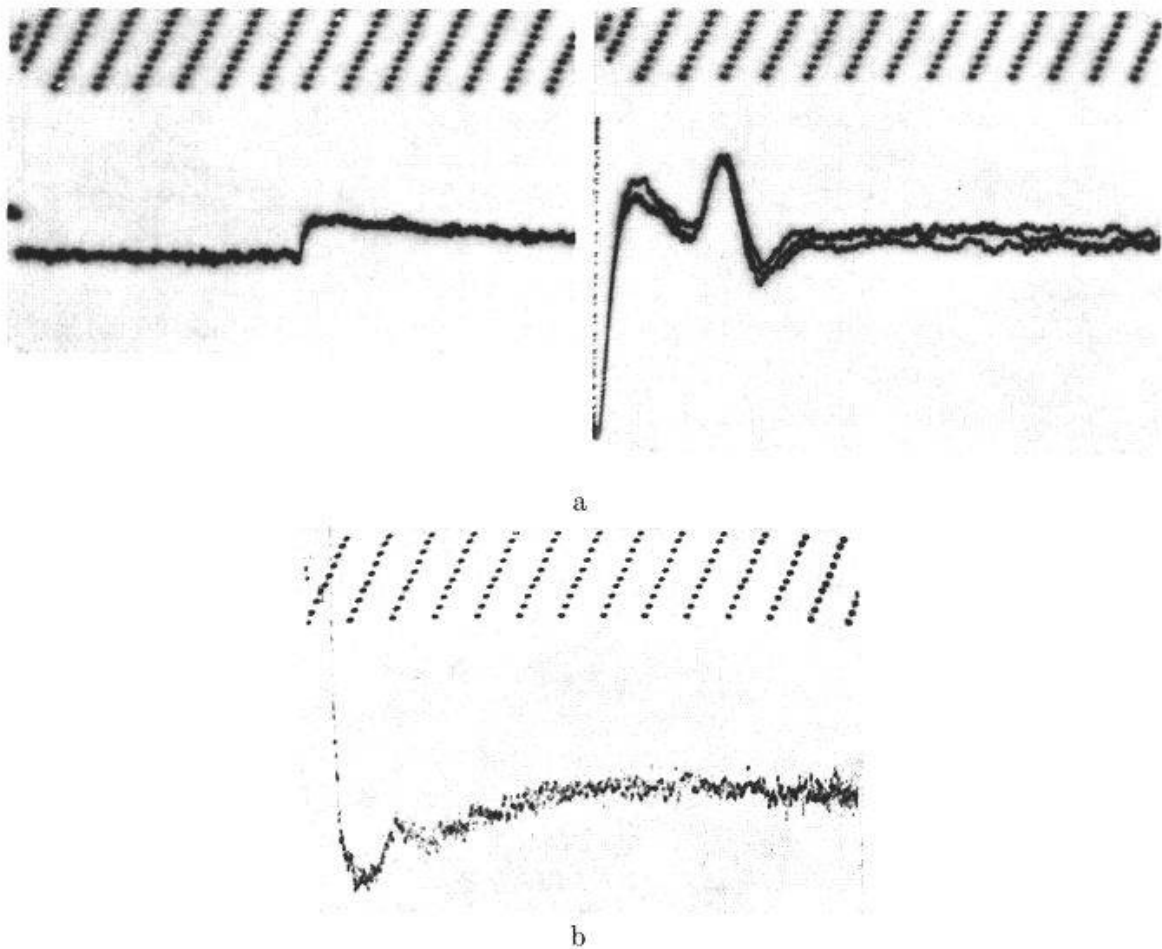


Fig. 4. - a) Normal sensory conduction. Index finger stimulated with ring electrodes and recording made with surface electrodes over the median nerve at the wrist. Time scale 1 msec, amplitude calibration $10 \mu\text{V}$. - b) Sensory potential in a patient with the carpal tunnel syndrome. Note reduced amplitude of response.

In the early stages of the Guillain-Barré syndrome distal weakness without sensory loss is not uncommon and the question of poliomyelitis or transverse myelitis may be raised. The demonstration of absent sensory conduction and a proximal block to motor conduction are characteristic of this disorder.

I would like to spend the remainder of my time discussing *some aspects of treatment*.

The demonstration of a localised pressure lesion will of course lead to appropriate surgery. Little can be done for motor neurone disease affecting the hand other than providing aids to daily living, or for myopathies other than preventing contractures. But in potentially recoverable lesions splintage to prevent deformity during the stage of paralysis and re-education of motor and sensory function during recovery are vital if the best results are to be obtained. During the stage of paralysis, while awaiting nerve regeneration after suture, there are certain deformities that are liable to arise due to overaction of antagonists unopposed by their paralysed agonists - the well known wrist drop in a radial palsy, the claw hand of an ulnar palsy and the ape hand of the median palsy. These must be corrected otherwise

the paralysed muscles and capsules and ligaments will be stretched and function seriously impaired after reinnervation. Today we recognise that it is not enough to prevent such deformities with a static splint, but lively splints must be provided which also encourage the patient to use his hand.

Thus the claw hand is provided with a splint that prevents hyperextension by stabilising the mp joints and by means of a spring wire coil hinge at these joints allows full use of the hand with only a slender bar in the palm, curved to maintain the palmar arch. Similarly a median splint puts the thumb into palmar abduction and a coil spring allows the long thumb flexor to be used as an opposer to the fingers. The wrist drop is prevented by a cock up with a lively spring at the wrist to allow full range of active flexion and extension. In brachial plexus lesions with a good prognosis a flail arm splint pioneered by FLETCHER at Roehampton can be provided with various attachments for tools so that the patient can return to work at an early stage.

As the muscles become reinnervated, the physiotherapist and occupational therapist must provide games, exercises and craft work to develop muscle power and co-ordination.

At all times the patient's interest and enthusiasm must be captured – men should be given carpentry, machine tool operating, metal work, radio or TV assembly – women should be encouraged to sew, make dresses, prepare and cook meals. At all times aids to daily living must be provided to ensure maximum independence – padded knives and forks, adapted razors, velcro fittings for clothing, elastic shoes obviating tying laces.

Surprisingly little attention has been paid to the re-education of sensation. ONNE has reported poor results after median nerve suture in adults, suggesting that values of recovery of two points discrimination is equal to the age of the patient – thus a 25-year-old man will only regain 25 mm discrimination on the finger tip. It is true that at 9 months after secondary suture of the nerves at the wrist protopathic sensation only will be present and it is commonly believed that stereognosis can never return. For the past 7 years we have been applying techniques of sensory re-education to our patients with nerve lesions and are most gratified by the functional results.

The rationale is to retrain the patient to relate the abnormal sensation of hyperaesthesiae to shapes and textures and thus identify objects correctly. The patient is blindfolded and presented with a series of large objects of obvious shape – cubes, rectangles, squares, hexagons – and asked to feel around them and state what shape they are. If he fails, he opens his eyes and feels the substance while looking at it and learns to relate the sensation of the particular object to the shape. Gradually he learns to achieve the correct answers by constant training. His efforts are timed and weekly charts kept. Later he is given a series of materials with different textures – wool, cotton, nylon, canvas, rubber, etc., and learns their identification. Different shapes are cut out of a board and the time taken to feel round the cavities and fill them with the correct shapes is recorded. Finally objects

in everyday use are identified. At regular intervals, materials, shapes and objects are given in a random order and the number of correct answers and the time taken are recorded and compared over the weeks. The patient is not allowed to know if he is right or not, so that a training effect is not produced.

Localisation is invariably poor after nerve suture and this again is systematically trained. The patient, blindfold again, is asked to point to where he is being touched and if incorrect, opens his eyes and learns to relate his incorrect sensation to the correct position. It is fascinating to note that at a certain stage of training patients will say that they know they are being touched at the tip of the index but it feels as if it is elsewhere.

Remarkable expertise can be developed with training and this is very markedly reflected in the patient's performance in the workshops. As soon as the patient develops awareness of his sensation, his skill in precision activities increases greatly. Patients are encouraged to train themselves and practice on their own after leaving the Centre for sensory function is easily lost by disuse. These techniques are also invaluable after neurovascular island transfers. When anaesthesia is permanent as in advanced leprosy the patient must be taught how to avoid damage to the skin by correct use of tools, gloves, and techniques at work.

I hope that I have been able to demonstrate to you this morning the wide range of diagnostic and therapeutic techniques that we now have at our disposal and that the neurological hand offers an exciting challenge to all members of the medical and paramedical team.

Summary

The differential diagnosis of lower motor neurone lesions affecting the hand can be facilitated by the use of modern techniques of electromyography. These allow one to distinguish myelopathies, neuropathies and myopathies, and studies of motor and sensory nerve conduction will determine the level of a pressure neuropathy.

During the stage of paralysis while awaiting regeneration after nerve suture the hand must be splinted both to prevent deformity, such as the claw hand of ulnar palsy, the dropped wrist of radial palsy and the 'ape hand' of median nerve lesions – such splints can be made 'lively' by the use of spring wire thus providing useful function and encouraging the patient to use his hand as much as possible.

Once reinnervation has started, rehabilitation of motor and sensory function is necessary to obtain the best results. Hand games and occupational therapy related to the patient's work and hobby will restore power and movement, but sensory re-education is essential in order to regain co-ordination and fine skills. These techniques are described in detail and the results of such a regime presented.

Finally, the importance of an intensive programme of treatment several hours a day by highly skilled therapists is stressed and the need for detailed supervision by an interested doctor at all stages of treatment.

Zusammenfassung

Die Differentialdiagnose der peripheren Nervenläsionen im Bereich der Hand kann durch die Anwendung moderner elektromyographischer Untersuchungsverfahren wesentlich erleichtert werden. Sie gestatten, sicher zwischen Myelopathien, Neuropathien und Myopathien zu unterscheiden, und die Bestimmung der motorischen und sensorischen Nervenleitungsgeschwindigkeiten ermöglicht die sichere Lokalisation einer Nervenkompression.

Im Lähmungsstadium, wenn nach der Nervennaht auf die Regeneration gewartet werden muss, muss die Hand zur Verhinderung der Entwicklung von Fehlstellungen (Krallenhand bei Ulnarisläsion, Fallhand bei Radialisparese, Affenhand bei Ausfall des Medianus) geschient werden. Mit Hilfe von Federdraht können derartige Schienen beweglich und funktionell gemacht werden, wodurch sie dem Patienten ermöglichen und ihn anregen, seine Hand in natürlichen Bewegungsmustern und soviel wie möglich zu gebrauchen.

Sobald die Reinnervation beginnt, müssen Motorik und Sensibilität intensiv trainiert werden, wenn beste Rehabilitationsresultate erzielt werden sollen. Handspiele und funktionelle Beschäftigungstherapie, die der Arbeit und den Hobbies des Patienten angepasst sind, werden Kraft und Beweglichkeit wiederherstellen; für die Wiedergewinnung von Koordination und Feingeschicklichkeit ist jedoch ein Sensibilitätstraining entscheidend. Die hierfür benutzten Trainingsmethoden werden im Detail besprochen und deren Resultate vorgelegt.

Schliesslich wird die Bedeutung eines Intensivbehandlungsprogramms während mehrerer Stunden pro Tag, das von hochqualifizierten Physio- und Ergotherapeutinnen geleitet wird, für diese Patienten hervorgehoben sowie die Notwendigkeit der kontinuierlichen Überwachung derselben durch einen auf diesem Gebiet besonders erfahrenen und interessierten Arzt.

Résumé

L'emploi de techniques modernes d'électromyographie permet de faire plus facilement le diagnostic différentiel des lésions du neurone moteur distal de la main. Ces techniques permettent de distinguer entre une myelopathie, une neuropathie et une myopathie, et l'étude de la conduction du nerf moteur et sensoriel détermine le niveau d'une neuropathie par compression.

Après une suture de nerf et en attendant sa régénération, il faut durant la phase de paralysie éclipser la main afin d'éviter une déformation, telle que la main en griffe de la paralysie cubitale, ou la chute du poignet de la

paralysie du nerf radial, ou encore la «main de singe» des lésions du nerf médian; ces éclisses peuvent être rendues plus «vivantes» en les faisant avec des fils métalliques souples, permettant une fonction et encourageant le patient à employer sa main le plus possible.

Une fois que la réinnervation a commencé, il faut faire une réhabilitation des fonctions motrices et sensorielles afin d'obtenir les résultats les meilleurs. Des jeux de mains et un travail manuel en rapport avec les occupations et les délassements du patient permettront de retrouver la force et le mouvement, mais une rééducation sensorielle est indispensable si l'on veut récupérer la coordination et les fins mouvements. Ces techniques sont décrites en détail et l'auteur présente quelques résultats de tels plans de travail.

L'auteur souligne enfin l'importance d'un programme de traitement intensif par des thérapeutes hautement qualifiés et durant plusieurs heures par jour, et la nécessité qu'un médecin qui s'intéresse à ces problèmes surveille jusque dans les détails les résultats obtenus à tous les stades du traitement.

Riassunto

L'uso delle tecniche moderne d'elettromiografia permette più facilmente di fare la diagnosi differenziale delle lesioni del neurone motore distale della mano. Queste tecniche permettono di distinguere fra una mielopatia, una nevropatia ed una miopatia. Lo studio della conduzione del nervo motore e sensitivo determina il livello di una nevropatia dovuta a compressione.

Durante la fase paralitica dopo sutura di un nervo, quando si aspetta la sua rigenerazione, bisogna fissare la mano con due stecche per evitare una deformazione quale la mano ad artiglio della paralisi cubitale, o la mano pendula della paralisi del nervo radiale, o ancora «la mano di scimmia» delle lesioni del mediano; queste stecche possono essere rese più «vive» costruendole con dei fili metallici pieghevoli che permettono una funzione e incoraggiano il paziente a far uso il più possibile della sua mano.

Una volta la reinnervazione cominciata, per ottenere i migliori risultati bisogna iniziare con la riabilitazione delle funzioni motrici e sensitive. Giochi di mano, come pure un lavoro manuale in relazione con le occupazioni e svaghi del paziente, permettono di ritrovare la forza e il movimento. Una rieducazione del nervo sensitivo è indispensabile, se si vogliono ricuperare le coordinazioni ed i movimenti fini. Queste tecniche sono descritte in dettaglio e l'autore presenta alcuni risultati di tali programmi di lavoro.

L'autore sottolinea infine l'importanza di un programma di terapia intensa da parte di persone altamente qualificate, durante parecchie ore al giorno, come pure la necessità che un medico interessato da questi problemi sorvegli in tutti i dettagli i risultati ottenuti a tutti gli stadi della cura.

FULLERTON P. M. and BARNES J. M.: *Brit. J. industr. Med.* 23, 210 (1966).

GOMBAULT A.: *Arch. Neurol. (Paris)* 1, 177 (1880).

HOPKINS A. P. and MORGAN HUGHES J. A.: *J. Physiol. (Lond.)* 189, 81 P (1967).

KAESER H. and LAMBERT E. M.: *Electroenceph. clin. Neurophys. Suppl.* 22, 29 (1962).
MCDONALD W. I.: *Acta neuropath. (Berl.)* 1, 425 (1962).
WAKSMAN B. M., ADAMS R. D. and MANSMANN H. C.: *J. exp. Med.* 105, 591 (1957).
ONNE L.: *Acta chir. scand. Suppl.* 300 (1962)
WYNN PARRY C. B. et al.: *Hand* 2, 31 (1970).

Address of author: Group Captain C. B. Wynn Parry, M.B.E., M.A., M.R.C.P.,
D.Phys.Med., R.A.F. Consultant Adviser in Physical Medicine, Joint Service Medical
Rehabilitation Unit, Royal Air Force, Chessington/Surrey, England.