

Zeitschrift: Schweizer Archiv für Tierheilkunde SAT : die Fachzeitschrift für Tierärztinnen und Tierärzte = Archives Suisses de Médecine Vétérinaire ASMV : la revue professionnelle des vétérinaires

Herausgeber: Gesellschaft Schweizer Tierärztinnen und Tierärzte

Band: 132 (1990)

Heft: 8

Artikel: Phalaris toxicosis in sheep in Spain

Autor: Fernández de Luco, D. / García Marín, J.F. / Badiola, J.J.

DOI: <https://doi.org/10.5169/seals-593367>

Nutzungsbedingungen

Die ETH-Bibliothek ist die Anbieterin der digitalisierten Zeitschriften. Sie besitzt keine Urheberrechte an den Zeitschriften und ist nicht verantwortlich für deren Inhalte. Die Rechte liegen in der Regel bei den Herausgebern beziehungsweise den externen Rechteinhabern. [Siehe Rechtliche Hinweise.](#)

Conditions d'utilisation

L'ETH Library est le fournisseur des revues numérisées. Elle ne détient aucun droit d'auteur sur les revues et n'est pas responsable de leur contenu. En règle générale, les droits sont détenus par les éditeurs ou les détenteurs de droits externes. [Voir Informations légales.](#)

Terms of use

The ETH Library is the provider of the digitised journals. It does not own any copyrights to the journals and is not responsible for their content. The rights usually lie with the publishers or the external rights holders. [See Legal notice.](#)

Download PDF: 05.02.2025

ETH-Bibliothek Zürich, E-Periodica, <https://www.e-periodica.ch>

Dpto. Patología Animal. Facultad de Veterinaria. Zaragoza, Spain

PHALARIS TOXICOSIS IN SHEEP IN SPAIN

D. Fernández de Luco, J. F. García Marín, J. J. Badiola, A. Ortillés

Ruminants grazing pastures of phalaris grass (*Phalaris aquatica* and *Phalaris arundinacea* mainly) sometimes produce—depending on environmental factors (20) — a toxic syndrome with nervous symptoms described in sheep and cattle [Argentina (1, 4), Australia (12), United States (5, 13), Norway (19) and New Zealand (14)], showing peracute, acute and chronic forms of the disease (8). In the acute and chronic syndrome the affected animals show hyperexcitability, head nodding, tendency to walk on the carpi, gait abnormality, muscle tremors and ataxia. Animals with lateral recumbency, convulsive spasms and extensive rigidity of the limbs can also be detected. The peracute form is characterized by sudden death (4, 5, 6, 11, 12, 14, 17, 18). Phalaris plants contain N-N, dimethylindolealkylamine alkaloids (3) resembling serotonin, that ingested in high concentrations can be toxic for the organism by competitively inhibiting the action of the enzyme monoamino-oxidase in serotonin and other amines, principally catecholamines (6). Experimentally, oral and intravenous administration of these alkaloids produces only the acute syndrom of the disease (2, 9). In this report, we describe a poisoning in the spring by phalaris, plants that are present commonly on spontaneous pasture areas.

In the spring of 1989 a flock of 500 ewes located in the North-East of Spain (Zaragoza) was affected by a process which involved nervous disorders, habing a mortality rate of 12%. Initially, the affected animals showed nervous signs, characterized by hyperexcitability, persistent head nodding, gait abnormality and a tendency to walking on the carpi. Later, ataxia and lateral recumbency with convulsive spasms and rigidity of the limbs could be detected. The symptoms were exacerbated after excitement and the animals frequently fell down. The flock had been grazing on arid land with spontaneous vegetation and phalaris plants could be found on the waysides. These plants were identified as *Phalaris brachystachys*.

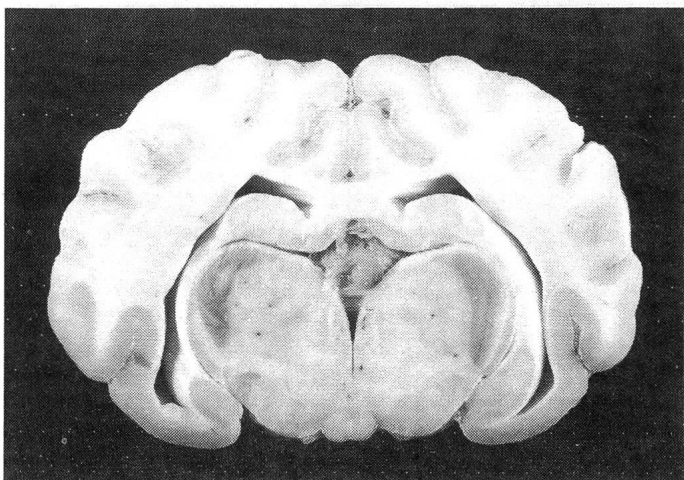


Fig. 1: Gray-green discoloration in the lateral geniculate bodies of a sheep with Phalaris toxicosis

Five affected animals were necropsied. Macroscopically, numerous seeds were found in the rumen and abomasum, being identified as phalaris. After fixing the encephalon in buffered formalin of 10%, a grey-green coloration in the lateral geniculate bodies located in the back of the thalamus was noted in the serial cross-section of the encephalon (Fig. 1). Other nuclei had a mild pigmentation. Grossly, the kidney did not show any particular coloration.

Histologically, sections, 4 µ thick, and haematoxilin-eosin (H-E) stains were made routinely. The Periodic Acid-Schiff technique, Long Ziehl-Neelsen Method for Acid Fast Lipofuscins, Perls' Method for Ferric Iron and Alternative Nile Blue Method for melanin and lipofuscins were also applied as special stains (16). Microscopically, a brown and granular pigment (H-E) in the cytoplasm of several neurons of the encephalon and spinal cord, except for the cerebellum, was observed, being negative in the special stains. Many of these neurons were hyperchromatic and shrunken. Mild and disseminated neuronophagia, gliosis, perivascular cuffing and macrophages with pigment were seen in some sections. Demyelination was evident in the white matter, principally in the «pedunculus cerebellaris inferior», «fasciculus longitudinalis medialis», in periventricular areas of the encephalon and in the ventral horns of the cervical and lumbar spinal cord. Histologically, the kidney showed tubulonephrosis; a granular and brown pigment was present when applying H-E stain and a bright blue colour when using the Perls' Method stain.

Diagnosis of phalaris toxicosis was made on the basis of nervous symptoms and pathological findings. No report on this disease can be found in the Spanish bibliography. Toxicosis by the ingestion of *P. aquatica* (12), *P. arundinacea* (18), *P. caroliniana* (15) and *P. minor* (13) has been reported in other countries but not with *P. brachystachys*. The nervous symptoms and the pigment observed in the lateral geniculate bodies are similar to those previously reported by different authors. Degenerative changes in the white matter are also in agreement with the existing bibliography. The presence of perivascular cuffing (10), gliosis and astrocytosis (5) has not been sufficiently described. Macroscopic pigmentation ist rare in the kidney, whereas histologically it is a common finding (7, 8), although not consistent (18). This pigment was identified as haemosiderin, being in agreement with the first description made by McDonald (12).

References

1. Bedotti D. O., Frecentese M. A. (1986): Therios 8, 367. — 2. Bourke C. A. et al. (1988): Aust. Vet. J. 65, 218. — 3. Culvenor C. C. J. et al. (1964): Aust. J. Chem. 17, 1301. — 4. Del Potro D. H. et al. (1984): Vet. Arg. 1, 763. — 5. East N. E., Higgins, R. J. (1988): J.A.V.M.A. 142, 667. — 6. Gallagher C. H. et al. (1966): Aust. Vet. J. 42, 279. — 7. Gallagher C. H. et al. (1966): New Sci. 31, 412. — 8. Gallagher C. H. et al. (1967): Aust. Vet. J. 43, 495. — 9. Gallagher C. H. et al. (1964): Nature 204, 542. — 10. Hartley W. J., Kater J. C. (1962): N. Z. Vet. J. 10, 128. — 11. Lean I. J. et al. (1989): J.A.V.M.A. 195, 768. — 12. Mc Donald I. W. (1942): Aust. Vet. J.