

# Light- and electronmicroscopical effects of atrazine in rainbow trout (*Oncorhynchus mykiss*) after subchronic exposition

Autor(en): **Hoffmann, R. / Fischer-Scherl, T. / Veese, A.**

Objektyp: **Article**

Zeitschrift: **Schweizer Archiv für Tierheilkunde SAT : die Fachzeitschrift für Tierärztinnen und Tierärzte = Archives Suisses de Médecine Vétérinaire ASMV : la revue professionnelle des vétérinaires**

Band (Jahr): **132 (1990)**

Heft 8

PDF erstellt am: **11.09.2024**

Persistenter Link: <https://doi.org/10.5169/seals-593538>

## **Nutzungsbedingungen**

Die ETH-Bibliothek ist Anbieterin der digitalisierten Zeitschriften. Sie besitzt keine Urheberrechte an den Inhalten der Zeitschriften. Die Rechte liegen in der Regel bei den Herausgebern.

Die auf der Plattform e-periodica veröffentlichten Dokumente stehen für nicht-kommerzielle Zwecke in Lehre und Forschung sowie für die private Nutzung frei zur Verfügung. Einzelne Dateien oder Ausdrucke aus diesem Angebot können zusammen mit diesen Nutzungsbedingungen und den korrekten Herkunftsbezeichnungen weitergegeben werden.

Das Veröffentlichen von Bildern in Print- und Online-Publikationen ist nur mit vorheriger Genehmigung der Rechteinhaber erlaubt. Die systematische Speicherung von Teilen des elektronischen Angebots auf anderen Servern bedarf ebenfalls des schriftlichen Einverständnisses der Rechteinhaber.

## **Haftungsausschluss**

Alle Angaben erfolgen ohne Gewähr für Vollständigkeit oder Richtigkeit. Es wird keine Haftung übernommen für Schäden durch die Verwendung von Informationen aus diesem Online-Angebot oder durch das Fehlen von Informationen. Dies gilt auch für Inhalte Dritter, die über dieses Angebot zugänglich sind.

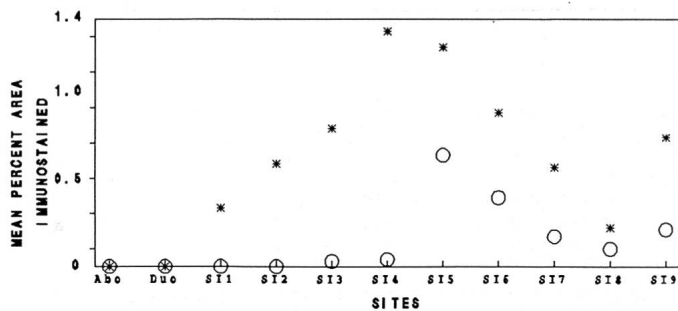


Fig. 1: Mean percent area immunostained for rotavirus antigen in the epithelium of the abomasum, duodenum and 9 small intestinal sites of one-day-old (\*) and ten-day-old (o) gnotobiotic calves.

24 hours after inoculation, when the peak titre of virus in faeces ( $10^{8.8}$ – $10^{9.2}$ ) occurred. The peak titre of virus in faeces of calves inoculated at ten-days-old ( $10^{5.7}$ – $10^{7.9}$ ) was detected between 48 and 72 hours after inoculation.

The mean percent area of epithelium immunostained in the small intestine was greater in calves inoculated at one-day-old than in the calves inoculated at ten-days-old; immunostaining was present throughout the small intestine in one-day-old calves but absent from the upper small intestine of calves inoculated at ten-days-old (Fig.). In the calves inoculated at one-day-old, enterocytes were exfoliated and villi stunted and fused and enterocytes remaining in the epithelium were cuboidal. Villus height was reduced to 50% of control

values in the mid and distal small intestine. Foci of enterocyte exfoliation and cuboidal enterocytes in the epithelium were seen in calves inoculated at ten-days-old, but villus height was not affected. Crypt cell production rates were increased in both groups of calves, compared with controls, in the proximal, mid and distal small intestine.

### Discussion

This study explains why the outcome of rotavirus infection differs in calves of different ages. In calves of both ages, the rotavirus used here infected and killed enterocytes but the inability of this strain to cause diarrhoea in ten-day-old calves appeared to be related to its inability to cause severe intestinal damage; it was not able to kill enterocytes faster than they could be replaced. There were differences in susceptibility of the gut to damage by this rotavirus in the two age-groups of calves; these host differences require further investigation.

### References

1. Bridger JC. (1988): J Med Micro 27, xi–xii.
2. Hall GA. et al. (1988a): Proc 15<sup>th</sup> World Buiatrics Congress, Palma de Mallorca. 915–920.
3. Hall GA. et al. (1988b): Res Vet Sci 45, 240–250.
4. MacDonald TT., Ferguson A. (1978): Gastroenterology 74, 496–500.
5. McNulty MS., Logan EF. (1983): Vet Rec 113, 333–335.
6. Parsons KR. et al. (1984): J Clin Pathol 37, 645–650.

Institut für Zoologie und Hydrobiologie, Universität München, FRG

### LIGHT- AND ELECTRONMICROSCOPICAL EFFECTS OF ATRAZINE IN RAINBOW TROUT (ONCORHYNCHUS MYKISS) AFTER SUBCHRONIC EXPOSITION

R. Hoffmann, Th. Fischer-Scherl, A. Veiser

Atrazine has become one of the most frequently used ingredients of herbicides in the last decade. It enters the aquatic environment by run-offs from agriculturally used areas. Morphological investigations of fish with atrazine have primarily been performed with very high concentrations. These high concentrations, however, normally occur in the environment only after accidents for a short period. To achieve more information on this water pollutant and its impacts on fish in sublethal concentrations, rainbow trout (*Oncorhynchus mykiss*) were used to assess the effects of various atrazine concentrations.

Atrazine was dissolved to a saturated mixture, filtered and added constantly to aquaria with a capacity of 36 l by mixing the original solution with tapwater by means of a dispenser. Atrazine concentration was measured regularly by a gaschromatograph at the beginning, during and at the end of the experiment to ensure the constant test concentration. Water temperature was 10.5°C at a flow rate of 2 l/h, pH 7.6 and conductivity was 744 µS/cm. Chronic exposure to atrazine was performed at concentrations of 5, 10, 20, 40 and 80 µg/l for 28 days and acute exposure was done at concentrations of 1.4 and 2.8 mg/l for 96 h. For each concentration two tests with 10 fish each were performed simultaneously. Additionally, for each test two control

groups each with ten fish were examined. The mostly affected organs were gills and kidney.

Chronic exposure resulted in gills in hypertrophia as well as hyperplasia of chlorid cells. A low percentage of them had first signs of degeneration in lower concentrations (5–20 µg/l) whereas in higher concentrations (40–80 µg/l) degeneration was more prominent than hyperplasia. Acute exposure induced an immense proliferation of chlorid cells which were degenerated in a high percentage.

In kidney both the excretory as well as the hemopoietic parts were affected. At chronic exposure, podocyte proliferation, mesangial proliferation and thickening of glomerular basement membrane took place indicating a membrano-proliferative glomerulonephritis. Furthermore, a periglomerular fibrosis was seen in higher concentrations. Acute exposure induced an obliteration of Bowman's space due to proliferated mesangial cells.

The tubular system was especially affected at acute exposure showing extensive vacuolar degeneration.

In the hemopoietic tissue an increase of mitotic figures was the result of low concentrations. Higher concentrations at chronic exposure as well as acute intoxication resulted in a degeneration of sinus endothelia and hemopoietic cells.

The results document that atrazine has a toxicity for gills and renal and hemopoietic tissue also in fish. Even relatively low concentra-

tions comparable to those in some surface waters may induce distinct lesions at chronic exposure.

*Institut für Immunologie, GSF, Munich, FRG*

**T-LYMPHOCYTE SUBPOPULATIONS IN FIV-POSITIVE AND -NEGATIVE CATS**

*G. Hoffmann-Fezer, I. Thum, C. Ackley, J. Mysliwicz, K. Hartmann, W. Kraft*

Strong similarities have been shown between feline immunodeficiency virus infection (FIV) and the human AIDS-complex concerning virus structure as well as clinical and epidemiological manifestations (Pedersen, 1989; Yamamoto et al., 1989).

The human counterpart HIV is known to infect predominantly CD4<sup>+</sup> T helper lymphocytes and cells of the monocyte/macrophage lineage (Detels et al., 1983; Levy, 1985; for review Sattentau et al., 1988). Gradual reduction in CD4<sup>+</sup> T helper subpopulation absolute numbers as well as in percentage is one of the most striking immunological consequences of HIV infection. We wondered if T-helper and T-suppressor lymphocytes were also changed in FIV-infected cats.

Therefore we have examined peripheral blood lymphocytes of FIV antibody positive domestic cats using recently developed monoclonal antibodies against cat CD4 homologue (Ackley et al., 1990) and cat CD8 homologue (Klotz et al., 1986).

The most prominent clinical symptoms of cats included in this study were: chronic infections of the mouth, chronic upper respiratory infections, fever, chronic infections of the skin, inappetence, weight loss and in some cats, neurological signs or uremia. Control animals were FIV and FeLV seronegative cats without signs of disease.

Immunofluorescence analysis of mononuclear cells of peripheral blood was performed as two-colour staining using goat-anti-cat-Ig-PE for demonstration of B-cells together with either FITC-labeled anti-fCD4 or FITC-labeled anti-fCD8. Lymphocytes were analysed by automated flow cytometry (FACScan, Becton Dickinson, Mountain View, CA). FACS analyses of peripheral blood lymphocytes of healthy seronegative cats revealed a percentage of 37% of fCD4<sup>+</sup> cells and 11.36% of fCD8<sup>+</sup> cells (table), whereas seropositive cats had 26% fCD4<sup>+</sup> and 17.2% fCD8<sup>+</sup> labeled lymphocytes, all of which

were negative for feline Ig. The percentage of Ig<sup>+</sup> B-lymphocytes in seropositive cats were not different from those of seronegative animals.

When the absolute numbers of fCD4<sup>+</sup> and fCD8<sup>+</sup> cells were calculated, there was a similar appearance of figures, however an increase in fCD8<sup>+</sup> cells was less prominent than a decrease in fCD4<sup>+</sup> cells.

Changes in T-cell subsets in FIV-antibody positive, clinically affected cats show a clear tendency of decreased fCD4<sup>+</sup> cells and of an increase in fCD8<sup>+</sup> lymphocytes. These alterations result in a fCD4/fCD8 ratio of 1.6 in FIV-positive cats compared with a ratio of 3.4 in control animals. A relationship between severity of illness and low fCD4<sup>+</sup> cells counts (as demonstrated in HIV-infection) could be revealed. But there were also low fCD4<sup>+</sup> values in cats without severe clinical symptoms. A correlation between virus antigen positivity and fCD4<sup>+</sup> counts could not be detected, since virus positivity is not yet available. The alterations in T-cell subsets are a further evidence for a strong similarity between human AIDS and FIV induced feline AIDS-like disease concerning the pathogenesis. Therefore FIV induced disease is an animal model better suitable for treatment and immunization approaches than for example, SIV infections.

Table: Percent and absolute numbers of fCD4<sup>+</sup> and fCD8<sup>+</sup> cells in FIV seropositive and seronegative cats.

	CD4 <sup>+</sup> %	abs/μl	CD8 <sup>+</sup> %	abs/μl	CD4/CD8 ratio
seropositive n = 20	26.05 <sup>±</sup> 10.02	733 <sup>±</sup> 461	17.2 <sup>±</sup> 7.9	477 <sup>±</sup> 382	1.6 <sup>±</sup> 0.83
seronegative n = 22	37.32 <sup>±</sup> 14.11	1305 <sup>±</sup> 761	11.36 <sup>±</sup> 3.98	379 <sup>±</sup> 153	3.4 <sup>±</sup> 1.6

*Institute of Veterinary Pathology, University of Berne, Switzerland*

**ALTERNATIVES TO IN VIVO ANIMAL EXPERIMENTATION: DEVELOPMENT OF A NOVEL IN VITRO ASSAY TO STUDY NEUTROPHIL-ENDOTHELIUM INTERACTION**

*W. Holden, R. Zwahlen, M. Holub*

Adhesion of neutrophil granulocytes (PMN) to endothelial cells (EC) is an essential event in the triggering of further steps in the inflammation process. A substantial number of drugs such as steroidal or non-steroidal antiinflammatories are used either therapeutically or prophylactically. Therefore, it is important to study the mechanisms of action of those drugs and their eventual cytotoxic effects on the endothelium.

We developed a novel physiological model, based on endothelial cell culture to study those cellular interactions in conditions simulating

the *in vivo* situation. Cultures of EC were initiated from bovine aortas obtained at the local slaughterhouse. The cells were isolated enzymatically with collagenase 0.2%. The primary cultures were fed with growth medium containing 10% fetal calf serum and antibiotics. After the first passage the cells were fed with a medium free of antibiotics to preserve the integrity of the receptors. The cells were passaged until purity: the endothelial nature was confirmed morphologically by the typical «cobblestone pattern» and immunohistochemically by the presence of factor VIII (Fig. 1). In the final stage of the culture, the EC were grown on collagen-coated microcarriers