

**Zeitschrift:** Schweizer Archiv für Tierheilkunde SAT : die Fachzeitschrift für Tierärztinnen und Tierärzte = Archives Suisses de Médecine Vétérinaire  
ASMV : la revue professionnelle des vétérinaires

**Herausgeber:** Gesellschaft Schweizer Tierärztinnen und Tierärzte

**Band:** 132 (1990)

**Heft:** 8

**Artikel:** Endogenous lipid pneumonia, a new type of pneumonia in birds : a possible model in human cholesterol pneumonia research?

**Autor:** Müller, M. / Zangger, N.

**DOI:** <https://doi.org/10.5169/seals-593634>

### **Nutzungsbedingungen**

Die ETH-Bibliothek ist die Anbieterin der digitalisierten Zeitschriften. Sie besitzt keine Urheberrechte an den Zeitschriften und ist nicht verantwortlich für deren Inhalte. Die Rechte liegen in der Regel bei den Herausgebern beziehungsweise den externen Rechteinhabern. [Siehe Rechtliche Hinweise.](#)

### **Conditions d'utilisation**

L'ETH Library est le fournisseur des revues numérisées. Elle ne détient aucun droit d'auteur sur les revues et n'est pas responsable de leur contenu. En règle générale, les droits sont détenus par les éditeurs ou les détenteurs de droits externes. [Voir Informations légales.](#)

### **Terms of use**

The ETH Library is the provider of the digitised journals. It does not own any copyrights to the journals and is not responsible for their content. The rights usually lie with the publishers or the external rights holders. [See Legal notice.](#)

**Download PDF:** 05.02.2025

**ETH-Bibliothek Zürich, E-Periodica, <https://www.e-periodica.ch>**

Additional information about the staining method and other technical procedures are also recorded for each finding.

Standardization of names is just one prerequisite for a systematized nomenclature. A similar important requirement is the use of the same diagnostic criteria to characterize a specific lesion. Detailed descriptions and definitions for all tumors and pre-neoplastic lesions in all organ systems have been worked out by a team of 25 pathologists. Those manuscripts include definitions about the light microscopic features and criteria for the differentiation of hyperplastic lesions, benign tumours and malignant tumours.

In the *registry* data base there are actually two nomenclature systems: In the first system all topographical parts in common lesion names are stored consequently as subtopographies and the lesion name consists only of the morphological classification. The second preserves the more popular structure of lesion names (e.g. WHO nomenclature) to allow an easy data transfer from other pathology software systems to the data base. For example, the diagnosis «adenoma, follicular cell» in the organ «thyroid gland», is stored in this form

*Institute of animal pathology, University of Berne*

## **ENDOGENOUS LIPID PNEUMONIA, A NEW TYPE OF PNEUMONIA IN BIRDS: A POSSIBLE MODEL IN HUMAN CHOLESTEROL PNEUMONIA RESEARCH?**

*M. Müller, N. Zangger*

Endogenous lipid pneumonia, foam-cell pneumonia, is characterized by large accumulations of foamy macrophages within alveoli. The disease is encountered in man, laboratory rodents, cats, rarely in dogs. The etiopathogenesis is not yet fully understood. For the first time endogenous lipid pneumonia is described in budgerigars and hummingbirds. Obesity and circulatory resistance will be discussed in this connection as possible causes.

### **Material and methods**

During 1988–1989 in eleven budgerigars from different owners and in two hummingbirds from the Basle Zoological Garden we suggested macroscopically an endogenous-lipid pneumonia. Tissues were prepared as usual. Routine bacteriological cultures were made from lung, spleen and liver. Hematology and blood chemistry were not worked up.

### **Results**

The eleven adult budgerigars were either obese (six), normal (three) or underweight (two); the two hummingbirds were slightly underweight. Grossly, the lungs had bilateral multiple irregularly distributed white, in severe cases more yellowish, firm foci. Most of the foci were subpleural and appeared as sharply defined, extended parabronchi. A marginal emphysema and generalized congestion were common. The filled parabronchi, the emphysema and the congestion rendered the lung swollen. A viscid milky fluid exuded from the cut surface.

Histologically, the bulk of the lesions was composed of distended parabronchi and alveoli filled with large, foamy macrophages. The cytoplasm was SUDAN-positive, less PAS-positive. There was only

using the second nomenclature system. In the first system, the diagnosis is translated to «adenoma» which is stored under the subtopography «thyroid, follicle». Both nomenclature systems are set up in a way that a translation in both directions can be performed automatically.

The hierarchical structure of the systematized nomenclature systems makes it very easy to perform different kinds of computerized data evaluation. Incidence reports for example can be produced on various «topographical levels»: The incidence of a particular tumour can be summarized for a whole organ system, for a single organ, including all related subtopographical sites, or for a single subtopography. In those reports, modifiers can be included to give more detailed information on a growth pattern. The multiplicity of tumours can be taken into account if necessary for a particular data evaluation.

### **Literature**

*I. Mohr U. et al.: Exp. Pathol. 38, 1–18.*

a small amount of interstitial fibrosis and accumulation of lymphocytes and plasma cells. In severe cases regions of alveolar type II cell proliferation as well as hypertrophic parabronchiolar muscles were prominent. Cholesterol crystals and giant cell granulomas were established in the obstructive pneumonia.

In eight birds the cause of death was a tumour in the abdominal cavity: leucosis (spleen, liver), reticulo-SA (spleen), fibro-SA (spleen, 2), cholangiocyst-CA (liver), lipo-SA (liver), lipoma (abdominal cavity), non-differentiated ovary tumour. A marked liver cirrhosis in two cases and a generalized arteriosclerosis in one bird had affected the circulatory.

### **Discussion**

For the first time endogenous lipid pneumonia is described in birds. The endogenous lipid pneumonia is a typical alveolar filling disorder. The causes are not yet clearly defined. In man and mammals, the accumulation of alveolar macrophages is associated with bronchitis or obstruction of alveolar clearance, either intrinsically by a tumour or extrinsically from compressing lymphnodes. Excessive production of macrophages and reduction of their mobility by ingested surfactant or serum-derived lipids are further causes. Also the acellular pulmonary alveolar lipoproteinosis may evolve through an endogenous-lipid pneumonia, almost desquamative in type. Several causal influences may be postulated in the etiology in birds: – Six of the eleven budgerigars were obese. An increased number of foamy cells was found in lungs of rats that had been fed diets rich in cholesterol or triglyceride. – A pathological surfactant has also been described. Cholesterol is able to deactivate normal surfactant. – Tumours in the abdominal cavity, arteriosclerosis, liver cirrhosis as well as the obesity are factors which increase blood pressure. In rats,

the contents of alveoli have been reported as phagozyted transudates due to increased capillary permeability.

The budgerigar may be an adequate spontaneous animal model for research in human endogenous lipid pneumonia.

*Departamento de Patología Animal, Universidad de Santiago de Compostela, Facultad de Veterinaria. Spain.*

**HISTOPATHOLOGICAL, IMMUNOHISTOCHEMICAL AND ELECTRON MICROSCOPIC METHODS FOR THE DIAGNOSIS OF FOX DISTEMPER INFECTION**

*JM. Nieto, L. Ferrer, S. Vidal, D. Fondevila, R. Fernández*

Distemper virus (DV) is a Morbillivirus pathogenic for dogs, minks, foxes and others Mustelidae that produces different clinical diseases according to the strain of virus, virus dose, susceptibility and immune response of the host (2, 3, 7). DV is highly transmissible and 20-80% of the infected animals die (1, 4).

DV – air-borne first multiplies in the lymphoid tissue and then spreads by the leukocytes 8-9 days post infectionem to the epithelial and nervous cells (1).

Several morphological methods are used for the identification of DV infections like histopathological demonstration of inclusion bodies or immunohistochemical identification of viral antigen (5, 8, 9).

The purpose of this study was to report the distribution of inclusion bodies and viral antigen in non vaccinated naturally infected foxes by means of histopathological, immunohistochemical and ultrastructural techniques.

**Material and methods**

Samples of lungs, trachea, spleen, lymph nodes, kidney, urinary bladder and nervous system were obtained from 8 foxes naturally infected with DV, and fixed in 10% phosphate buffered formalin and 2.5% buffered glutaraldehyde.

Tissues were processed according to routine histological methods, embedded in paraplast and stained by H-E and Shorr-S3 stainings. An indirect immunoperoxidase (IPI) method was used to detect DV antigen, using as first antiserum a monoclonal antibody against the nucleocapsid protein (10).

Samples of renal pelvis epithelium – fixed in glutaraldehyde – were processed according to routine methods for transmission electron microscopy.

Table 1: Comparative results IB/IPI

Results	1	2	3	4	5	6	7	8
Respir. IB	+	+	+	+	-	-	+	-
system IPI	+	+	+	+	+	+	+	+
Lymph IB	+	0	0	0	0	0	0	-
organs IPI	+	0	0	0	0	0	0	+
Urinary IB	-	+	+	-	-	-	-	-
system IPI	-	+	+	-	+	+	+	+

IB inclusion bodies  
 IPI indirect immuno-peroxidase  
 + positive; - negative; 0 no samples

*Histopathological lesions.* The most frequent lesion observed was interstitial pneumonia with dilatation of the interstitium due to infiltration of mononuclear cells. Trachea and bronchi presented intracy-

toplasmic and intranuclear inclusion bodies. Lymphatic organs were characterized by necrosis and by the appearance of eosinophilic intracytoplasmic and intranuclear inclusions. Moderate to severe congestion was shown in the urinary bladder. Intracytoplasmic and intranuclear inclusions were detected in the epithelium of the urinary bladder and renal pelvis. No other significant lesions were present in the kidney.

*Immunocytochemical results.* The positive cells to the IPI showed a cytoplasm with dark-brown granules, the nuclei were not involved. Peroxidase-positive material was found in alveolar cells, interstitial cells, macrophages, trachea epithelial cells (Fig. 1), trachea gland cells, bronchial and bronchiolar epithelial cells, lymphoid cells, macrophages of the lymphoid system and epithelial cells of the

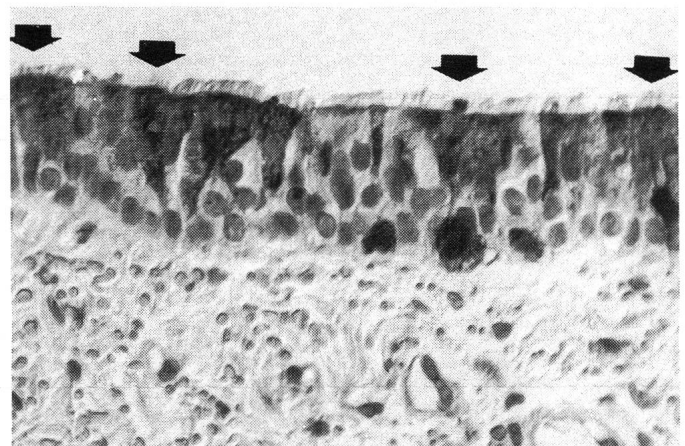


Fig. 1: Trachea. Cytoplasm peroxidase-positive material in the epithelial cells (arrows). IPI. X400

urinary bladder (Fig. 2) and renal pelvis. In one case positive material was found in glomerular mesangial cells.

Table 1 summarizes the histopathological and immunohistochemical findings. *Ultrastructural results.* Particles like DV were found in the cytoplasm of the epithelial cells of the renal pelvis.

**Discussion**

In this study distemper infection was diagnosed by evidence of inclusion bodies, immunoperoxidase techniques and electron-microscopic procedures.

Inclusion bodies (IB) were traditionally associated with distemper infection, but it was verified that occasionally IB were not identified