

# Immunomorphologic changes in golden hamsters caused by yersinia pestis ev

Autor(en): **Vesselinova, A. / Veljanov, D. / Nikolova, S.**

Objekttyp: **Article**

Zeitschrift: **Schweizer Archiv für Tierheilkunde SAT : die Fachzeitschrift für Tierärztinnen und Tierärzte = Archives Suisses de Médecine Vétérinaire ASMV : la revue professionnelle des vétérinaires**

Band (Jahr): **132 (1990)**

Heft 8

PDF erstellt am: **11.09.2024**

Persistenter Link: <https://doi.org/10.5169/seals-593713>

## **Nutzungsbedingungen**

Die ETH-Bibliothek ist Anbieterin der digitalisierten Zeitschriften. Sie besitzt keine Urheberrechte an den Inhalten der Zeitschriften. Die Rechte liegen in der Regel bei den Herausgebern.

Die auf der Plattform e-periodica veröffentlichten Dokumente stehen für nicht-kommerzielle Zwecke in Lehre und Forschung sowie für die private Nutzung frei zur Verfügung. Einzelne Dateien oder Ausdrucke aus diesem Angebot können zusammen mit diesen Nutzungsbedingungen und den korrekten Herkunftsbezeichnungen weitergegeben werden.

Das Veröffentlichen von Bildern in Print- und Online-Publikationen ist nur mit vorheriger Genehmigung der Rechteinhaber erlaubt. Die systematische Speicherung von Teilen des elektronischen Angebots auf anderen Servern bedarf ebenfalls des schriftlichen Einverständnisses der Rechteinhaber.

## **Haftungsausschluss**

Alle Angaben erfolgen ohne Gewähr für Vollständigkeit oder Richtigkeit. Es wird keine Haftung übernommen für Schäden durch die Verwendung von Informationen aus diesem Online-Angebot oder durch das Fehlen von Informationen. Dies gilt auch für Inhalte Dritter, die über dieses Angebot zugänglich sind.

In the experimental animals, the autopsy lesions were inconspicuous. Icterus was present to a lesser or higher degree. No conjunctivitis was present. The histologic lesions in the livers were similar to those described in the field cases. In one animal that was euthanised at the onset of clinical signs, necrosis of hepatocytes was limited to the cells near Kiernan's triangle. In the other cases, hepatocyte necrosis was diffuse.

At the ultrastructural level, severe degenerative alterations were present. Low power magnification revealed a loss of structural integrity, with red blood cells scattered throughout, and hepatocytes rounded and in some instances even fragmented. Nuclei of hepatocytes mostly were pale, with large chromatin clumps and irregular indented outline. The nuclei of fragmented cells usually were dark staining. Endothelial lining of the capillaries was difficult to discern. In less damaged areas, focal thickening of endothelial cells with cytoplasmic accumulation of lysosomes was noted. At higher magnification the cytoplasm of the hepatocytes was seen to contain abundant annular membranous structures. These were thought to represent the fragmented endoplasmic reticulum. Some cells contained numerous lipid droplets. Multivesicular bodies also frequently were seen. On rare occasions, virus-like particles of approximately 25 nm in diameter were seen in a paracrystalline arrangement in the cytoplasm. 28 to 30 nm virus-like particles could also be observed in liver homogenates by immuno electron microscopy.

*Institute of Microbiology, Bulgarian Academy Sciences, Sofia*

### IMMUNOMORPHOLOGIC CHANGES IN GOLDEN HAMSTERS CAUSED BY YERSINIA PESTIS EV

*A. Vesselinova, D. Veljanov, S. Nikolova, H. Najdenski, K. Mladenov, M. Sumnaliev*

The literature does not offer descriptions of immunomorphologic changes in animals and people caused by *Y. pestis* EV. However, Veljanov et al. (17) have reproduced chronic, non-lethal infection in golden hamsters aerosol-infected with vaccinal, plague strains *Y. pestis* EV. That is why our investigation were aimed at studying the morphological changes in golden hamsters infected by aerosol with *Yersinia pestis* EV with a view to explaining some immunogenic properties of this strain of the species *Yersinia*.

#### Material and methods

The experiments were carried out on golden hamsters at the age of 75 days with an average liveweight of  $120 \pm 10$  at the beginning of the experiment. The test animals were aerosol infected with the bacterial strain *Yersinia pestis* EV-76 (Brubaker) tenfold passivated on white mice. The nutritive medium was sulfate agar with an additive of beef et yeast extract - 0,5%. The inhalation immunization was carried out in an aerosol chamber of flow-and-dynamic type, at V/Q ratio = 1:1.4, described in a previous work (13). The bacterial suspension of 24-hour culture was spread in the working space of the chamber at a concentration of  $5.0 \times 10^9$  microbial cells. The inhaled (Dinh) and efficient (Def) doses received by the test animals for 18 min. (exposure time), were as follows:

#### Discussion

From the results of this study it can be concluded that EBHS indeed is a separate disease entity of viral origin.

The lesions observed in the experimentally infected hares were similar to the field cases. Conjunctivitis was not reproduced. It is not clear whether this conjunctivitis is a symptom of the disease or merely an intercurrent phenomenon. The ultrastructural alterations in the hepatocytes suggest a primary disrupture of the endoplasmic reticulum. The presence of virus-like particles in these cells may indicate that the hepatocyte necrosis would be a direct effect of the virus replication. The endothelial lesions observed may contribute to the often rapid course of the disease. The virus-like particles observed in ultra-thin sections of the livers of experimentally infected hares were similar to those observed by Peeters in rabbits exposed to the haemorrhagic disease virus (Peeters, pers. commun.).

#### References

1. Eskens, U., Volmer, K. (1989): Dtsch. tierärztl. Wschr. 96, 433–472. — 2. Gavier, D. et al. (1988): Meeting «Diseases of hares and the European brown hare syndrome», Uppsala, Sweden, 27–30 October. — 3. Marcato, P. S. et al. (1989): Rivista di Coniglicoltura 8, 41–50.

Dinh =  $1.4 \times 10^6$  microbial cells Def =  $3.8 \times 10^6$  microbial cells. The efficient (real) dose is 27% of the inhaled one.

The immunomorphologic changes were examined in their dynamics. To this end, five test animals were killed at different time intervals (on the 1st, 3rd, 7th, 15th and 30th day) after immunization. The materials designed for histological examination (lungs, pulmonary lymph nodes, tonsils, spleen, mesenterial lymph nodes and liver) were fixed in Baker's liquid, and treated according to the rapid histological technique.

All histocuts were stained with hematoxylin-eosin.

#### Results and discussion

By examination of the manifestation and development of the morphologic changes (Fig. 1) in the lungs, pulmoranry lymph nodes, tonsils, spleen, mesenterial lymph nodes and liver, it has been found that the first changes occur on the 3rd day after the inhalation of *Y. pestis* EV; they come strongly expressed on the 7th up to the 15th day, and, then, these are gradually reduced, and after the 30th day they are a attenuated, and this substantiates the assumption that the macroorganism has acquired immunity.

On the 3rd day after inhalation of *Y. pestis* EV in the lungs, the bronchi and alveoli are filled with serous cell exudate. On the 7th day small accumulations of leukocytes are found in the inflamed pulmonary tissue, that gradually increase, and towards the 15th day

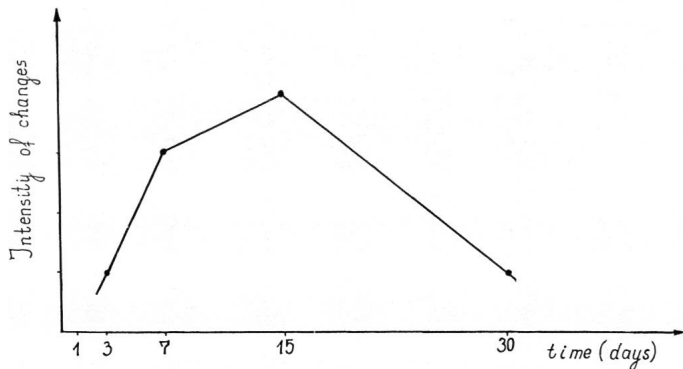


Fig. 1: Dynamics of morphologic changes in Golden Hamsters caused by *Yersinia pestis* EV aerosol infection.

a well-expressed catarrhal-suppurative pneumonia is present (Fig. 2), while misliary necrotic foci are also found in individual sectors. On the 30th day the pneumonic changes show a trend to reduction and restriction. The changes found in the lungs of golden hamsters aerosol infected with *Y. pestis* EV are similar to the pneumonic changes described in small laboratory animals and sheep (6, 8, 11, 12) caused by other strains (*Y. pseudotuberculosis* and *Y. enterocolitica*) of the species *Yersinia*. On the 7th day after inhalation of *Y. pestis* EV catarrhal lymphadenitis is found in the pulmonary lymph nodes. In the lymphoreticular system of the lymph nodes (Fig. 3), tonsils (Fig. 4) and spleen single macrophages, a great number of histiocytes and plasma cells are found which are assumed as being an expression of increased immunobiological state of the macroorganism, an immunomorphologic manifestation of immunogenesis (1, 3, 4, 7). However, most strongly expressed macro- and microphageal reaction is found in the immunocompetent organs on the 7th up to the 15th day after application of *Y. pestis* EV. As far as the role of the macrophages in the process of immunogenesis is concerned, some authors (2, 4, 5, 10, 15, 16) point out that the macrophages have an important function in realizing the immune response in the organism of the vertebrates, although these do not directly participate in the formation of antibodies.

The plasma cells found in the lymph nodes, tonsils and spleen are considered by some immunologists (3, 4, 9) as being highly organized cells capable of quickly absorbing and removing the corpuscular material. These are accumulated in the immunocompetent organs of the macroorganism in case of antigenic irritation, producing highly specific antibodies (9, 14), and participating in the control of the humoral immune response. According to Ahlgvist et al. (1), the accumulation of pyroninophilic cells in the mesenteric lymph nodes in case of *Y. enterocolitica* infection is connected with an early production of specific antibodies.

The changes occurring in the liver are manifested by activation of the cells of the reticuloendothelial system.

On the basis of the morphologic investigations carried out so far, it may be assumed that the macrophageal reaction and the great number of plasma cells in lymph nodes, tonsils and spleen of golden hamsters aerosol-immunized with *Yersinia pestis* EV, are an immunomorphologic manifestation of the immunogenesis.

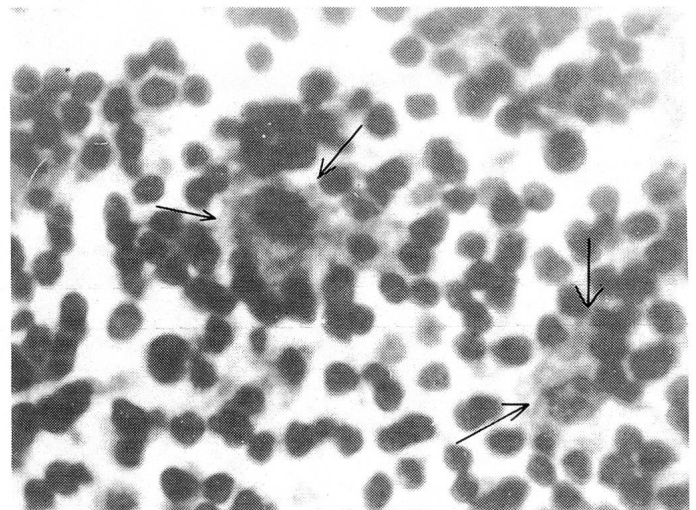


Fig. 3: Lymph node of a golden hamster, macrophages H. E. X630.

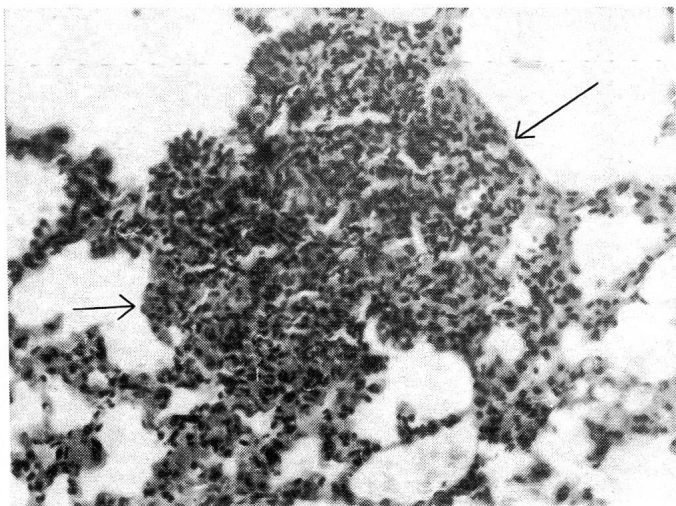


Fig. 2: Lungs of a golden hamster, pneumonic focus H. E. X125.

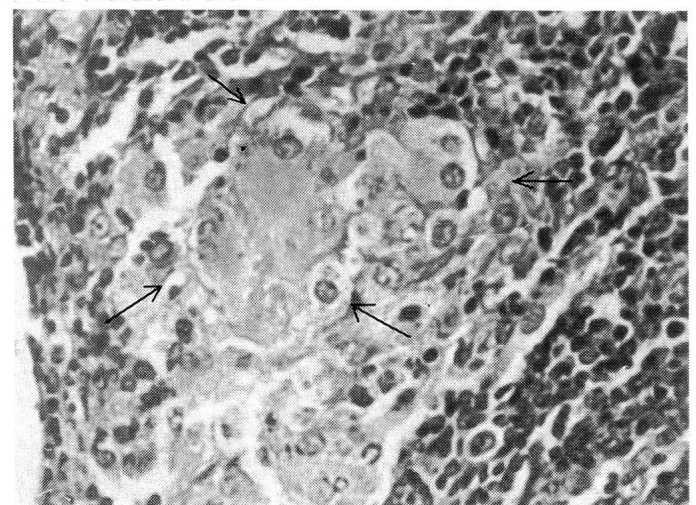

Fig. 4: Tonsil of a golden hamster, macrophages and plasma cells (→) H. E. X250.

## References

1. Ahlgvist, J. et al.: Acta path. microbiol. scand., 79, 109–122. — 2. Beeson, P. P. (1977), Immunology of the gut. Amsterdam. — 3. Boyd, W. C. (1966) Fundamentals of immunology, New-York-London-Sydney. — 4. Burnet, Mac-Farlain (1969): Cellular immunology, Melbourne university press, Cambridge university press. — 5. Carr, I. (1973), The Macrophage, New-York, Academic Press. — 6. Carter, Ph. B. (1975), Infect. Immun., 11, 164–170. — 7. Cood, R. (1983), Progress in Immunology V, Acad. Press Japan, 1607–1615. — 8. Jarret, I., U. Slee (1989), Vet. Pathol., 26, 180–183. —

9. Litt, M. (1964), Ann. N. Y. Acad. Sci, 116, 964. — 10. Lohmann-Matthes, M. et al. (1982); Immunobiol., 161, 401–407. — 11. Pearson, A. D., et al., Contr. Microbiol. Immunol., 5, 335–345. — 12. Pueyo, J. M. et al. (1987), 68, 259–261. — 13. Sumnaliev, M. et al. (1969), II Congress of Microbiology, Sofia, 1, 237–240. — 14. Toshkov, As., D. Denchev (1987). Immune system, C/o Jus autor, Sofia. — 15. Uchtiel, U. Y. (1978), Macrophages in Immunity, Moscau. — 16. Velev, G., D. Todorov (1981), Immunomorphology, C/o Jus autor, Sofia. — 17. Veljanov, D. et al. (1990), Bacteriological characteristic of aerosol infection with *Y. pestis* EV among golden hamsters (unpublished data).

Institut für Veterinärpathologie, Universität Zürich,

## IN SITU HYBRIDIZATION: A METHOD TO CONFIRM THE ETIOLOGICAL DIAGNOSIS OF PARVOVIRUS ENTERITIS IN DOGS AND CATS?

A. S. Waldvogel, S. Hassam, R. Weilenmann, J-D. Tratschin, G. Siegl, J. Briner, A. Pospischil

In situ hybridization was used to localize parvovirus in section from formalin fixed, paraffin embedded intestinal and lymphoid tissue from dogs with atrophic enteritis and cats with feline panleukopenia. The probe consisted of the pBR322 plasmid containing the entire VP1- and VP2-coding sequences of canine parvovirus. It was labeled by nicktranslation with biotinylated dUTP.

For the in situ hybridization the section was deparaffinized, endogenous peroxidase was inactivated by incubating with  $H_2O_2$  and the tissue was digested by proteinase K. The probe was denatured on the slide at 98°C for 10 minutes and hybridization was performed over night at 42°C. The hybridization product was localized by incubating the slide with an avidin-biotinylated horseradish peroxidase complex

and the peroxidase activity was detected by amino-ethyl-carbazol and  $H_2O_2$  as substrates.

The morphologic diagnosis of an atrophic enteritis correlated well with the presence of parvovirus in dogs. However, parvovirus could only be detected in 5 out of 9 cats with marked atrophic enteropathy. In this study we were able to confirm the etiologic diagnosis in several cases, but could not rule out a parvovirus infection, where the in situ hybridization yielded negative results. Whether this discrepancy between morphologic findings and results of the in situ hybridization reflected a) a lack of sensitivity or b) some cats had already eliminated the virus by the time of necropsy or c) the atrophic enteritis was caused by another agent, such as FeLV, still needed to be investigated.

Institute of Veterinary Pathology, University of Zurich, Switzerland

## PATHOLOGY OF SWINE – A PORTRAIT OF ECONOMIC LOSS IN PIG PRODUCTION IN SWITZERLAND

P. Wegmann

Economic loss in pig production due to runtting or premature death is one of the most important economic factors in Swiss agriculture. In 1971 the costs were estimated at about SFr. 100 million. Half of this loss was due to the spontaneous death of younger pigs, the other half was due to bad feed conversion caused primarily by lung affections or unfavourable husbandry conditions. In 1988, 1447 pigs were necropsied at our institute. A statistic evaluation of the findings is presented with an attempt to show a relationship between the diagnoses and the economic losses in Switzerland.

### Necropsy results

75% of the pigs were younger than 2 months. An explanation for this age distribution is that deaths caused by infectious diseases predominate in pigs of this age and farmers thus show more concern for the aetiology. Runtting is infrequent.

Intestinal infections with *E. coli* were of greatest importance. One peak occurs in the first two weeks after birth and is caused by *E. coli*

strain O 149. The next peak is found in the second month after birth, i. e. after weaning. Here, the strains O 139 and O 141 dominate. In the next three months, intestinal infections with *E. coli* decrease and occur only after moving animals and the assembly of new groups.

The second major cause of death in younger pigs is septicemia. In the first month more than 60% are infections with *E. coli*, *Streptococcus* and *Erysipelothrix*. In the following months, *Haemophilus parasuis* (Glässer's Disease) often occurs. Affections of joints, skin or other diseases are relatively seldom, namely in only 13% of all the pigs under 2 months.

In the animals over 2 months, the respiratory tract was primarily affected; predominantly infections with *Mycoplasma hyopneumoniae*, *Pasteurella multocida*, *Actinobacillus pleuropneumoniae* and *Bordetella bronchiseptica*. The maximum incidence was in the 7 month-old pigs, where 100% had pneumonic infections. Respiratory diseases in SPF-pigs were rare.

Pigs with respiratory problems usually only tended to runt.