

Zeitschrift: Schweizer Archiv für Tierheilkunde SAT : die Fachzeitschrift für Tierärztinnen und Tierärzte = Archives Suisses de Médecine Vétérinaire ASMV : la revue professionnelle des vétérinaires

Band: 138 (1996)

Heft: 4

Artikel: Efficacy of maduramicin against turkey coccidiosis in battery : a clinical and pathological study

Autor: Cerruti Sola, S. / Leoni, A. / Agostini, A.

DOI: <https://doi.org/10.5169/seals-591041>

Nutzungsbedingungen

Die ETH-Bibliothek ist die Anbieterin der digitalisierten Zeitschriften. Sie besitzt keine Urheberrechte an den Zeitschriften und ist nicht verantwortlich für deren Inhalte. Die Rechte liegen in der Regel bei den Herausgebern beziehungsweise den externen Rechteinhabern. [Siehe Rechtliche Hinweise.](#)

Conditions d'utilisation

L'ETH Library est le fournisseur des revues numérisées. Elle ne détient aucun droit d'auteur sur les revues et n'est pas responsable de leur contenu. En règle générale, les droits sont détenus par les éditeurs ou les détenteurs de droits externes. [Voir Informations légales.](#)

Terms of use

The ETH Library is the provider of the digitised journals. It does not own any copyrights to the journals and is not responsible for their content. The rights usually lie with the publishers or the external rights holders. [See Legal notice.](#)

Download PDF: 17.11.2024

ETH-Bibliothek Zürich, E-Periodica, <https://www.e-periodica.ch>

Dipartimento di Patologia Animale, Università degli Studi di Torino¹, Istituto di Patologia Generale ed Anatomia Patologica Veterinaria, Facoltà di Medicina Veterinaria, Università degli Studi di Sassari², Cyanamid Italia S.p.A., Roma³

Efficacy of maduramicin against turkey coccidiosis in battery: a clinical and pathological study

S. Cerruti Sola¹, A. Leoni², A. Agostini³, M. Castagnaro³

Summary

Two groups of 24 three-day-old turkeys each were inoculated with *Eimeria meleagrimittis* sporulated oocysts and fed a diet containing respectively 5 and 6 ppm of maduramicin ammonium. Clinical signs, mortality rates, weight gain, intestinal lesions and replication of the parasite were compared to the data obtained from a group of infected, untreated birds kept in the same experimental conditions over a period of 17 days. The treated birds showed better performances and less severe intestinal damages; the replication and the development of the parasite in the intestinal mucosa were impaired and delayed by the drug. All the data were dose dependent.

Key words: coccidiosis – turkeys – maduramicin

Wirksamkeit von Maduramicin gegen Trutenkokzidiose in Batteriehaltung: eine klinische und pathologische Studie

Zwei Gruppen von je 24 drei Tage alten Trutenküken wurden mit sporulierte Oozysten von *Eimeria meleagrimittis* infiziert. Das Futter enthielt 5 oder 6 ppm Maduramicin-Ammonium. Klinische Symptome, Mortalität, Gewichtszunahme, Läsionen des Darms und Vermehrung der Parasiten wurden mit den Daten einer Gruppe von infizierten, unbehandelten Tieren, die unter denselben experimentellen Bedingungen 17 Tage lang gehalten wurden, verglichen. Die behandelten Truten zeigten eine bessere Leistung und litten unter weniger starker Enteritis; Replikation und Entwicklung der Parasiten in der Darmschleimhaut waren auf Grund der Arzneimittelwirkung reduziert und verzögert. Alle Werte waren von der Dosierung abhängig.

Schlüsselwörter: Kokzidiose – Truten – Maduramicin

Introduction

Cygro® (maduramicin ammonium, American Cyanamid Company), a monoglycoside polyether ionophore antibiotic produced by *Actinomadura yumaensis*, has been extensively tested for anticoccidial activity in poultry (Folz et al., 1988; Kantor and Schenkel, 1984; Kantor et al., 1984, 1986; McDougald et al., 1987) and a maduramicin dietary concentration of 5 ppm has been shown to

be effective against all economically relevant species of coccidia in turkeys (Cringoli et al., 1988).

The purpose of this study was to evaluate the efficacy of maduramicin in the diet for the prevention of turkey coccidiosis caused by field isolates under laboratory conditions and to investigate its effects on the development of the parasites and of the associated intestinal lesions.

Animals, materials and methods

Animals and experimental infection

Ninety six 3-day-old broad breasted male turkeys were divided into four groups of 24 birds each; each group was allocated in separate cages, kept at a controlled temperature of 38 °C and identified respectively as Group 1, 2, 3 and 4. The birds of Group 1 were maintained as controls and were uninoculated and uninfected, while the turkeys of Groups 2, 3 and 4 were inoculated by crop intubation with 1 ml of an aqueous suspension containing 7×10^4 /ml of *Eimeria meleagridis* sporulated oocysts derived from a field isolate.

Nutrition

All of the birds were supplied with feed and water ad libitum. Throughout the entire experimental period Groups 1 and 2 received standard feed formulation for turkeys (metabolic energy = 3,000 kcal/kg), while Groups 3 and 4 were given the same diet plus Cygro® in proportions of 5 and 6 ppm respectively. Therefore the final experimental plan was as follows: Group 1 = uninfected, control; Group 2 = infected, control; Group 3 = infected, medicated (Cygro®, 5 ppm); Group 4 = infected, medicated (Cygro®, 6 ppm).

Clinical symptoms, body weight, and mortality

A clinical evaluation was performed on the birds every day. Mortality was recorded and fresh faecal material was microscopically examined using a McMaster's chamber, in order to estimate the oocyst production. At 11 days of age, corresponding to the 8th day of the experiment, 5 turkeys from each group were randomly selected and weighed; the weight was calculated as average and standard deviation.

Postmortem examination

At the moment of the experimental infection (0 hours post infection = PI), one turkey from each group was weighed and necropsied. From day 1 to day 7 PI two turkeys from each group chosen at random were killed and necropsied as above at 36 hours intervals (24, 60, 96, 132, 168 hours PI); two more birds from each group were sacrificed respectively on the 9th and 17th day of the experiment (216 and 408 hours PI). The intestinal lesions due to coccidiosis were scored numerically as follows: 0 = no lesion; 1 = excessive mucus in the intestine; 2 = duodenum enlarged, vessels congested; 3 = duodenal necrotic core extended into the upper small intestine; 4 = necrotic core, petechial haemorrhages in the mucosa of the small intestine. The results of the scoring were calculated as average values. The turkeys which died

spontaneously were necropsied in order to determine whether the cause of death was due to coccidiosis. The small intestine was removed from each sacrificed bird, fixed in 10% buffered formalin, processed by standard paraffin techniques and the sections stained with haematoxylin and eosin (HE), Periodic Acid Schiff (PAS), Goodpasture and Ritter-Oleson staining methods. For ultrastructural studies, representative portions of duodenal tissue obtained from sacrificed birds were cut into 1–2 mm blocks and fixed in 2.5% glutaraldehyde, buffered with 0.2 M sodium cacodylate (pH 7.4). They were post-fixed in 0.1 M 1% osmium tetroxide in sodium cacodylate buffer for two hours at 20 °C and dehydrated in a series of graded ethanols. The specimens were then stained *en bloc* with a 3% solution of uranyl acetate in absolute alcohol and embedded in a mixture of Epon-812/Araldite. Thick sections (1 µm) were stained with toluidine blue. Thin sections were cut on a Reichert-Jung Ultracut E (Reichert Jung, Wien, Austria), stained with uranyl acetate and lead citrate, and observed with a Zeiss EM 109 with trans-fiber-optic photography (Carl Zeiss, Oberkochen, Germany).

Results

Clinical signs, growth, and mortality rates

Throughout the entire experiment the turkeys of Groups 1 and 4 did not show any clinical signs. Their water and feed intakes were regular and within normal limits, although Group 4 birds showed a visible inferior growth rate than Group 1. Ninety six hours PI the turkeys of Groups 2 and 3 started producing an aqueous diarrhoea that caused an accumulation of faeces around the cloaca which induced cannibalism within the groups. For the next three days the turkeys of Group 2 showed evidence of scours and depression, character-

Table 1: Live weight of turkeys at 11 days of age (Data expressed as mean ± standard deviation; five turkeys from each group were weighed)

Groups	Live weight (g)
1 (uninfected control)	235.6 ± 10.7
2 (infected control)	171.2 ± 19.9
3 (Cygro, 5 ppm)	183.8 ± 16.8
4 (Cygro, 6 ppm)	196.6 ± 20.8

Table 2: Oocyst production (Data expressed as oocysts/g faeces × 10³, 24 birds per group)

Groups	Hours postinfection					
	120	144	168	192	216	408
1 (uninf. control)	0	0	0	0	0	0
2 (inf. control)	0	12.6	13.4	24.1	26.1	0
3 (Cygro, 5 ppm)	0	0.2	1.2	4.5	6.0	0
4 (Cygro, 6 ppm)	0	0	0.8	3.7	5.3	0

Table 3: Mortality rates (Data expressed as percentage, 24 birds per group)

Groups	Hours postinfection								
	24	48	72	96	120	144	168	192	216
1	0	0	0	0	0	0	0	0	0
2	4.3	0	5.0	21.4	15.8	9.1	0	12.5	14.3
3	8.7	0	0	5.3	6.2	0	0	0	0
4	0	0	4.8	0	0	5.5	0	0	0

ized by ruffled feathers, listlessness, dehydration, low feed intake and poor growth. These symptoms were less severe and more transient in Group 3 birds. Although Group 3 birds had a feed intake comparable to Groups 1 and 4, their weight gain was inferior. The body weight increase recorded at 11 days of age is shown in Table 1. In Table 2 the oocyst counts are reported. The mortality rates are shown in Table 3.

Gross pathology, histopathology, and ultrastructure

Table 4 shows the average scores of the gross intestinal lesions recorded at necropsy. As early as 24 hours PI severe hyperaemia, haemorrhages and necrosis were observed in the intestine of Group 2 turkeys. A profound destruction of the epithelial cells was evident both on the surface of the villi and in the crypts (Fig. 1). An inflammatory reaction, characterized by heterophils and round cells infiltration, occurred in the axis of the villi, in the intestinal lumen and in the lamina propria. Morphologically normal trophozoites were found in the gland epithelial cells. During the following 72 hours the severity of the necrotic and inflammatory lesions decreased progressively, so that at 96 hours PI the necrosis was evident only in the axis of the villi and the inflammatory cells here located consisted mostly of eosinophilic granulocytes. The presence of a large number of morphologically normal second and third generation schizonts was noticed in the glands respectively at 60 and 96 hours PI. At 132 hours PI an intensive mitotic activity took place in the crypt epithelial cells and the number of goblet cells started increasing. Gamonts and oocysts were found in the villi and they became even more numerous at 168 hours PI (Fig. 2), when an intensive regeneration of the epithelial layer occurred. At the same time the bloodvessels of the axis of the villi appeared to be enlarged and an eosinophilic inflammatory reaction was present. During the next 48 hours (216 hours PI) the histopathological picture did not change substantially

Table 4: Intestinal lesion scores (Data expressed as average; two turkeys from each group were scored for lesions)

Groups	Hours postinfection						
	24	60	96	132	168	216	408
1	0	0	0	0	0	0	0
2	2.5	3.5	3.0	2.5	2.0	0	0
3	1.5	2.0	2.5	2.0	1.5	0	0
4	0	0	1.0	2.0	1.5	0	0

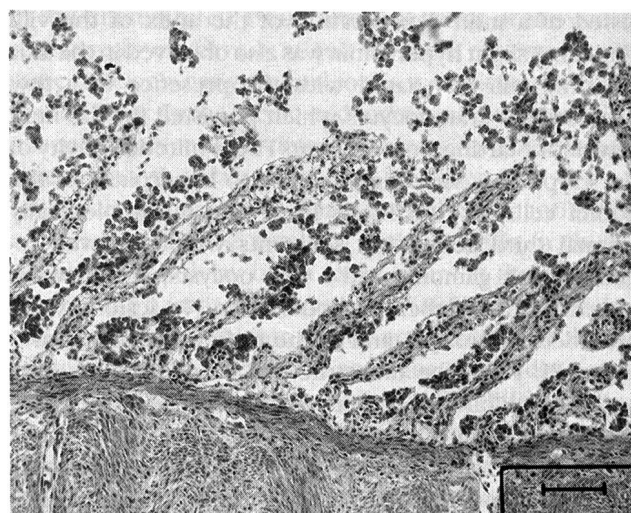


Figure 1: Microphotograph; small intestine; infected, unmedicated turkey (Group 2), 24 h PI; H.E. - Extensive necrosis and detachment of epithelial cell layers associated with inflammatory infiltration of the villi axis. Bar = 100 µm.

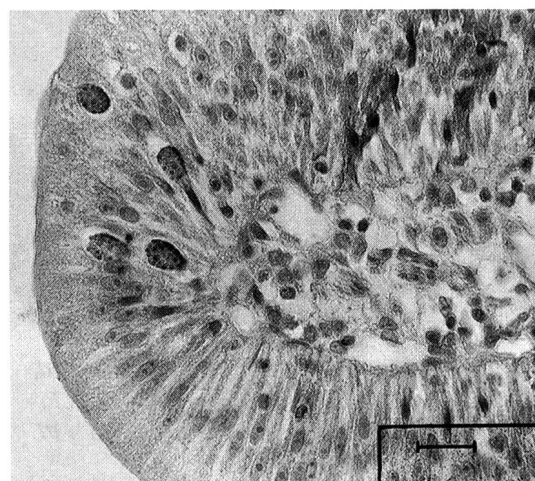


Figure 2: Microphotograph; small intestine; infected, unmedicated turkey (Group 2), 168 h PI; H.E. - A normal macrogamont and some oocysts are present inside the epithelial cells. Bar = 25 µm.

and oocysts were mostly found. At 408 hours PI no parasites were observed, no inflammatory lesions were left and the epithelial regeneration was complete. The histopathological picture of Group 3 was substantially the same as Group 2 although the lesions were less severe. The epithelial necrosis was less extensive and the inflammation more transient; no trophozoites were found at 24 hours PI. At 168 hours PI the regeneration of the epithelium was complete and many morphologically normal gamonts were observed, whereas the formation of the oocysts was delayed compared to Group 2 (Fig. 3). A large number of oocysts was found 216 hours PI, together with many gamonts and an intensive crypt hyperplasia. In Group 4 the early lesions (24 hours PI) con-

sisted of a mild degeneration of the apex of the villi (Fig. 4). A slight hyperaemia was also observed in the axis of some villi associated with the presence of a few eosinophilic granulocytes which persisted for the next few days. Starting from 96 hours PI the mitotic activity of the crypts was very high, leading to hyperplasia of the goblet cells. At 168 hours PI several morphologically normal third generation schizonts were observed together with gamonts and a few oocysts, which were increased in number 72 hours later. No lesions were recorded in Group 1 and in the turkeys sacrificed at 0 hours PI. From the ultrastructural point of view, only second and third generation schizonts were observed in inoculated, medicated birds (Groups 3 and 4), whereas sporozoites, trophozoites and first generation schizonts were not found. The growth and differentiation stages of schizonts (Fig. 5) and the subsequent development of

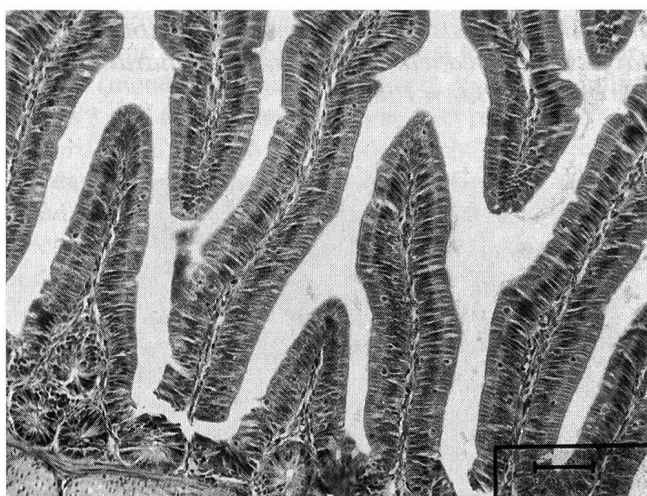


Figure 3: Microphotograph; small intestine; infected, medicated (5 ppm) turkey (Group 3), 168 h PI; H.E. - Only normal macrogamonts are present at 168 h PI. Bar = 25 μ m.

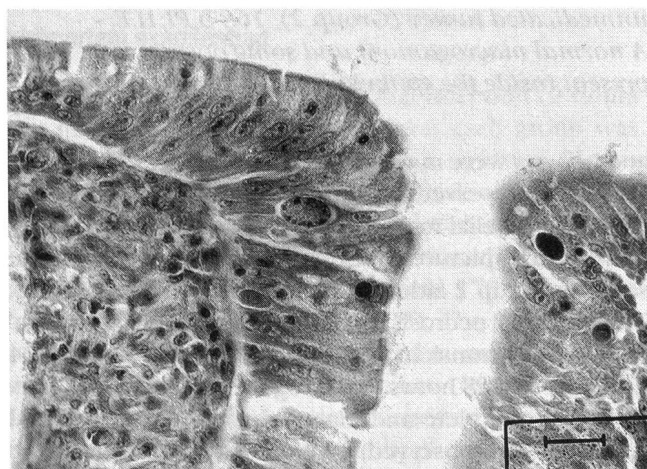


Figure 4: Microphotograph; small intestine; infected medicated (6 ppm) turkey (Group 4), 24 h PI; H.E. - Mild degeneration of apical epithelial cells. Bar = 100 μ m.

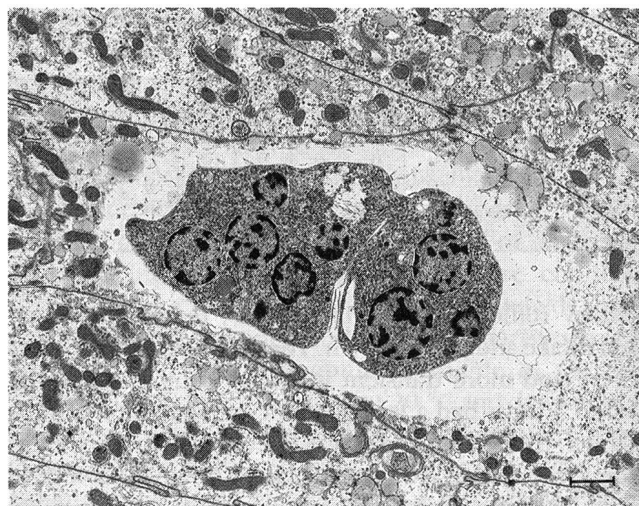


Figure 5: Electron micrograph; small intestine; infected, medicated (5 ppm) turkey (Group 3), 132 h PI. A normal second-generation schizont in late stage of development. Bar = 4.54 μ m.

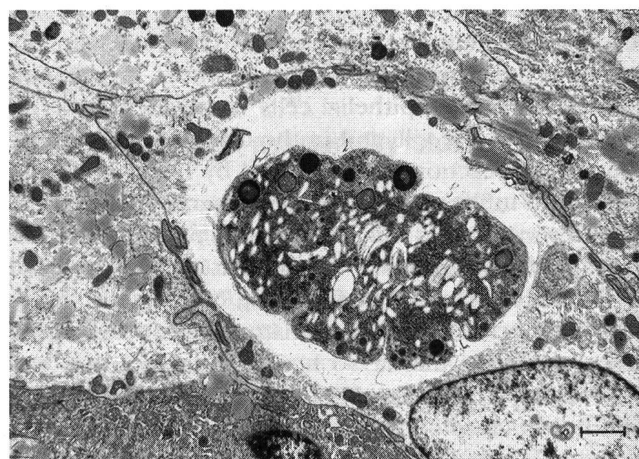

Figure 6: Electron micrograph; small intestine; infected, medicated (6 ppm) turkey (Group 4), 216 h PI. Normal developing macrogamonts. Bar = 6.66 μ m.

gamonts (Fig.6) were not morphologically affected in Groups 3 and 4, although their number was sensibly decreased compared to the inoculated unmedicated birds (Group 2).

Discussion

In the present study we show that maduramicin had significant anticoccidial activity against *Eimeria meleagridis* under laboratory conditions.

The efficacy of the treatment appears to be directly related to the dose of the drug used. It is noteworthy the turkeys receiving the higher dose of medication (6 ppm) did not show any signs of toxicity. Since the diarrhoea observed in Groups 2 and 3 birds was not present in

Group 4, this phenomenon was likely to be induced by the parasites and not by the treatment.

The weight gain was greater in the infected and medicated birds than in the infected and unmedicated ones, although even the former turkeys never reached the size of the uninoculated birds. On the other hand, the growth depression recorded in the treated turkeys, being more substantial in the group fed the lower dose, was not due to the action of the drug, but of the parasite itself.

The mortality rates were inversely related to the doses of drug used, being the highest in untreated inoculated turkeys. The mortality observed as early as 24, 48, and 72 hours PI was due to the extremely high dose of the inoculum. In fact, as confirmed by the histopathological observations, there was a severe destruction of the intestinal epithelium already at 24 hours PI. This damage was caused by the dramatic large number of trophozoites released from the inoculated oocysts.

The pathological findings here reported show that the severity of the lesions is inversely related to the dose of the drug even at an early stage of the infection (24 hours PI). As already reported for other ionophore antibiotics (Chappel, 1979), the site of action is probably represented by the sporozoite stage. This assumption is supported by the failure in detecting early forms of the protozoa in treated animals and by the observation of mild early histological lesions in the same groups. The destruction of the early stages of the parasite results in a weaker invasive potential and in a less severe damage of the intestinal epithelium. The subsequent maturation of the few sporozoites escaping the action of the drug is somehow affected by the treatment, in terms of a delay in the formation of schizonts, gamonts and oocysts. In fact,

in the unmedicated group terminal forms of the protozoa were found already at 168 hours PI, whereas at the same time only early asexual forms were detected in the treated birds. In the medicated turkeys oocysts were first observed only at a later time (216 hours PI). These results agree with the data produced by Ryley and Wilson (1975) about the action of another polyether antibiotic, monensin, against *E. brunetti* and *E. tenella* in chicks, which show a delay of up to 24 hours in the development of the parasite. Verheyen et al. (1989) reported that diclazuril, a recently introduced anticoccidial molecule belonging to the nucleoside analogue group, did not affect morphologically the growth and the differentiation stages of *Eimeria maxima* and *E. brunetti* in chickens; accordingly, in our study the morphology of the schizonts and of the sexual forms of *E. meleagridis* in turkey seemed not to be affected by the treatment.

The pathological observations are strongly consistent with the oocyst counts, which show a longer prepatent period and a decreased oocyst excretion in the medicated turkeys.

References

- Chappel L.R. (1979): The site of action of the anticoccidial salinomycin (Coxistac). *J. Parasitol.* 65, 137-143.
- Cringoli G., Fioretti A., Menna L.F., Rossi M., Di Meo C. (1988): Ricerche sull'efficacia del Cygro (maduramicina ammonio) come anticoccidico in un gruppo di tacchini infettati sperimentalmente. *Parassitologia.* 30, 60-61.
- Folz S.D., Lee B.L., Nowakowsky L.H., Conder G.A. (1988): Anticoccidial evaluation of halofuginone, lasalocid, maduramicin, monensin and salinomycin. *Vet. Parasitol.* 28, 1-9.

Efficacité de la maduramicine contre la coccidiose des dindons d'élevage intensif en cage: étude clinique et pathologique

Des oocystes sporulés d'*Eimeria meleagridis* ont été inoculés à deux groupes de 24 dindons âgés de trois jours. La nourriture contenait 5 et 6 ppm d'ammonium de maduramicine. Les symptômes cliniques, le pourcentage de mortalité, l'accroissement du poids, les lésions intestinales et la reproduction du parasite ont été comparés aux valeurs obtenues chez un groupe témoin de dindons infectés et maintenus dans les mêmes conditions expérimentales pendant une période de 17 jours. Les dindons traités ont montré des meilleures performances et moins de dommages intestinaux que les dindons témoins. La reproduction et le développement du parasite dans la muqueuse intestinale étaient réduits et retardés par le médicament. Tous les résultats étaient dépendants de la dose.

Efficacia della maduramicina nella coccidiosi dei tacchini allevati in batteria: studio clinico e patologico

Due gruppi di 24 tacchini di 3 giorni di età sono stati inoculati con oocisti sporulate di *Eimeria meleagridis* e nutriti con una dieta contenente rispettivamente 5 e 6 ppm di ammonio maduramicina. I sintomi clinici, la percentuale della mortalità, l'incremento ponderale, le lesioni intestinali e la riproduzione del parassita sono stati comparati con i dati ottenuti da un gruppo di tacchini infetti, non trattati, mantenuti nelle stesse condizioni sperimentali per un periodo di 17 giorni. I tacchini trattati hanno dimostrato migliori risultati e danni intestinali meno gravi; la riproduzione e lo sviluppo del parassita nella mucosa intestinale erano diminuite e ritardate dal farmaco. Tutti i dati erano dose-dipendenti.

Kantor S., Schenkel R.H. (1984): CL 259,971: A potent new polyether anticoccidial. 1. Battery efficacy and safety. Poultry Sci. 63, 1497-1504.

Kantor S., Schenkel R.H., Kennet R.L. Jr (1984): CL 259,971: A potent new polyether anticoccidial. 2. Floor pen trials. Poultry Sci. 63, 1505-1511. 1984.

Kantor S., Quarles C., McDougald L.R., Wang G.T. (1986): Efficacy of maduramicin against ionophore-tolerant field isolates of *Coccidia* in broilers. Avian Dis. 31: 302-312. 1986.

McDougald, L.R., Da Silva J.M.L., Solis J., Braga M. (1987): A survey of sensitivity to anticoccidial drugs in 60 isolates of *Coccidia* from broiler chickens in Brazil and Argentina. Avian Dis. 31, 287-292.

Ryley, J.F., Wilson R.G. (1975): Laboratory studies with some recent anticoccidials. Parasitology. 70, 203-222. 1975.

Vlaminckx E., Marsboom R. (1989): Ultrastructural evaluation of the effects of diclazuril on the endogenous stages of *Eimeria maxima* and *Eimeria brunetti* in experimentally inoculated chickens. Parasitol. Res. 75, 604-610.

Address of the authors: Mrs. Dr. S. Cerruti Sola, Dipartimento di Patologia Animale, Università degli Studi di Torino, Via Nizza 52, I-10126 Nizza

Manuskripteingang: 24. Januar 1994

DIANA.
Computersoftware für Gross- und Kleintierpraxen

brunner & hess software ag
PC-Lösungen aus Entwicklerhand
Schulhausstrasse 73 Tel. 01/286 20 30
CH-8002 Zürich Fax 01/286 20 31
DIANA-Direktnummer Tel. 01/286 20 40