

# Invasive potential and actual invasion : an essay on tumor progression

Autor(en): **Stäuli, Peter**

Objektyp: **Article**

Zeitschrift: **Jahrbuch der Schweizerischen Naturforschenden Gesellschaft. Wissenschaftlicher und administrativer Teil = Annuaire de la Société Helvétique des Sciences Naturelles. Partie scientifique et administrative**

Band (Jahr): **162 (1982)**

PDF erstellt am: **17.07.2024**

Persistenter Link: <https://doi.org/10.5169/seals-90892>

## **Nutzungsbedingungen**

Die ETH-Bibliothek ist Anbieterin der digitalisierten Zeitschriften. Sie besitzt keine Urheberrechte an den Inhalten der Zeitschriften. Die Rechte liegen in der Regel bei den Herausgebern.

Die auf der Plattform e-periodica veröffentlichten Dokumente stehen für nicht-kommerzielle Zwecke in Lehre und Forschung sowie für die private Nutzung frei zur Verfügung. Einzelne Dateien oder Ausdrucke aus diesem Angebot können zusammen mit diesen Nutzungsbedingungen und den korrekten Herkunftsbezeichnungen weitergegeben werden.

Das Veröffentlichen von Bildern in Print- und Online-Publikationen ist nur mit vorheriger Genehmigung der Rechteinhaber erlaubt. Die systematische Speicherung von Teilen des elektronischen Angebots auf anderen Servern bedarf ebenfalls des schriftlichen Einverständnisses der Rechteinhaber.

## **Haftungsausschluss**

Alle Angaben erfolgen ohne Gewähr für Vollständigkeit oder Richtigkeit. Es wird keine Haftung übernommen für Schäden durch die Verwendung von Informationen aus diesem Online-Angebot oder durch das Fehlen von Informationen. Dies gilt auch für Inhalte Dritter, die über dieses Angebot zugänglich sind.

# Invasive potential and actual invasion: An essay on tumor progression

Peter Sträuli

## 1. Invasion as a criterion of malignancy

Tumors have various means to endanger and eventually to kill their hosts. Growth of a neoplastic cell population, even if it is strictly expansive and does not encroach on neighboring normal structures, is perilous in an organ with a limited range of adaptation to increasing pressure, e.g. in the brain. Furthermore, tumors producing excessive amounts of hormones or similar agents can imperil the host irrespective of their growth behavior. Within the vast spectrum of death by neoplasia, however, these are relatively rare instances compared to the effects of invasion and their eventual sequel, metastasis. Invasion or local spread is therefore the chief characteristic of malignancy, and as long as morphology is responsible for the definitive diagnosis of cancer, the search for invasion in histological preparations remains irreplaceable.

## 2. Principal mechanisms of invasion

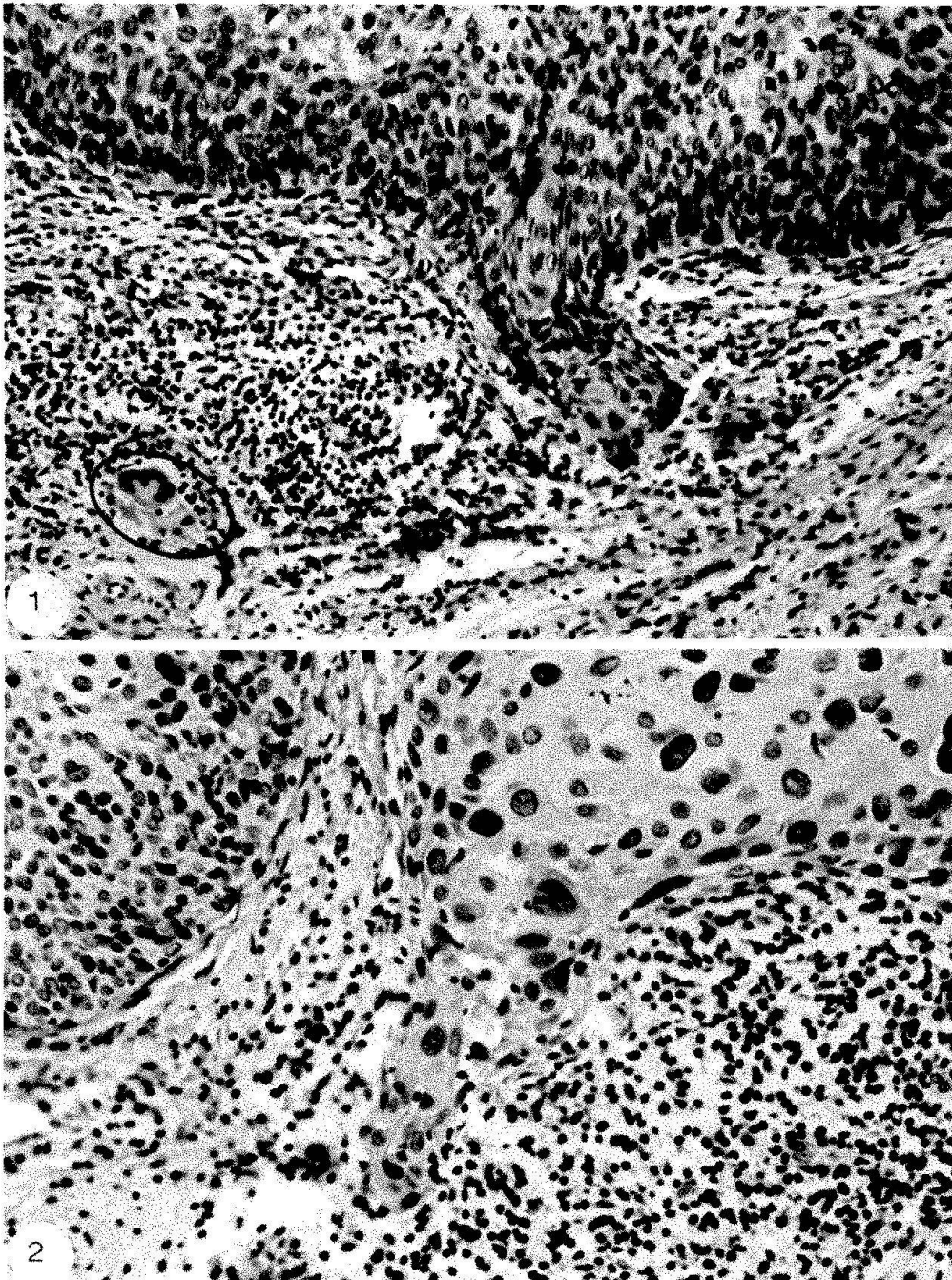
It is a truism that tumor invasion is a complex process which represents, at every moment, the result of tumor action and host reaction. In spite of this complexity a rough concept of invasion, at least of heuristic value, is possible (Sträuli 1980). It must be based on those properties and activities of cancer cell populations that are regularly or at least frequently recorded in surveys of clinical and experimental malignancies. Such features are tumor cell multiplication, exertion of lytic effects, and tumor cell locomotion. Of these, proliferation is the basic property of neoplasia. Benign tumors as well as incipient stages and many metastases of malignant tumors show that cell multiplication alone is unable to achieve invasion and

therefore needs support by other mechanisms. Admittedly, progressive multiplication of cancer cells (Willis 1973) is an elementary factor, even the driving force, of local spread in many types of cancer, and this is easily understandable, since two (or more) daughter cells require more space than one cell. Such space must be taken from the host, and this calls for lytic action. Thus, proliferation and destructive influences together can accomplish invasion and must not be supplemented by cancer cell locomotion. But when and where the latter becomes operative, it can increase the spread of local spread and expand its range.

To what extent are the three mechanisms of invasion operative in solid cancer? In man, the most frequent type of this tumor class is squamous cell carcinoma, of which carcinoma of the ectocervix is the most investigated representative. The available information on local spread of cervix carcinoma is summarized in the next paragraph.

## 3. The lesson of human cervix carcinoma

Owing to early detection by colposcopy and exfoliative cytology, innumerable specimens of cervical carcinoma were and still are subjected to histological examination. A first consequence of this endeavour was the description of a preinvasive stage with a neoplastic focus confined to the epithelium and exhibiting no tendency to extend in depth. Unfortunately, a proliferation of terms complicates communication about cervical cancer. Intraepithelial neoplasia is an adequate designation for the preinvasive stage, but the term carcinoma in situ has also become established. The lesion is intraepithelial with regard to the epithelial-stromal junction represented by the basement mem-



*Figs. 1 and 2. Squamous cell carcinoma of the human ectocervix. Transition from carcinoma in situ to microinvasive carcinoma.*

*Fig. 1. A cohesive projection, consisting of pleomorphic carcinoma cells, extends from the base of the tumor into the stroma. The host tissue is infiltrated by inflammatory cells, among them a foreign body giant cell (circle). Magnification  $\times 160$ .*

*Fig. 2. Similar situation. The pleomorphic cells in the invading part of the tumor are clearly recognizable. Magnification  $\times 250$ .*

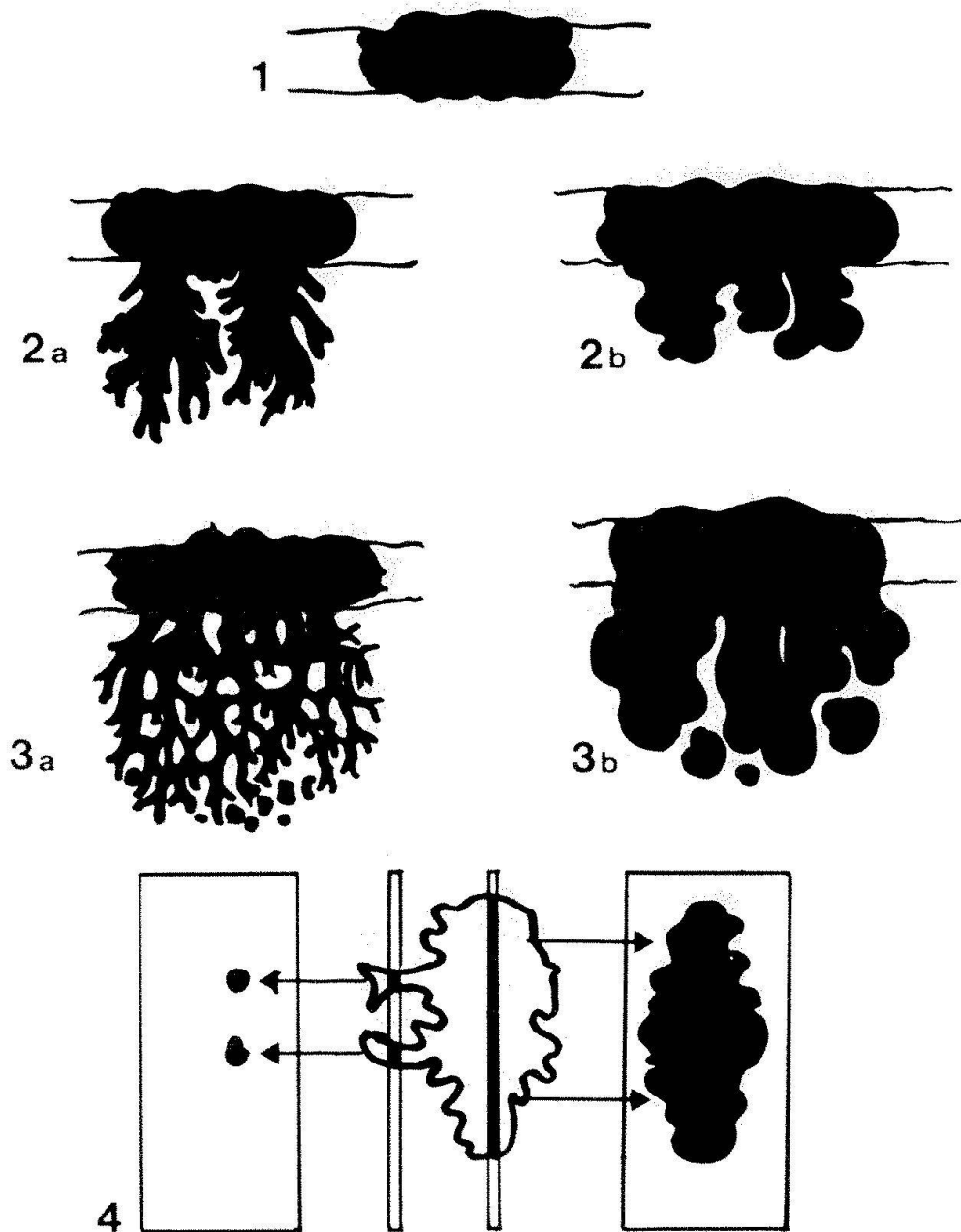
*Figs. 1 and 2 were kindly provided by PD Dr. C.Y. Genton, Leitender Arzt, Institut für Pathologie, Universität Zürich.*

brane. However, multiplication of the neoplastic cells frequently results in their piling-up above the former epithelial surface. Many cells of these exophytically growing neoplasias are shed. This is not only the *raison d'être* of clinical cytology, but also a factor that slows down overall growth of the neoplastic focus.

The next stage is microinvasive carcinoma. Although there is no universal agreement on definition and description of this phase, a prevailing pattern is recognizable (Hamperl 1959, Ober et al. 1961, Burghardt 1973,

Seski and Schmidt 1982). Microinvasion begins with the extension of tongues and prongs from the base of the intraepithelial tumor (fig. 1, 2). These projections consist of tightly cohesive cells which, in contrast to the undifferentiated and uniform cells of in situ carcinoma, are pleomorphic and often show features of differentiation with keratin formation. Inevitably, these tumor extensions come in conflict with the basement membrane. Recently, Spornitz and Hafez (1982) have presented excellent transmission electron microscopic evidence for the forma-

GROWTH PATTERNS OF MICROINVASIVE  
SQUAMOUS CELL CARCINOMAS OF THE HUMAN CERVIX



*Schema 1. Growth patterns of microinvasive squamous cell carcinomas of the human cervix.*

1 Intraepithelial tumor.

2 Non-confluent microinvasion: a finger-like outgrowth, b bulky outgrowth.

3 Confluent microinvasion (coalescence of individual finger-like or bulky parts): a reticular pattern, b advanced bulky outgrowth.

4 Two sections through the same tumor show (left) drop-like foci that seem to lack continuity with the tumor, and (right) the cohesive tumor mass. Serial sectioning reveals in most instances the continuity of tumor parts visible in single sections. Therefore, the distinction of a drop-like growth pattern is hardly warranted.

tion of gaps through which parts of the carcinoma cells are pushed into the stroma. Since basement membrane material is synthesized by epithelial cells, decreased supply of such material could contribute to the weakening of the basement membrane wherever the cervical epithelium is replaced by carcinoma. At the sites of actual penetration, however, proteolytic activity of the carcinoma cells must be considered as a factor of microinvasion.

In the stroma, further invasion of cervical carcinoma frequently displays two more or less successive patterns, non-confluent and confluent; in both, finer (finger-like) or coarser (bulky) outgrowths can prevail (schema 1). It must be emphasized, however, that intermediate forms do occur and that attempts to describe growth patterns should not divert from the concept of a biological and clinical entity represented by microinvasive carcinoma of the cervix.



With regard to mechanisms of invasion, two points merit special attention:

(1) Evidence for lytic effects can be found in the immediate vicinity of the microinvasive tumor parts. They consist in alterations of the stroma with degradative changes of collagen (reticulin) fibrils and the appearance of edema. Since the same sites are frequently infiltrated by host cells (lymphocytes, plasma cells, eosinophils), the origin of the lytic agents is an open issue. The tumor cells, at any rate, are serious candidates. A cathepsin B-like activity has recently been demonstrated in squamous carcinoma cells from the human ectocervix, particularly in a subpopulation with a high rate of proliferation *in vitro* (Pietras and Roberts 1981). It has been argued that the onset of invasion in cervix carcinoma could be due to the emergence of "a cell clone producing a proteolytic enzyme sufficient to weaken the basement membrane and the underlying collagen" (Koss 1981). Proof for this course of events appears now to be within reach.

(2) On the other hand, convincing evidence for the occurrence of tumor cell locomotion in microinvasive cervical carcinoma is lacking. Such evidence could only be of an indirect nature (direct recording of tumor cell translocation by microcinematography being excluded) and consist in the demonstration of isolated carcinoma cells or cell groups within the stroma. This can only be achieved by serial sectioning. In single sections the discontinuous localization of tumor elements is, as a rule, an artefact caused by the complex shape of the invading tumor front (see bottom of text fig. 1). So far, the strongest argument in favor of tumor cell locomotion was provided by Schiller et al. (1953), who described a few chance findings of so-called spray carcinoma. This particular type of microinvasive carcinoma is thought to develop exclusively in the basal layers of the cervical epithelium, while the higher strata remain normal; for this reason the tumor escapes detection by colposcopy or cytology. Spray carcinoma "does not show strands invading the stroma, but the invasion is performed by single carcinoma cells which form a brush- or spray-shaped structure" (Schiller et al. 1953). No spray carcinomas were found in the large material of Hamperl, Burghardt, and later investigators, and it re-

mains doubtful whether such a particular type of infiltrating cervical carcinoma exists at all. For theoretical reasons, better evidence for tumor cell locomotion should be expected in surgical specimens from advanced cervical carcinomas; this assumption, however, is not substantiated by published reports. The conclusion is justified that invasion of squamous cell carcinoma of the cervix, at least in its early stage, is accomplished by tumor cell proliferation and by lytic events in the invasion zone, whereas a contribution of tumor cell locomotion is, at best, exceptional.

#### 4. Tumor invasion and tumor progression

Tumor progression, the antipode of tumor regression, consists in the acquisition of higher degrees of malignancy by individual tumors. Since invasion is the main feature of malignancy, progression must be expected to be chiefly expressed in the appearance of invasiveness as such and in the emergence of the latter's more advanced stages. Tumor progression is analyzed in Fould's "Neoplastic Development" (1969), one of the master texts of theoretical oncology. A passage on carcinoma *in situ* of the human uterine cervix reads as follows: "To call it a cancer is dangerously misleading. Its designation as an imperfect carcinoma indicates, in harmony with the best available evidence, that the quality of invasiveness is not merely inapparent or latent but is absent and can be acquired only by progression". As pointed out in the preceding paragraph, progression from the *in situ* stage to the microinvasive stage implies the onset of lytic activity, but not of cell locomotion. There is some morphological evidence that this limited sequence of progression is not only characteristic for squamous cell carcinoma of the cervix, but also for other localizations of this tumor type. It is a reasonable assumption that full progression (i.e. with inclusion of tumor cell locomotion) is not or only rarely attained at the time when human squamous cell carcinomas are examined after surgery or autopsy. The same need not be true for other human cancers, e.g. malignant melanoma, although the concept of progressive invasion is basically applicable to them. On

the other hand, the limited span of progression available to squamous cell carcinomas corresponds to Fould's statement that "progression does not always reach an endpoint within the life-time of the host". The consequence of this deduction is that progression can be brought to further advance in the progeny of the original tumor through transplantation to new hosts. On this basis we can expect that an extreme degree of invasive potential can possibly be attained by transplantable squamous cell carcinomas. The crucial question, of course, is: Transplantable in what type of host? The progeny of human tumors cannot be serially transplanted in human beings. Attempts were made to use conditioned (X-irradiated and/or cortisone-treated) animals as hosts for permanently transplantable human tumors, among them several squamous cell carcinomas (Toolan 1954). These xenografts displayed capacities of invasion which, in general, did not exceed or even reach those exhibited in the patient. A noteworthy exception is H.Ep.3, the fastest growing and most invasive cancer of the human xenograft series. Its parent tumor, a squamous cell carcinoma of the buccal mucosa, was already in an advanced stage of spread when surgery was performed and material from a cervical lymph node metastasis was harvested for xenografting. In the conditioned host, H.Ep.3 displayed vigorous invasion which, judged from the published micrographs, occurred in a more dissociated growth pattern than in the original host. Spread by single cells was particularly conspicuous when H.Ep.3 was implanted on the chorioallantoic membrane of the embryonated chick egg (Gittermann and Luell 1973). As a most unusual event in this experimental approach, H.Ep.3 was found to metastasize to many organs of the

chick embryo, among them gizzard, heart, lung, liver, kidney, spleen, intestine, eye, and brain. We may thus assume that this human squamous cell carcinoma reached its full invasive potential after heterotransplantation. But this is an exceptional situation. For systematic studies on dimensions of invasiveness attainable beyond the individual tumor-host association, we must resort to animal tumors. An excellent model is the V2 carcinoma of the rabbit.

#### 5. The V2 carcinoma of the rabbit, an absolute invader

Skin papillomas of the cottontail rabbit occasionally progress to squamous cell carcinomas. From such lesions, serially transplantable tumors were established, of which V2 (or VX2) became the most widely used entity (Kidd and Rous 1940). The V2 carcinoma is a moderately to poorly differentiated squamous cell carcinoma which grows in domestic rabbits of all strains and shows a characteristic mode of spread: it penetrates into surrounding host structures from all implantation sites, produces regional lymph node metastases in most animals and spreads to the lungs in about half of the hosts.

As an example of local spread of the V2 carcinoma, some histological findings of subcutaneously implanted tumors are shown in figures 3-10. The first four photographs demonstrate characteristic growth patterns sequentially exhibited by V2 implants during two to three weeks. Cell multiplication proceeds throughout this observation period. A cohesive invasion front exists only for a short time and often abuts upon connective tissue with increased density (fig. 3). Such capsule-like structures are invaded within a

*Figs. 3 - 6. V2, transplantable squamous cell carcinoma of the rabbit. Growth patterns after s.c. implantation.*

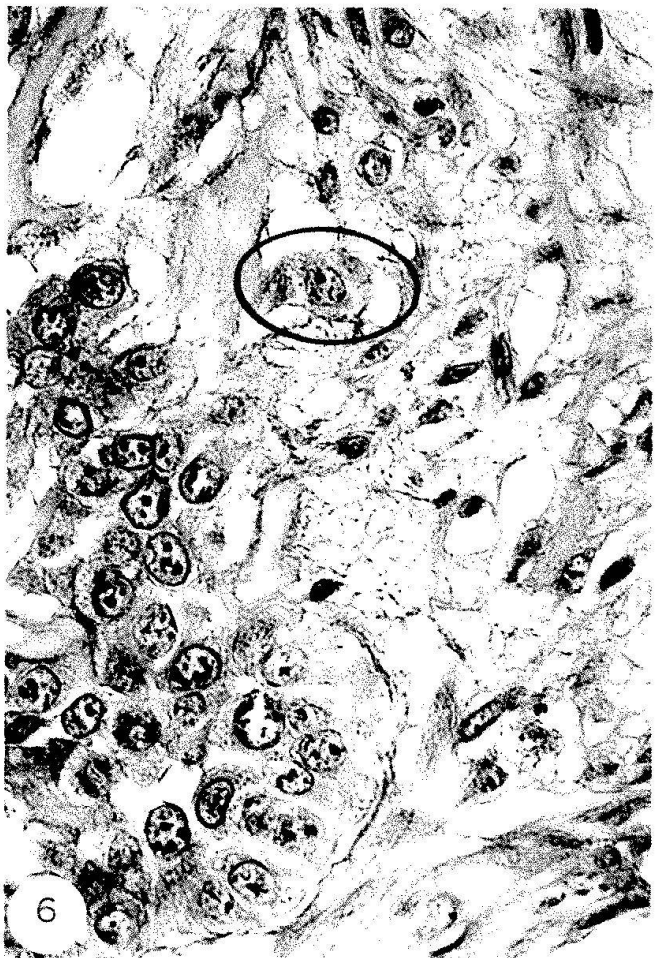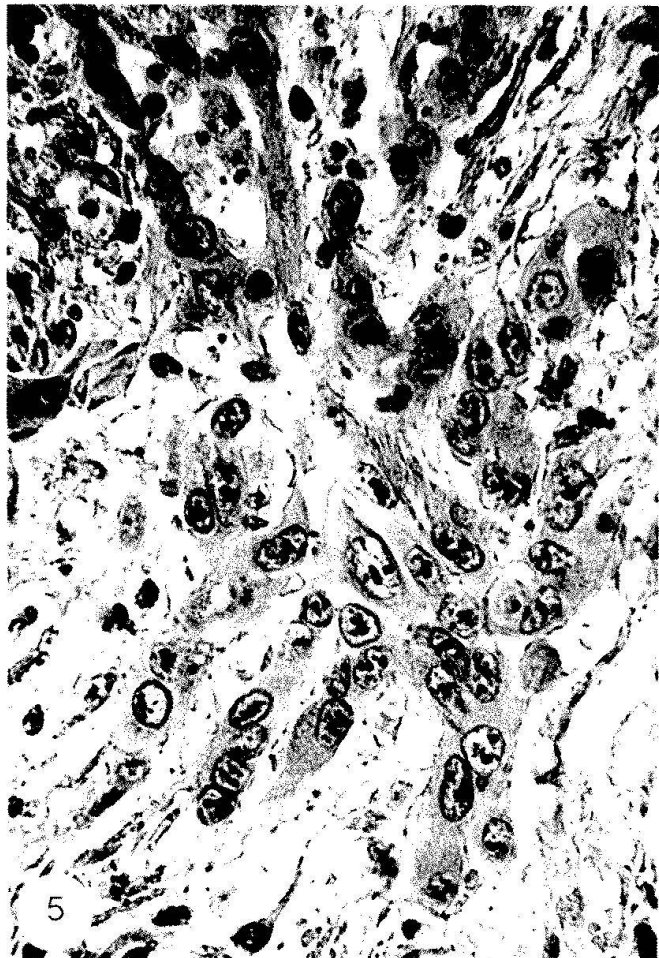
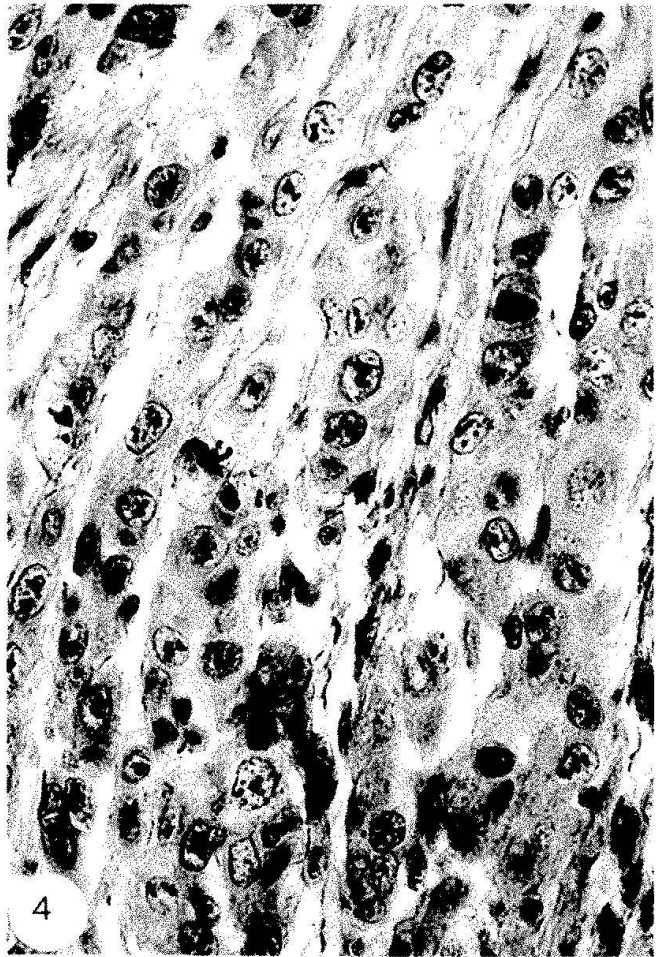
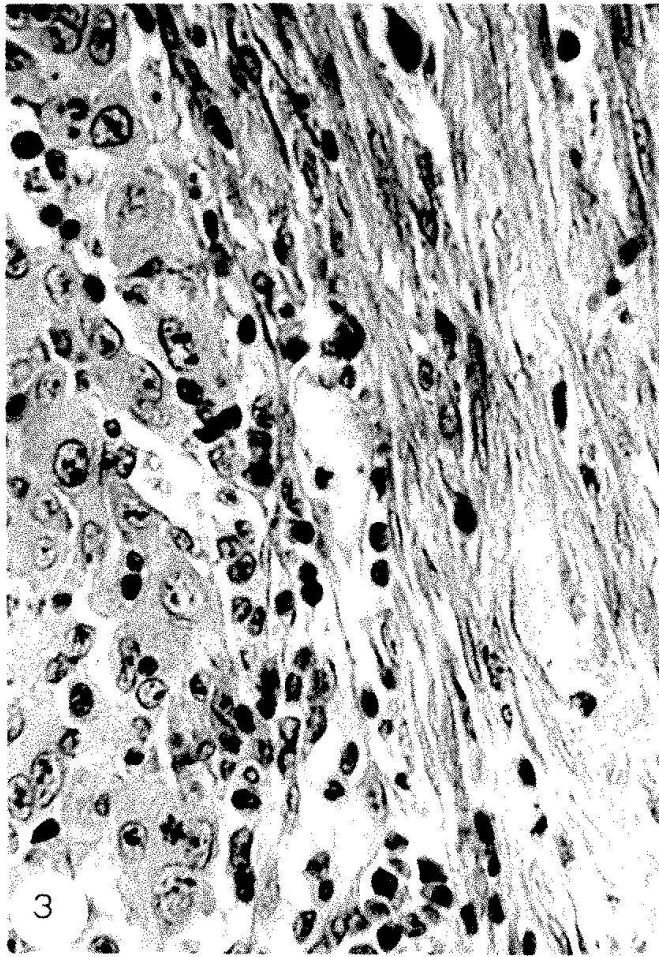
*Fig. 3. A cohesive part of the tumor (left) abuts on connective tissue (right) with increased density. Magnification  $\times 500$ .*

*Fig. 4. A less cohesive part of the tumor with remnants of connective tissue. Magnification  $\times 500$ .*

*Fig. 5. Tongue-like projections of the tumor extending into the surrounding host tissue which shows a loosened structure. Magnification  $\times 500$ .*

*Fig. 6. A single carcinoma cell (circle) is localized at a slight distance from the invading edge of the tumor. Magnification  $\times 500$ .*





few days, either by tumor growth in parallel sheets which split up and compress the stroma (fig. 4), or by the extension of tumor tongues which squeeze into stromal interstices (fig. 5). With progressive dissociation of the invasion front, single V2 cells and small cell groups are frequently found in advanced positions (fig. 6). Serial sectioning proves that in many instances such tumor elements are genuinely isolated and must have reached their actual sites by active translocation.

Lytic effects become recognizable within the first days after tumor implantation. They are exemplified in the next four figures which show the destruction of the skin muscle layer. Histological evidence indicates that this structure together with its collagen fascia perishes in contact with tumor cells (figs. 7, 8), tumor and host cells (granulocytes, monocytes, lymphocytes, fig. 9), and occasionally with host cells alone (fig. 10). Indeed, the studies of our group (Graf et al. 1981; Baici et al. 1982) have revealed that destructive effects in the invasion zone of the V2 carcinoma result from a kind of biochemical interaction between tumor and host with proteolytic enzymes from both sides as effectors.

As concerns the third mechanism of invasion, tumor cell locomotion, histology provides indirect evidence only for its occurrence and significance. Direct evidence is exclusively obtained by time lapse recording of cell motility. We have therefore studied the motile behavior of V2 carcinoma cells by microcinematography (Haemmerli et al. 1982) utilizing experimental conditions of increasing complexity: Motility on glass, on the surface of normal explanted rabbit me-

senteries, and on and within mesenteries of rabbits which had received intraperitoneal implants of the carcinoma. From small tumor fragments explanted in culture chambers (figs. 11-15), single V2 cells detach, flatten, and migrate outwards under display of conspicuous leading lamellae. The migration of the cells is always short-distanced. Apparently the V2 cells, in spite of being on the move almost incessantly, have a tendency to stay in the vicinity of other cancer cells. This "socio-locomotory" behavior is consistent with the distribution pattern of single tumor cells in sections. The mesentery as a transparent membrane allows the microcinematographic recording of V2 cells translocating within a living tissue (figs. 16-19). As long as the tumor cells are on the surface of the mesentery, they move around in a similar configuration as on glass (figs. 16, 17). Penetration into the interior, however, requires shape adaptations, and V2 cells perambulating within the fibrillar meshwork of the mesentery display incessant and striking shape changes apparently imposed by the texture of the microenvironment (figs. 18, 19).

Recent studies on spread of the V2 carcinoma in the mesentery (Sträuli et al., 1983) provide new insight into the possible combinations of the three major mechanisms of invasion. Tumor cells that have migrated singly into the interior often begin to divide and thus give rise to small foci. A graded zone of complete and incomplete destruction of the loose connective tissue extends around such tumor nodules. Apparently, lytic effects depend on the close association of a minimal number of cells. Multiplication of V2 cells with formation of foci can also oc-

*Figs. 7-10: Destruction of the skin muscle layer of the rabbit during invasion of the s.c. implanted V2 carcinoma.*

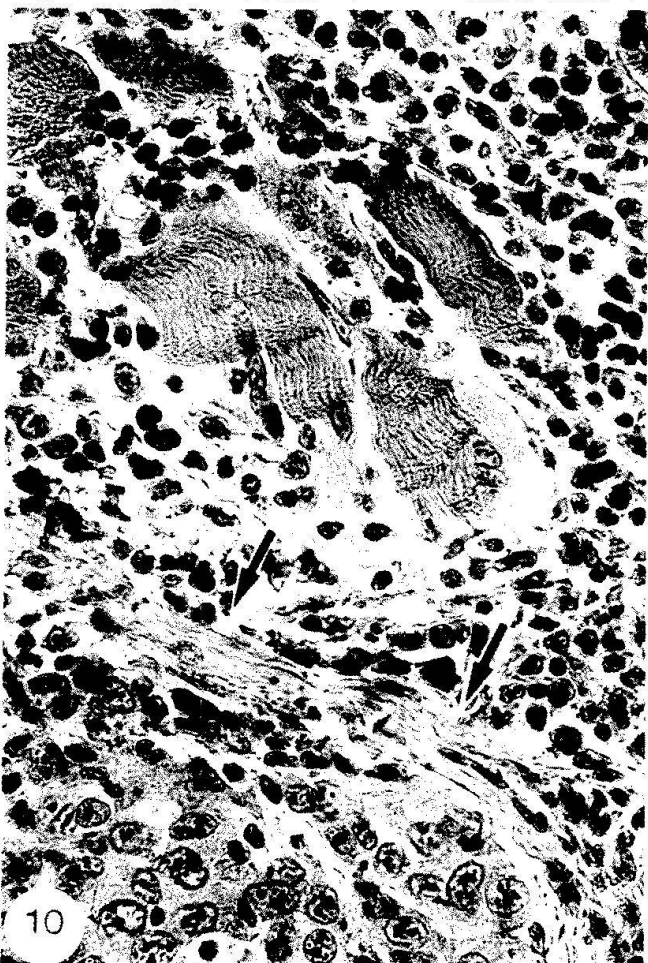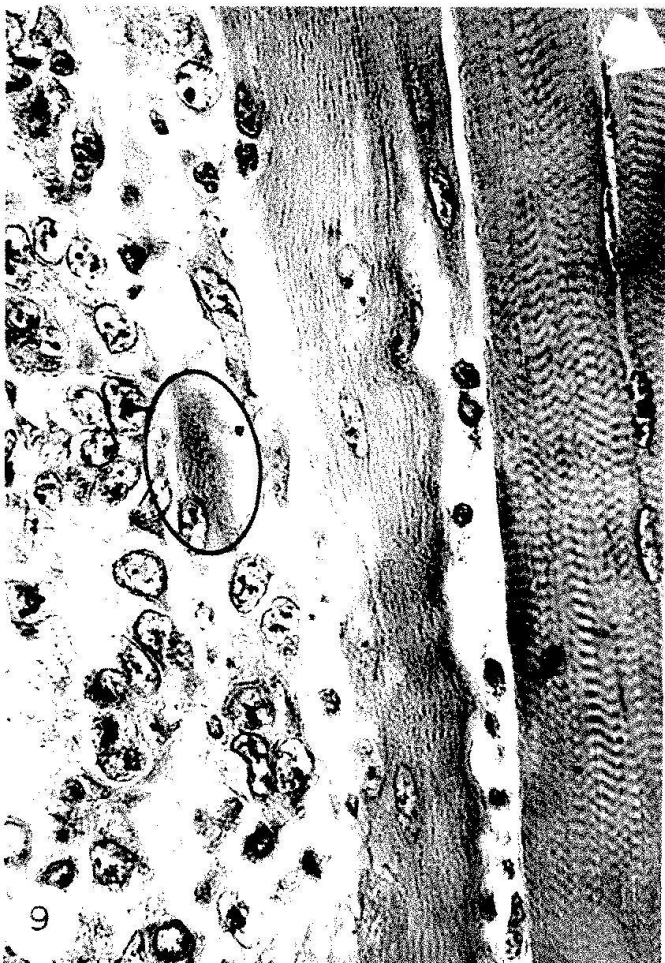
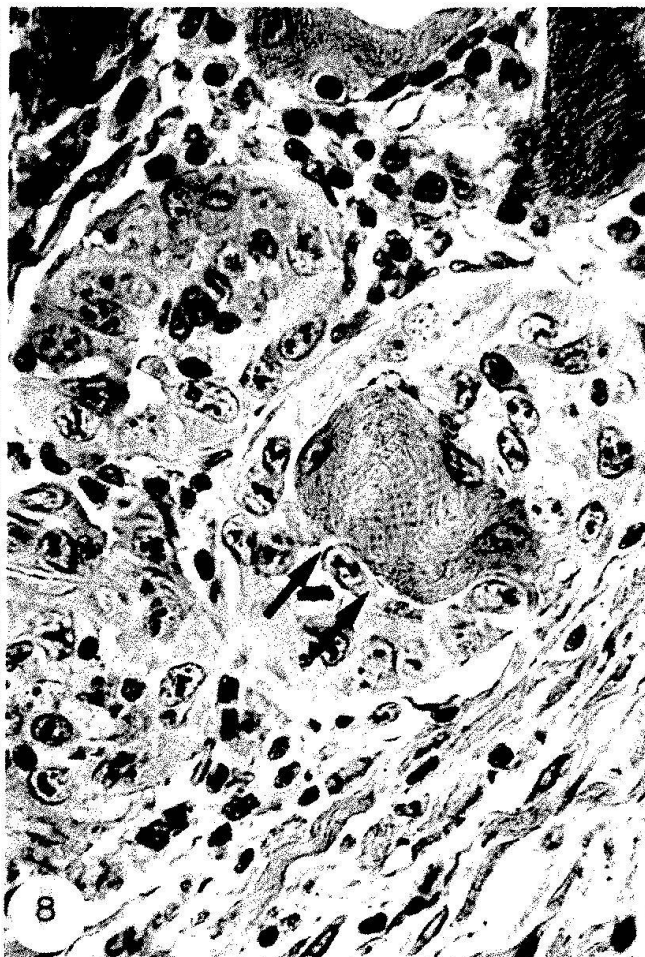
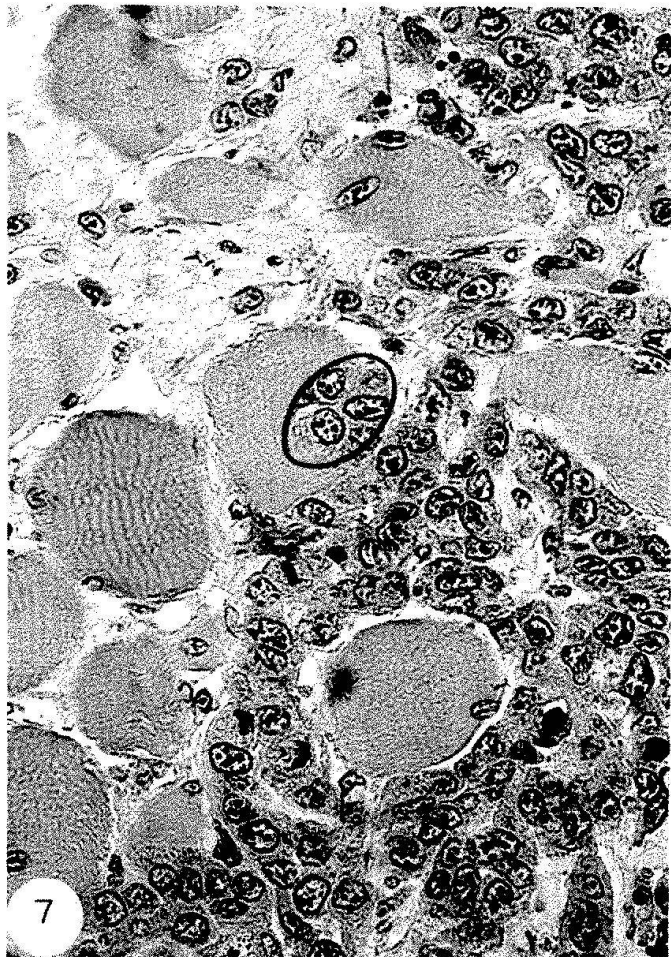*Fig. 7.* The tumor (right and bottom) has invaded, isolated and partly destroyed the large fibers of the striated muscle. Penetration of carcinoma cells into a muscle cell is indicated by a circle. Magnification  $\times 400$ .

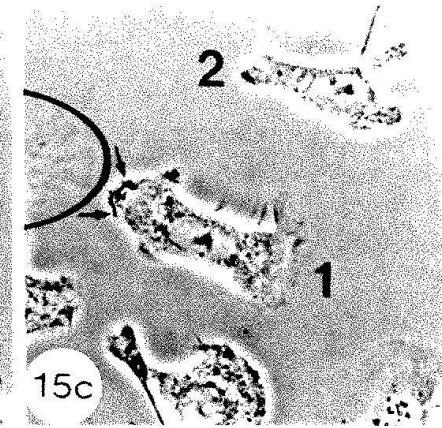
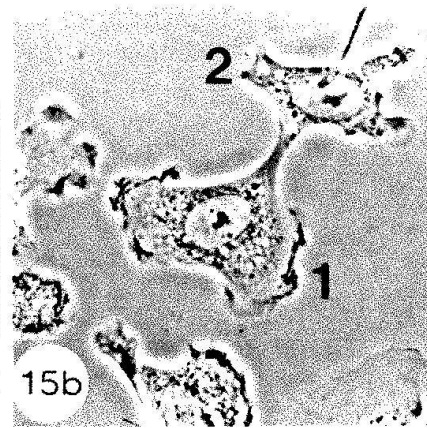
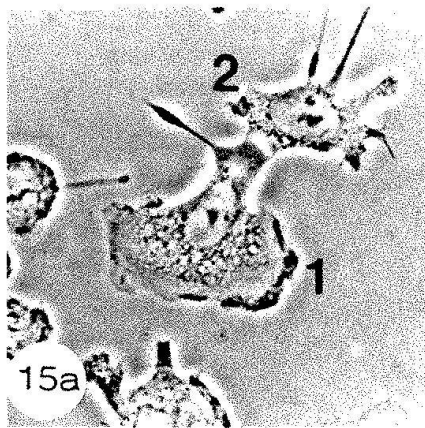
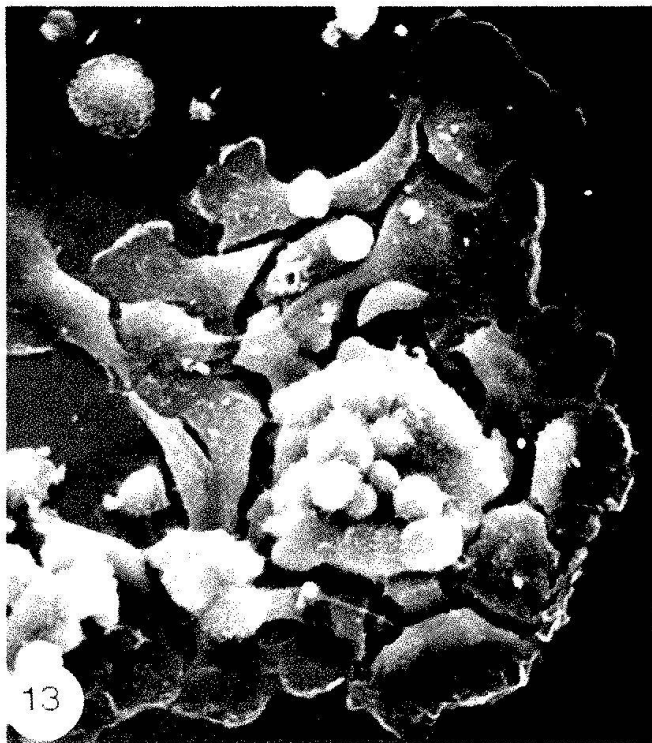
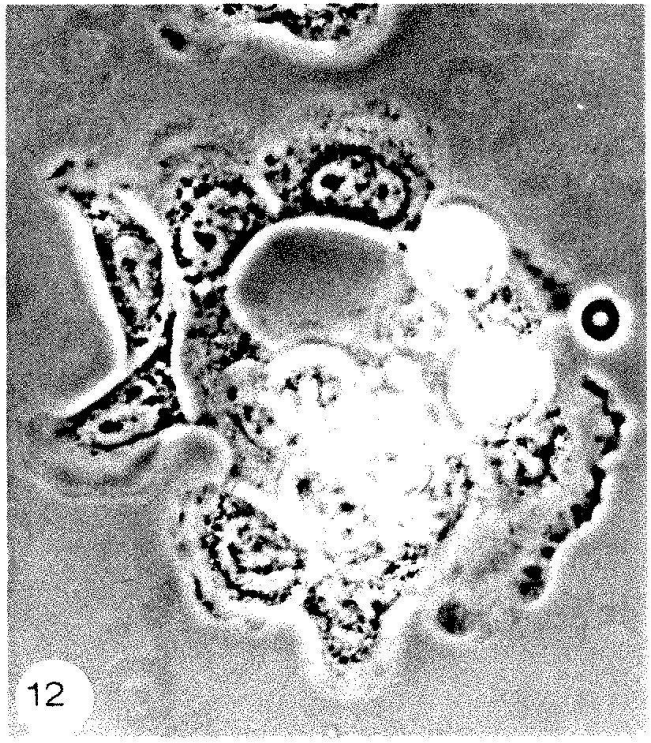
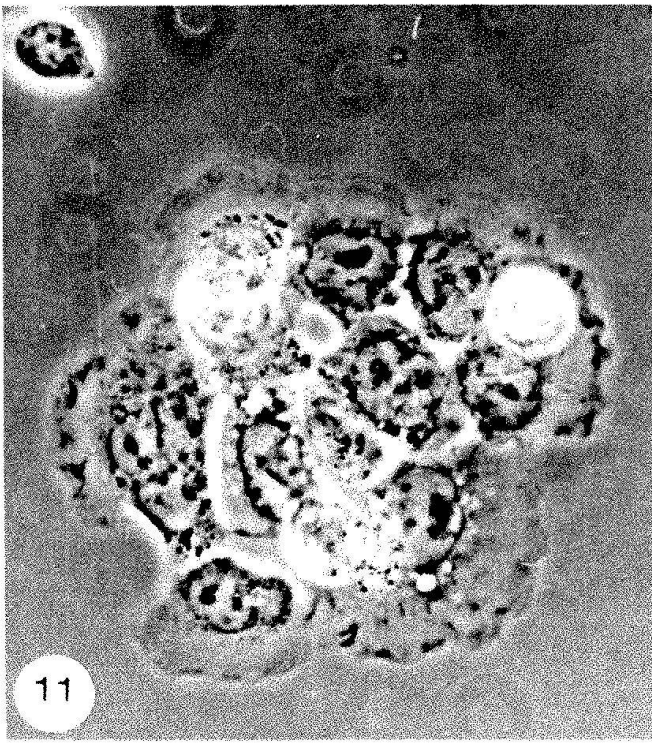
*Fig. 8.* Three muscle fibers are invaded by carcinoma cells. While two fibers are completely replaced by the tumor, one fiber contains a rest of the sarcoplasm (arrows). Magnification  $\times 400$ .

*Fig. 9.* Damage of muscle fibers decreases with distance from the tumor. The figure shows from left to right destruction, damage, and preservation of the musculature. Remnant of a muscle fiber is indicated by a circle. Magnification  $\times 500$ .

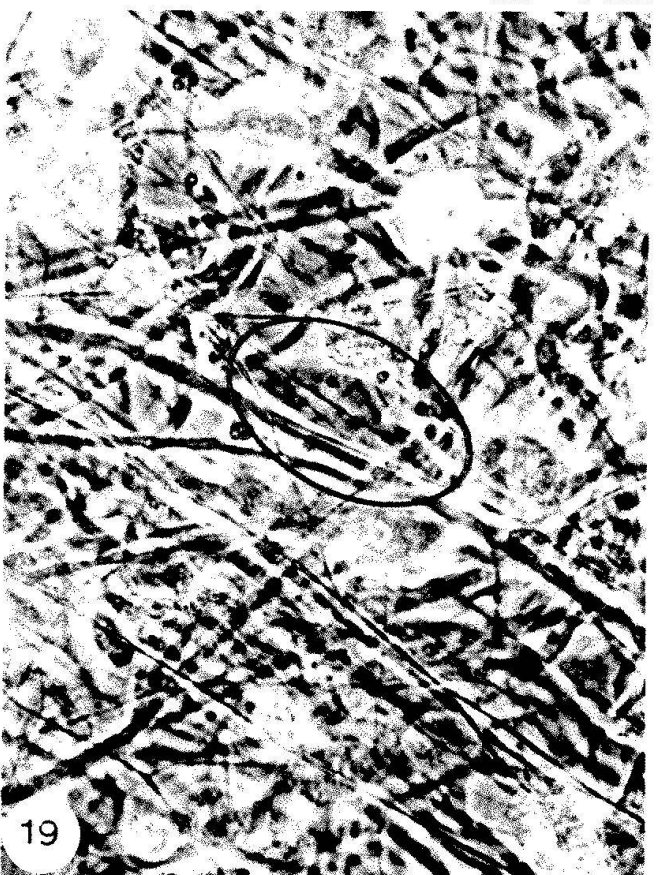
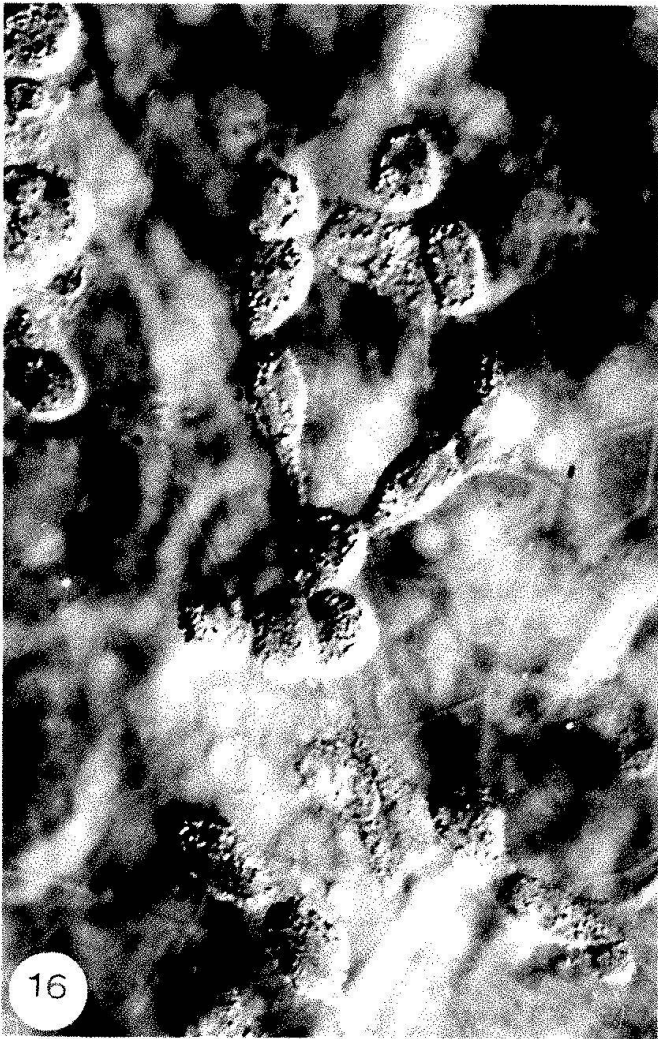
*Fig. 10.* Destruction of the muscle layer by inflammatory host cells. The tumor (bottom) has reached and partly attenuated the collagen fascia (arrows) of the skin muscle. Host cells, apparently attracted by the tumor, have displayed their proteolytic capacity before reaching their chemotactic target, the carcinoma cells. Magnification  $\times 500$ .











cur at the surface of the mesentery. Such aggregates, preceded by a destruction zone, extend in depth and reach the interior, where single V2 cells get loose and, after short migrations, produce new tumor foci. It is conceivable that the invasive maneuvering of V2 cells at a given site and time is governed by environmental influences, but no such interdependence is clearly recognizable at the time being. At any rate, it appears that the tumor disposes always of a complete invasive potential: The V2 carcinoma is an absolute invader.

## 6. Concluding remarks: Progression of tumor invasion

As presented here for squamous cell carcinoma, a trend towards increasing invasiveness is disclosed by the combined engagement of clinical and experimental pathology. This trend fits well into the concept of tumor progression, but so far, the latter's connection with invasive potential is more descriptive than analytic. What causes the progression of tumor invasion? A discussion of the possible mechanism(s) is beyond the scope of this communication, but two major alternatives should be mentioned:

(1) The full potential of invasion is induced in the first cancer cell(s) by the transforming influences. The whole progeny of the transformed cell(s) is genetically primed for inva-

sion, but expression of the potential depends on extragenetic factors, e.g. the size of the cancer cell population.

(2) The acquisition of the full potential of invasion depends on additional (posttransformational) changes of the genotype occurring either in the whole cancer cell population or in subpopulations, which may but must not coincide with clones or stem cells. Whether or not subpopulations are the carriers of the invasive potential is of minor importance for the fundamental aspects of the problem.

The host can be considered to be a decisive factor for both alternatives, and it is an intellectual and technical challenge to investigate in depth the impact of its anti- and pro-neoplastic activities on progression of tumor invasion.

## Literature

- Baici, A., Graf, M., Gyger-Marazzi, M. 1983: The V2 carcinoma of the rabbit as a model for tumor invasion: 3. Proteolytic activities. In: Tumor Progression and Markers. Proc. 6th Meeting Europ. Ass. Cancer Res., Budapest 1981, 47-50. Kugler Publications, Amsterdam.
- Burghardt, E. 1973: Early Histological Diagnosis of Cervical Cancer. Thieme, Stuttgart.
- Foulds, L. 1969: Neoplastic Development. Academic Press, London, New York.

### *Figs. 11-15. Motility of V2 carcinoma cells on glass.*

*Figs. 11-14.* Dissociation of small tumor cell clumps placed on the lower glass surface of a cultur chamber. The cells migrate outwards, frequently under formation of arcade-like arrangements. Note the similarity of living cells (figs. 11, 12) and of cells fixed for scanning electron microscopy (SEM) (figs. 13, 14). Time interval: 1 hour. Phase contrast. Magnification  $\times 300$  (figs. 11, 12) SEM  $\times 700$  (fig. 13),  $\times 350$  (fig. 14).

*Figs. 15a-c.* Sequence from a time lapse film showing the detachment of a V2 cell (1) from another carcinoma cell (2). The membrane activity (arrows) displayed by cell no. 1 indicates the new direction of movement. Contact with the cell at the left side (circle) was established 10 minutes later. Time interval: 15 minutes each. Phase contrast. Magnification  $\times 300$ .

### *Figs. 16-19. Motility of V2 carcinoma cells on and within the mesentery.*

*Figs. 16, 17.* After injection of V2 tumor suspensions into the peritoneal cavity, the carcinoma cells adhere to the surface of the mesentery where they display their locomotory activity. Note the similarity in pattern formation shown in figure 16 to that of cells moving on glass (figs. 12 and 14). Single migrating V2 cells often show long posterior extensions (fig. 17). Differential contrast. Magnification  $\times 600$ .

*Figs. 18, 19.* V2 cells migrating within the fibrillar meshwork of the connective tissue in the mesentery. Phase contrast. Magnification  $\times 600$ .



- Gittermann, C.O., Luell, S. 1973: Chemotherapeutic studies on metastasis of human epidermoid carcinoma (H.Ep.)<sub>3</sub> in the embryonated chick egg. In: *Chemotherapy of Cancer Dissemination and Metastasis*, ed. by S. Garattini, G. Franchi, 279-291. Raven Press, New-York.
- Graf, M., Baici, A., Sträuli, P. 1981: Histochemical localization of cathepsin B at the invasion front of the rabbit V2 carcinoma. *Laboratory Investigation* 45, 587-596.
- Haemmerli, G., Arnold, B., Sträuli, P. 1982: Cell locomotion, a contributing factor in spread of the rabbit V2 carcinoma. *International Journal of Cancer* 29, 223-227.
- Hamperl, H. 1959: Definition and classification of the so-called carcinoma in situ. In: *Cancer of the Cervix (CIBA Foundation Study Group No. 3)*, 2-15. Churchill, London.
- Kidd, J.G., Rous, P. 1940: A transplantable rabbit carcinoma originating in a virus-induced papilloma and containing the virus in masked or altered form. *Journal of experimental Medicine* 71, 813-837.
- Koss, L.G. 1981: Pathogenesis of carcinoma of the uterine cervix. In: *Cervical Cancer*, ed. by G. Dallenbach-Hellweg, 111-142. Springer, Berlin, Heidelberg, New York.
- Ober, K.G., Kaufmann, C., Hamperl, H. 1961: Carcinoma in situ, beginnendes Karzinom und klinischer Krebs der Cervix uteri. *Geburtshilfe und Frauenheilkunde* 21, 259-297.
- Pietras, R.J., Roberts, J.A. 1981: Cathepsin B-like enzymes. Subcellular distribution and properties in neoplastic and control cells from human ectocervix. *Journal of Biological Chemistry* 256, 8536-8544.
- Schiller, W., Daro, A.F., Gollin, H.A., Primiano, N.P. 1953: Small preulcerative invasive carcinoma of the cervix: The spray carcinoma. *American Journal of Obstetrics and Gynecology* 65, 1088-1098.
- Seski, J.C., Schmidt, W.A. 1982: Growth patterns of microinvasive carcinoma of the cervix. In: *Carcinoma of the Cervix*, ed. by E.S.E. Hafez, J.P. Smith, 45-56. Martinus Nijhoff, The Hague.
- Spornitz, U.M., Hafez, E.S.E. 1982: Morphology of the basement membrane in carcinoma of the cervix. In: *Carcinoma of the Cervix*, ed. by E.S.E. Hafez, J.P. Smith, 45-56. Martinus Nijhoff, The Hague.
- Sträuli, P. 1980: A concept of tumor invasion. In: *Proteinases and Tumor Invasion*, ed. by P. Sträuli, A.J. Barrett, A. Baici, 1-13. Raven Press, New York.
- Sträuli, P., In Albon, A.M., Haemmerli, G. 1983: Spread of the V2 carcinoma in the rabbit mesentery: Mechanisms of invasion and tumor-associated alterations of the extracellular matrix. *Cancer Research* 43, 5403-5410.
- Toolan, H.W. 1954: Transplantable human neoplasms maintained in cortisone-treated laboratory animals: H.S.1; H.Ep.1; H.Ep.2; H.Ep.3; and H.Emb.Rh.1. *Cancer Research* 14, 660-666.
- Willis, R.A. 1973: *The Spread of Tumours in the Human Body*. 3rd ed. Butterworths, London.

#### Address of the author

Prof. Dr. Peter Sträuli  
Abteilung für Krebsforschung  
Institut für Pathologie  
Universität Zürich  
Birchstrasse 95  
CH-8050 Zürich (Switzerland)